

Arthrodesis of the First Metatarsophalangeal Joint in Adolescents with Cerebral Palsy

Min Jia Tang, MBBS¹; Ken Ye, MBBS, PhD¹; Samuel K. Van de Velde, MD, PhD²; Erich Rutz, MD, PhD³; Kerr Graham, MD, FRACS¹

¹Orthopaedic Department, The Royal Children's Hospital, Parkville, Victoria, Australia; ²Columbia University Medical Center, New York, NY; ³The Hugh Williamson Gait Analysis Laboratory, The Royal Children's Hospital, Parkville, Victoria, Australia

Abstract:

Symptomatic hallux valgus (HV) and hallux flexus (HF) affect 2% of adolescents with cerebral palsy. Due to the high recurrence rate and lower patient satisfaction after non-fusion surgery, it is generally accepted that fusion of the first metatarsophalangeal joint (1st MTPJ fusion) is the primary treatment of choice in symptomatic bunions. In this paper, we describe our surgical technique which we adapted from the technique described by Coughlin and colleagues—preparation of the joint surfaces using cup and cone reamers and fixation with a robust, dorsal locking plate. The use of these plates has allowed accurate alignment of the fusion and early mobilisation after surgery. We have adopted plate fixation as our primary means of fixation for symptomatic bunions in adolescents and young adults with cerebral palsy.

Key Concepts:

- Arthrodesis of the 1st MTPJ using cup and cone reamers and a dorsal plate is effective in managing symptomatic hallux valgus and hallux flexus in adolescents with cerebral palsy.
- Soft tissue releases and corrective osteotomies alone yield unpredictable results and may require salvage by fusion.
- Benefits of arthrodesis using this technique include stable fixation and early weightbearing.
- Care must be taken to avoid malalignment of the locking plate and excessive shortening of the fusion construct when reaming osteoporotic bone.

Introduction

Symptomatic bunions affect approximately 2% of the population with cerebral palsy (CP).¹ Deformity usually starts in the first decade of life, but symptoms may be delayed until the second decade, usually after puberty.² Van de Velde and colleagues described two principal types of bunions in the cerebral palsy population. Hallux valgus (HV) presents with pain and swelling over a medial callosity in ambulatory adolescents (GMFCS I-III). Hallux flexus (HF) or dorsal bunion presents with

pain and inflammation over the dorsum of the first MTP joint in non-ambulatory adolescents (GMFCS IV and V) (Figure 1).¹ While much has been published on the management of hallux valgus in CP, the literature on management of hallux flexus in adolescents with CP is limited.¹⁻⁶ We describe a technique for arthrodesis of the 1st MTPJ for the management of hallux valgus and hallux flexus, which we have found to be reliable and reproducible.

Description of the Method

A curved dorsal incision of approximately 6–8 cm is made, extending from the interphalangeal joint of the hallux proximally across the 1st MTPJ and along the axis of the 1st metatarsal (Figure 2). The incision is deepened through the subcutaneous layers taking care to identify and protect cutaneous nerves. The extensor hallucis longus (EHL) tendon is protected and retracted laterally, followed by a longitudinal capsulotomy of the 1st MTPJ. The joint surfaces are exposed by release of the collateral ligaments and the plantar plate.

A threaded guide wire is inserted proximally into the first metatarsal, through the center of the articular surface. If there is a significant exostosis, this is removed using a cookie-cutter circular reamer. A concave reamer of appropriate size is used to remove the articular cartilage from the head of the first metatarsal. It is important to remove all the articular cartilage but not to remove the strong subchondral bone. In patients with osteopenia from limited weight-bearing, it is easy to remove too much bone, resulting in excessive shortening and impairing the stability of the fixation. The base of the proximal phalanx is prepared using a similar method with a concave reamer (Figure 3).

Following preparation of the joint surfaces, a trial reduction is performed to ensure that the joint surfaces are congruent, that they can be compressed together, and that suitable alignment of the first MTP joint can be achieved (Figure 4). In an ambulatory patient, the typical position of fusion is 20–30 degrees of dorsiflexion with a hallux valgus angle of 8–10 degrees.

An Acumed (Hillsboro, OR, USA) locking plate is chosen for the right or left foot as appropriate. These plates are pre-contoured for the right or left 1st MTPJ and have a pre-set dorsiflexion angle of either 4 or 9 degrees and lateral translation angle of 10 degrees. We routinely use plates with 9 degrees dorsiflexion and avoid plate bending which may interfere with locking screw engagement. The plate is placed dorsally over the first metatarsal, across the joint and extending onto the dorsum of the proximal phalanx, and temporarily fixed with plate tacks

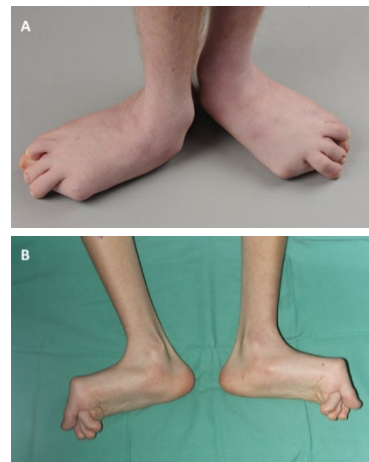

Figure 1. The two types of bunions in cerebral palsy: 1A) Severe bilateral hallux valgus in an ambulatory 16-year-old boy with severe pes valgus, GMFCS III. 1B) Bilateral dorsal bunions in a nonambulatory 14-year-old boy, GMFCS V. Note the elevation of the first metatarsal and the prominence of the tibialis anterior. Clinical images courtesy of author KG, Royal Children's Hospital.

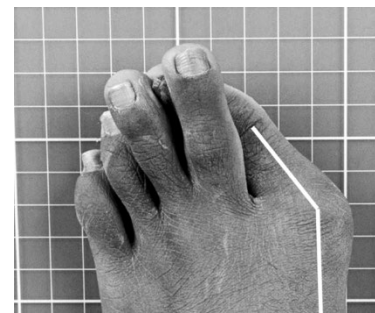


Figure 2. Dorsomedial incision for exposure of the 1st MTPJ in a boy with severe hallux valgus deformity. Clinical images courtesy of author KG, Royal Children's Hospital.

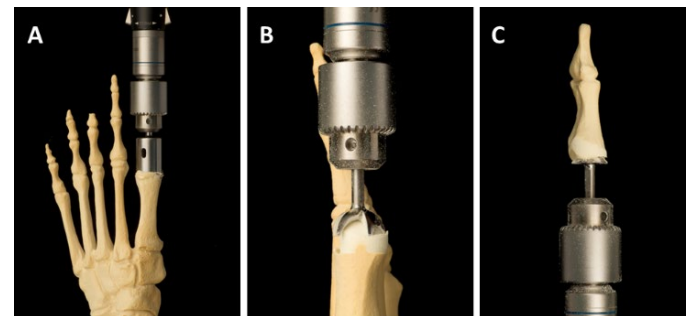


Figure 3. Preparation of the joint surfaces for arthrodesis. A) Removal of the medial exostosis with the circular reamer. B) Removal of articular cartilage, head of the 1st metatarsal with the concave/cup shaped reamer. C) Removal of articular cartilage from the base of the proximal phalanx with the matching convex/cone shaped reamer.

(PL-TACK) (see Figure 5). The position is checked clinically and with the fluoroscope.

It is important to place the plate precisely on the dorsal surface of the 1st metatarsal and proximal phalanx to ensure correct alignment for fusion. Progressive fixation is now undertaken, using a combination of both locking and non-locking screws. The final position of the plate and screw construct is checked fluoroscopically (Figure 6). It is essential to avoid screws protruding on the

plantar aspect of the metatarsal head or base of the proximal phalanx as these can become symptomatic and may require revision.

Following irrigation of the incision and the implant to remove all bone debris and fat, the tourniquet is deflated, haemostasis is secured, and the incision is closed in layers allowing the intact EHL tendon to be repositioned in its normal alignment, which will be over the top of the plate.

We recommend skin closure with interrupted 3.0 nylon sutures placed as mattress sutures, reasonably loose to accommodate for postoperative swelling. The incision is dressed with dressing gauze and a below-knee cast is applied with a firm foot plate to permit early weight-bearing. Patients are discharged on postoperative day 1, with advice to elevate both lower limbs for 7 to 10 days to reduce swelling and promote healing. Weight-bearing for transfers is allowed from day 1.

Postoperatively, the wound is inspected through a window in the cast at 2 weeks after surgery and sutures are removed. Weight-bearing as tolerated is permitted from day 10 in a below-knee walking cast. The cast is removed at six weeks after surgery when additional radiographs are obtained. It can be difficult to be certain that bony union has occurred. The concave and convex surfaces of the joints prevent easy visualization through the joint and there is little in the way of external callus. However, if the patient has no symptoms such as pain or swelling with weight-bearing, full weight-bearing is encouraged in the orthosis that has been used preoperatively. Further clinical and radiographic checks are made at 3 and 6 months after surgery.

Comparison to Other Methods

In our institution, we previously used planar preparation of the joint surfaces using a micro-sagittal saw, small osteotomes, and rongeurs. This method of joint preparation is slower and less precise than the use of cup and cone reamers.^{9,10} In addition, once planar surfaces have been prepared, adjustment is much more difficult if the position is not ideal during trial reduction. We consider the use of cup and cone reamers to be significantly faster

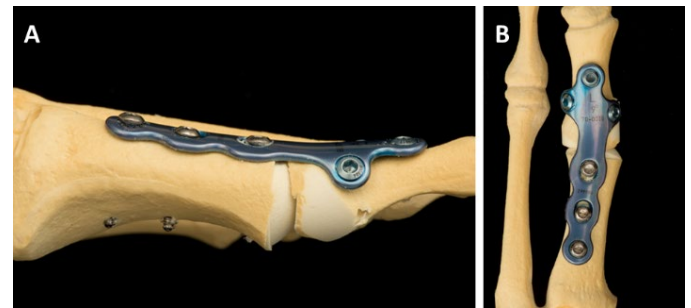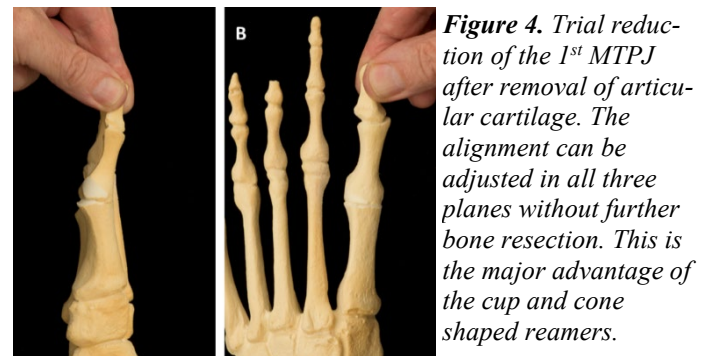


Figure 5. A dorsal locking plate construct for internal fixation of a 1st MTPJ arthrodesis. The hallux valgus angle and dorsiflexion angle are pre-set, and the plates are available in right and left configurations. The screws in the base of the proximal phalanx are locking screws at different angles. This results in a very stable construct which allows early weight-bearing and mobilization.

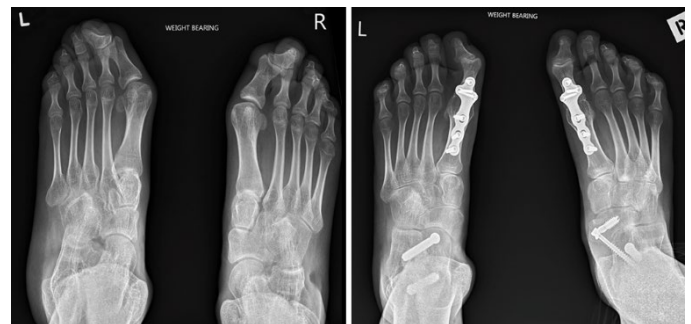

Figure 6. AP weight-bearing radiographs before and after bilateral arthrodesis of the 1st MTPJ for hallux valgus combined with extra-articular subtalar fusion for severe pes valgus. The patient was an adolescent with severe foot deformities and crouch gait. The hallux valgus angle is fully corrected, the intermetatarsal angle has reduced but the interphalangeal angle has increased.

and superior in terms of precision and adjustability than planar joint surface preparation.

With respect to other methods of internal fixation, we believe that fixation with K wires and screws is unreliable and not a good option in this population. Surgery is

typically performed after the pubertal growth spurt when adolescents need to be independent and resent being made once again dependent on outside help for mobility. In our experience, patients found it impossible to comply with long periods of non-weight-bearing after bilateral bunion surgery. This may have contributed to unpredictable postoperative outcomes.

The advantages of using of a dorsal locking plate as opposed to previous generation plates (such as the Vitallium mandibular plate), is that the hallux valgus angle and dorsiflexion angle are pre-set and improve the precision of the arthrodesis so long as the plate is placed directly dorsally. In addition, the plates are stronger, and weight-bearing for transfers are allowed from day 1 and weight-bearing as tolerated from day 7–10, with early return to activity such as attending high school or college. Furthermore, dorsal locking plates are concave and have a low profile. They are asymptomatic in the majority of patients and rarely require removal.

Summary

Symptomatic bunions affect a significant proportion of adolescents with cerebral palsy, and arthrodesis of the 1st MTPJ has been reported in the literature as having the highest success rate in terms of relief of symptoms and correction of deformity. We recommend cup and cone reamers for joint preparation. These should be used carefully in osteopenic bone as it is easy to remove too much bone resulting in excessive shortening of the fusion construct. We use pre-contoured dorsal locking plates for fixation. This technique is reproducible and produces stable fixation allowing early weight-bearing, optimal alignment, high fusion rates, and reliable results for fusing the 1st MTPJ in the treatment of hallux valgus and hallux flexus in cerebral palsy.

Additional Links

- Shore BJ, Thomason P, Reid SM, Shrader MW, Graham HK. Cerebral Palsy. In: Flynn JM, Weinstein S, eds. Lovell and Winter's Pediatric Orthopaedics, 8th edn. Philadelphia, PA: Lippincott Williams & Wilkins; 2020; 509-90. <https://www.wolterskluwer.com/en/solutions/ovid/lovell-and-winters-pediatric-orthopaedics-768>

- Miller F, Bachrach S, Lennon O'Neil, et al. Cerebral Palsy. 2nd edn. Cham, Switzerland: Springer, 2020 <https://www.springer.com/gp/book/9783319745572>
- Kulkarni VA, Kephart DT, Olleac R, et al. Enhancing Observational Gait Analysis—Techniques and Tips for Analyzing Gait Without a Gait Lab. *JPOSNA*. 2020 Nov; 2(3) <https://www.jposna.org/ojs/index.php/jposna/article/view/135>

References

1. Van De Velde SK, Cashin M, Johari R, et al. Symptomatic Hallux Valgus and dorsal bunion in adolescents with Cerebral Palsy: Clinical and biomechanical factors. *Dev Med Child Neuro*. 2018; 624-628
2. Bishay S, El-Sherbini M, Lotfy A, et al. Great Toe Metatarsophalangeal arthrodesis for Hallux Valgus deformity in ambulatory adolescents with spastic Cerebral Palsy. *J Child Orthop*. 2008 Nov; 3:47-52
3. Bayhan IA, Kadhim M, Sees J P, et al. Hallux Valgus deformity correction without fusion in children with cerebral palsy. *J. Pediatr. Orthop. B*. 2017 Mar; 26(2):164-171
4. Fulford GE. Surgical management of ankle and foot deformities in Cerebral Palsy. *Clin Orthop Relat Res*. 1990; 253: 55-61
5. Davids JR, Mason TA, Danko A, et al. Surgical management of Hallux Valgus deformity in children with Cerebral Palsy. *J Pediatr Orthop*. 2001; Jan:21(1):89-94
6. Sarikaya IA, Seker A, Erdal OA et al. Surgical correction of Hallux Valgus deformity in children with Cerebral Palsy. *Acta Orthop. Traumatol*. 2018; Feb: (52); 174-178
7. Dening J, Van Erve RHGP. Arthrodesis of the First Metatarsophalangeal joint: A Retrospective Analysis of Plate versus Screw Fixation. *J Foot Ankle Surg*. 2021; Apr: 51(2012); 172-175
8. Coughlin MJ, Abdo RV. Arthrodesis of the First Metatarsophalangeal Joint with Vitallium Plate Fixation. *J Foot Ankle*. 1994; Jan:15(1); 18-28
9. Goucher NR, Coughlin MJ. Hallux Metatarsophalangeal Joint Arthrodesis using Dome-shaped Reamers and Dorsal plate fixation: A Prospective study. *Int. J. foot ankle* 2006; Nov:27(11); 869-876
10. Curtis MJ, Myerson M, Jinnah RH, et al. Arthrodesis of the First Metatarsophalangeal Joint: A biomechanical study of internal fixation techniques. *J Foot & Ankle*. 1993; Sep:14(7); 395-399