

# Arthroscopic Saucerization and Repair of the Lateral Discoid Meniscus

*Gin Way Law, MBBS, MRCS(Edin); Dave Lee, MBBS, MMed(Ortho), FRCS(Tr&Ortho), FAMS; Shobhit Gupta, MBBS., MS (Orth.); James HP Hui, MBBS(S'pore), FRCS(Edin), FAMS(S'pore)*

*Department of Orthopaedic Surgery, National University Health System (NUHS), Singapore*

## **Abstract:**

Surgical treatment of the symptomatic discoid lateral meniscus has undergone a paradigm shift since recognition of the development of accelerated osteoarthritis with subtotal meniscectomies. Current strategies have shifted towards meniscus preservation, and meniscoplasty is considered the gold standard treatment. Meniscoplasty with saucerization of the meniscus recreates the standard crescent shape for improved shock absorption, load transmission, and joint stability. As the discoid lateral meniscus is also associated with intrasubstance degeneration and meniscus tears, concomitant meniscus repair should be performed in line with efforts for meniscus preservation. In this manuscript, we detail our saucerization technique, considerations for meniscus repair, and tips to achieve a successful outcome.

## **Key Concepts:**

- The discoid lateral meniscus should be judiciously assessed during arthroscopy as symptoms from the discoid lateral meniscus can be due to hypermobility or from tears.
- Meniscus saucerization should retain 8 mm of residual peripheral meniscus for function preservation for good mid- to long-term outcomes.
- Meniscus repair should be used to address tears and instability in the discoid lateral meniscus.
- Repair of the posterior horn of the lateral meniscus must be performed cautiously when using the all-inside repair device via the anterolateral portal due to proximity of the device to posterior neurovascular structures, especially in the small pediatric knee.
- Meniscus-based sutures can be used to treat horizontal tears associated with intrasubstance degeneration in children and adolescents.

## **Introduction**

Discoid meniscus affects the lateral meniscus predominantly and has different incidences worldwide.<sup>1</sup> Asians have higher incidences, with up to 20% reported compared to 0.4% in Caucasians.<sup>2-6</sup> These occur in both knees in approximately 20% of cases.<sup>7-9</sup>

The surgical treatment for the symptomatic discoid meniscus has evolved since the recognition of early secondary osteoarthritis associated with subtotal meniscectomy.<sup>3,10-13</sup>

Current treatment goals are aimed at meniscus preservation, and at present, meniscoplasty is considered the gold standard treatment for the symptomatic discoid lateral meniscus.<sup>3,6,10</sup> This involves removal of the central part of the meniscus to restore the standard crescent shape<sup>3,6,10</sup> and has shown good mid- to long-term outcomes in children and adolescents.<sup>10</sup>

In recent years, meniscus repair has also been advocated over resection of horizontal cleavage tears to prevent excessive tibiofemoral contact pressures associated with complete resection.<sup>14</sup> Favorable outcomes have been shown in degenerative horizontal meniscal tear repairs,<sup>15,16,17</sup> and peripheral meniscus instability can be concurrently addressed with the same repair techniques by anchoring the meniscus to the joint capsule.<sup>18</sup> As tears are commonly associated with the discoid lateral meniscus,<sup>2,19,20</sup> especially in the degenerative horizontal cleavage configuration,<sup>21,22</sup> meniscal repair should be performed in conjunction with saucerization to create a functional meniscus for improved shock absorption and load transmission.

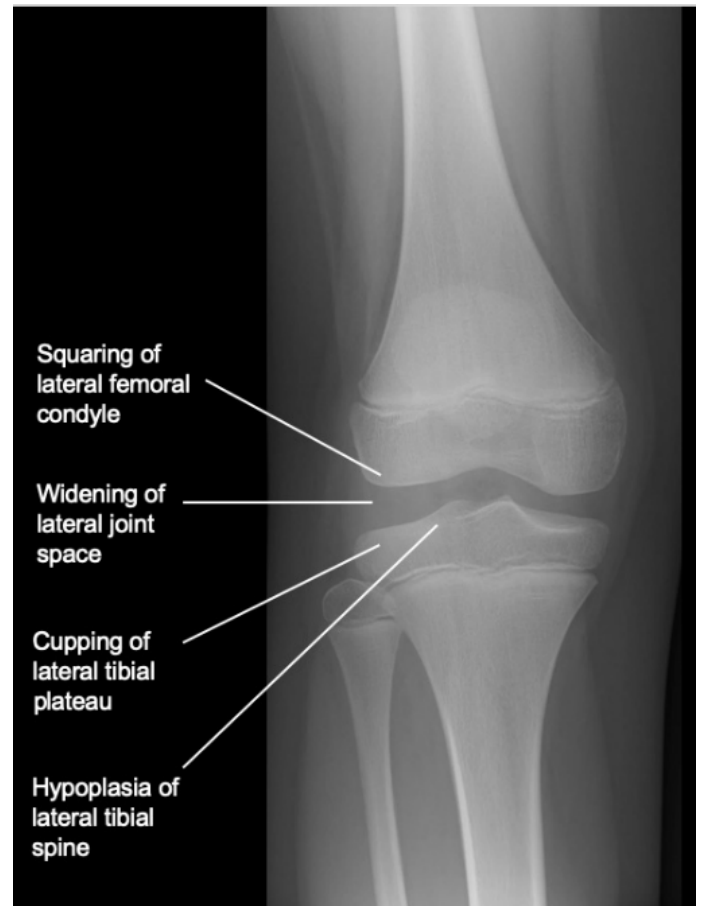
In this paper, we describe our technique for saucerization of the lateral discoid meniscus and share tips that we use for concomitant meniscal repair to preserve the meniscus.

## Etiology & Preoperative

### Clinical Evaluation

The discoid meniscus has variable morphologies<sup>23</sup> and a histological structure different from the normal meniscus.<sup>1</sup> These menisci have a disorganized collagen network arrangement,<sup>24-26</sup> less collagen fibers, and are prone to intrameniscal mucoid degeneration.<sup>25,26</sup> The discoid meniscus is also anatomically thicker, particularly at the outer rim, compared to the normal meniscus which results in abnormal shear stresses and further predisposes the meniscus to tears.<sup>27-29</sup>

The symptoms typically result from either a tear in the meniscus or from an unstable discoid variant.<sup>30</sup> In addition to the physical properties that predispose the meniscus to tears, hypermobility of the discoid lateral meniscus further contributes to their risk of injury.<sup>31,32</sup> The classic snapping knee syndrome is postulated to result from the displacement of the meniscus with knee flexion and extension due to meniscus hypermobility.<sup>25,33,34</sup> Although the Wrisberg type discoid meniscus is traditionally associated with hypermobility due to the absence of the normal posterior attachment,<sup>25</sup> peripheral rim

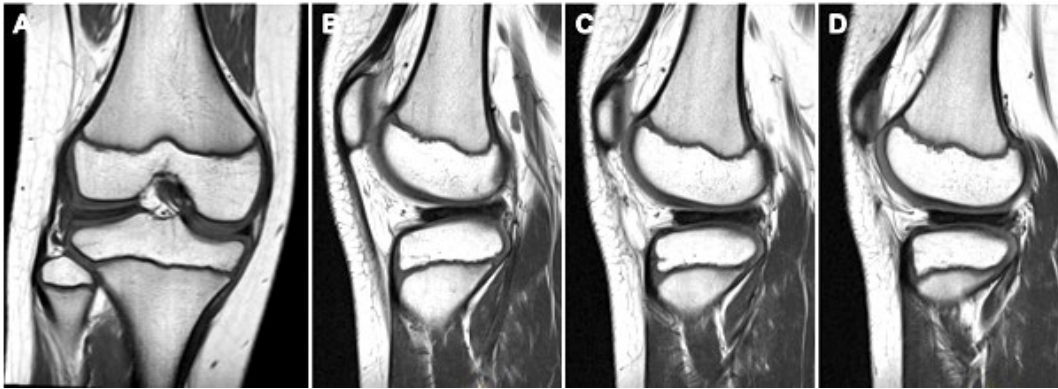

**Figure 1.** Radiograph features suggestive of a discoid lateral meniscus

instability has also been identified in both complete and incomplete discoid subtypes.<sup>35,36</sup>

The hypermobility of the discoid meniscus can cause pain and mechanical symptoms in younger children and is more likely to result in tears in adolescents.<sup>1,25,30,37-39</sup> The symptoms from the discoid lateral meniscus occur most frequently in teenagers and are often caused by sports activity<sup>19</sup> and are associated with meniscus tears.<sup>30</sup> In the younger pediatric population, these symptoms are often not associated with any trauma.<sup>19</sup>

Snapping in the knee with discoid meniscus classically occurs between ages of 5 and 10 years.<sup>30</sup> In the younger child (3 to 4 years old), snapping may not be associated with pain. In older children (8 to 10 years), however, pain is commonly experienced with activity.<sup>40</sup>



**Figure 2.** (A) T1 weighted MRI images of the right knee coronal view, (B to D) sagittal view with sequential 5-mm cuts showing meniscal continuity of the discoid lateral meniscus

Discoid meniscus tears usually present with sudden onset knee pain, locking, and inability to weight bear on the affected limb.<sup>30</sup> Physical findings may include joint line tenderness, knee effusion, loss of extension or flexion, and a positive McMurray's test or Apley's grind test.<sup>30,41</sup>

The contralateral knee should also be examined, especially in children under 10 years of age with a symptomatic complete or unstable discoid meniscus as they have higher bilateral incidence and are at increased risk of symptoms developing in the contralateral knee.<sup>42</sup>

Surgery should only be considered for the symptomatic discoid meniscus as they can exist without ever being symptomatic.<sup>43</sup> These symptoms may include pain, snapping, locking or instability and usually occur in the absence of trauma.<sup>10,30,41</sup> In cases of the snapping knee syndrome, a clunk may be heard at terminal knee flexion due to instability in the meniscus.<sup>44</sup>

### Preoperative Imaging

Weight-bearing anteroposterior, lateral, and skyline plain radiographs of the symptomatic knee should be obtained where possible as the preliminary imaging modality for the investigation of a symptomatic knee. Radiographic features suggestive of a discoid lateral meniscus include lateral joint space widening, a squared off lateral femoral condyle appearance, lateral tibial plateau cupping, and lateral tibial eminence hypoplasia.<sup>25,45</sup> These features are shown in Figure 1.

As radiographs are often normal in patients with a discoid meniscus, magnetic resonance imaging (MRI) may be performed for confirmation.<sup>1</sup> The diagnosis can be

made with continuity of the meniscus between the anterior and posterior horns on three or more 5-mm thick consecutive sagittal slices<sup>46</sup> (Figure 2), or when the ratio of the minimal meniscal width to the maximal tibial width is more than 20% on the coronal cut and the ratio of sum of the width of both lateral horns to the maximal meniscal diameter on the sagittal cut is more than 75%.<sup>47</sup> Other MRI features suggestive of a discoid meniscus include meniscal width over 15 mm on the coronal cut<sup>48</sup> and a thickened, bow-tie meniscus appearance.<sup>30</sup>

Findings of parameniscal edema adjacent to a discoid meniscus, shape deformation with abnormal infolding, dents or buckling of the meniscal surface, and meniscal displacement on MRI suggest meniscal instability.<sup>21</sup> Peripheral meniscus tears, horizontal meniscus tears, and intrasubstance degeneration can sometimes also be assessed on MRI. In children under 10 years old, however, a tear in a morphologically normal meniscus is rare.<sup>21</sup> Thus, it is suggested that a horizontal cleavage tear in the meniscus in the absence of signs of trauma in the pediatric age group is highly suspicious for a discoid meniscus variant.<sup>49,50</sup> The MRI will also be able to identify if there is cartilage injury, loose bodies, or any osteochondral dissecans lesions that may account for their symptoms.

In patients with clinical findings of concomitant knee deformity or limb length discrepancy that may cause abnormal loading to the knee, weight-bearing long limb films should also be performed for formal assessment of alignment and surgical correction should be considered where appropriate.

## Operative Procedure

### *Room Setup and Patient Positioning*

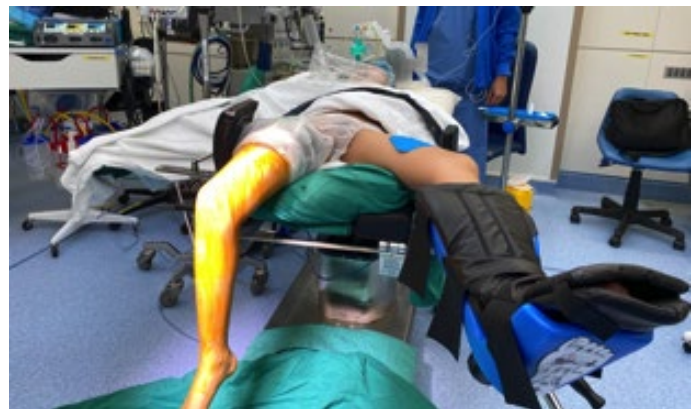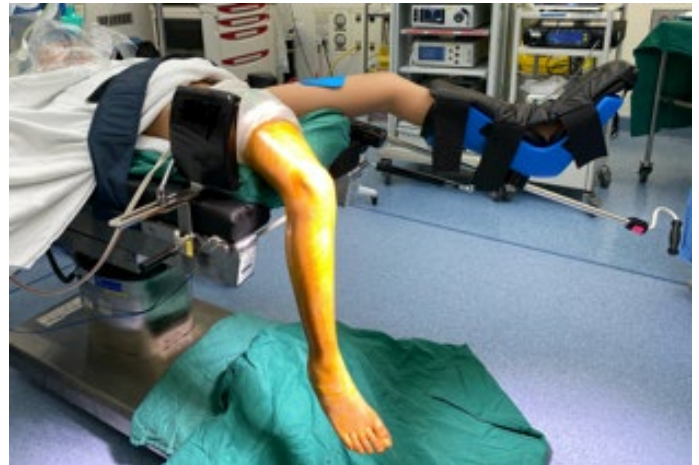The patient is positioned supine, and a thigh tourniquet is applied. The surgical table is broken, and the operative knee left free hanging as shown in Figure 3. This is to allow unrestricted access to the knee to facilitate placement and utilization of accessory portals if required and manipulation of the knee during surgery. The lower limbs are abducted and well cushioned beneath their thighs with a thick, well-padded bolster. A rigid side support is positioned lateral to the mid-thigh of the operative knee, and the nonoperative leg is supported in a leg holder.

The room setup and respective equipment positions are shown in Figures 3 and 4. As the majority of the surgery is performed with the operative limb in a figure-of-four position, a separate trolley with folded drapes stacked to prop up the foot is utilized to reduce the need for an additional assistant to hold the limb and to allow room for maneuvering of the arthroscope during surgery. The lateral tibiofemoral compartment can be further opened up with a varus force on the medial knee in this position. The viewing screen showing the arthroscopic images is placed just lateral to the nonoperative leg.

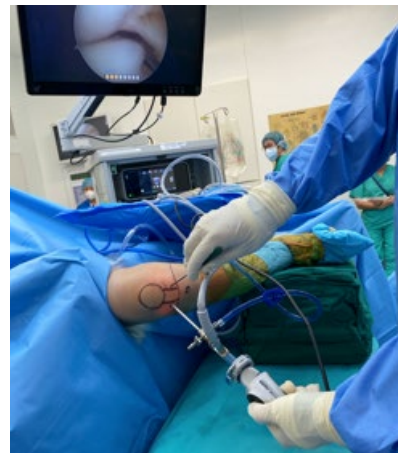Our setup for the figure-of-four facilitates knee flexion to 90 degrees which directly increases the distance of the posterior neurovascular structures to lateral meniscus,<sup>51</sup> opening up of the lateral tibiofemoral compartment with forced varus and improved instrument and implant maneuverability.

### *Procedure*

The anatomical landmarks are marked, as shown in Figure 5A, and standard anterolateral (AL) and anteromedial (AM) portals are used. Both AL and AM portals are placed in the soft spot 1 cm above the joint line with the AL portal as close to the lateral border of the patella tendon as possible and the AM portal placed 1 cm medial to the medial border of the patella tendon. We find that this configuration allows best access to all areas of the meniscus for saucerization and meniscal repair if required.



**Figure 3.** Patient positioning



**Figure 4.** Setup for figure-of-four position and positioning of arthroscopic equipment

The AL portal is our main viewing portal, and the AM portal is our main working portal. The more medial placement of the AM working portal allows better access to the anterior horn, while placement of the AL portal just next to the lateral border of the patella tendon allows improved access when the working portal is switched to the AL portal. These two portals are generally adequate

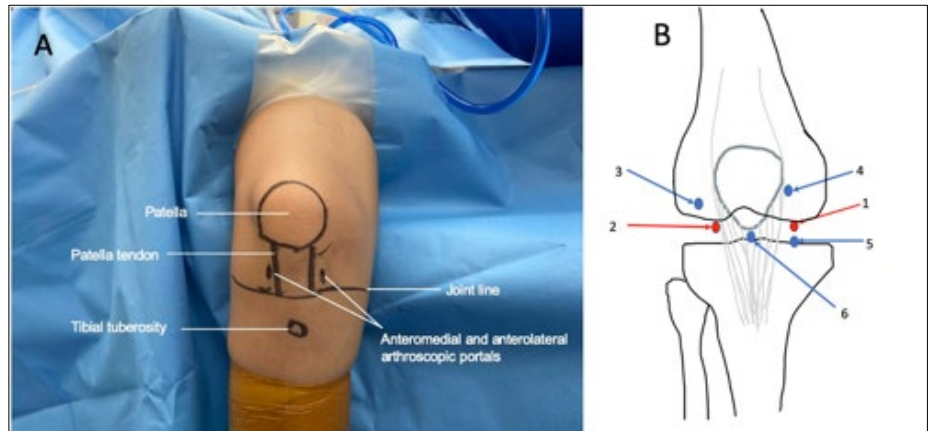
for most cases, but additional portals may be added as shown in Figure 5B if required.

We use a 4.0-mm 30-degree arthroscope. A diagnostic arthroscopy is performed, and the discoid lateral meniscus is assessed for the following: (i) morphological appearance according to the Watanabe classification into complete (type I), incomplete (type II), or Wrisberg ligament-type (type III) based on the degree of tibial plateau coverage and presence or absence of the normal posterior attachment,<sup>23</sup> (ii) evidence of peripheral rim instability, (iii) tear sites and tear configuration. The cartilage is also inspected for any cartilage lesions.

For discoid lateral meniscii with a tear or peripheral instability, meniscus repair may be performed prior to saucerization if the tear site can be easily accessed. The reduction of the bulky discoid meniscus to the peripheral location after meniscus repair can help the appreciation of the areas the discoid meniscus to resect. An example of a lateral discoid meniscus with meniscal tear and peripheral rim instability that has both issues appropriately addressed with the all-inside meniscus repair along with the saucerization is shown in the accompanying video.

In other patients where access may be difficult because the large bulky discoid meniscus prevents visualization of the tear or location of peripheral instability, a careful limited resection of bulky discoid central region can be first performed. This then allows better visualization and access to the peripheral part of the meniscus for the repair to be performed.

Careful assessment and preservation of the meniscus roots, especially the posterior root, helps maintain hoop stresses through the meniscus. The resection margins for the saucerization are marked out to achieve a precise cut with the aim to keep 8 mm of peripheral meniscus tissue while recreating the crescent shaped meniscus. This width is based on Hayashi et al.'s findings which showed higher rates of meniscal re-tears with remnant



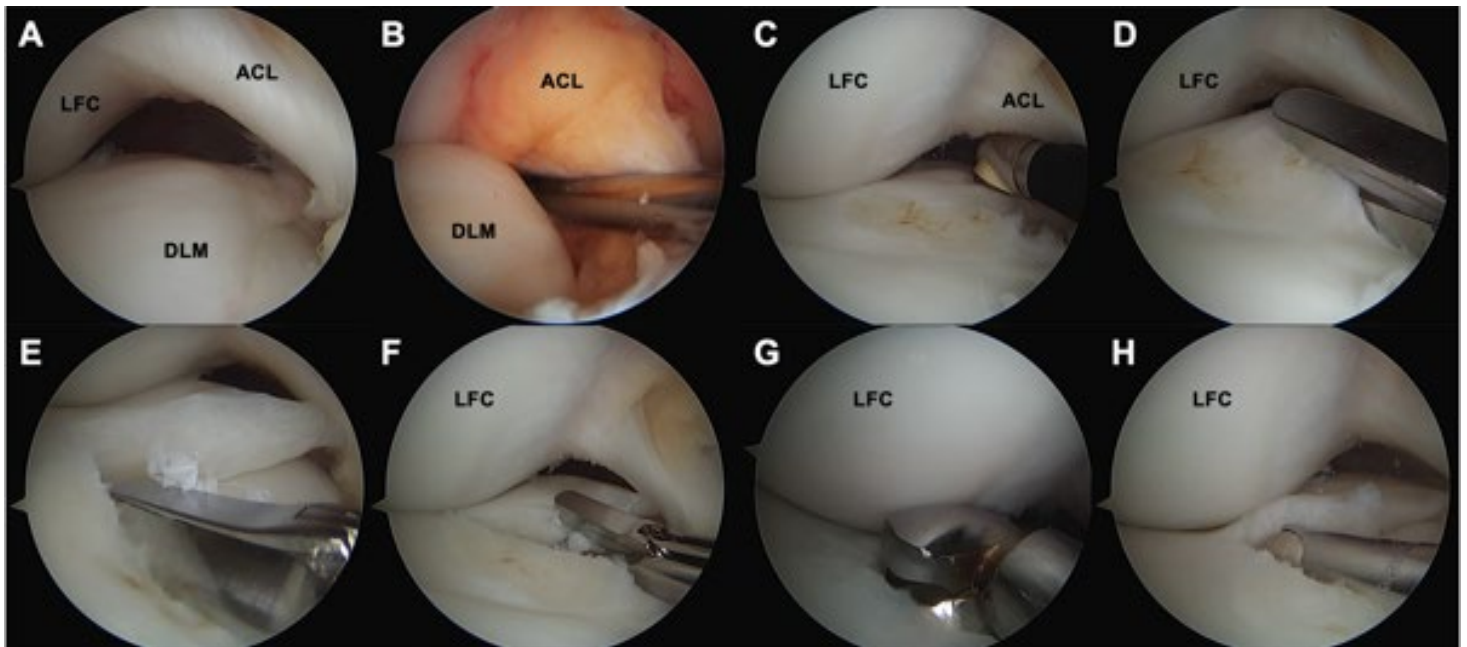
**Figure 5.** (A) Positioning of routine arthroscopic portals, (B) Sites of accessory portals that may be considered in difficult cases to facilitate access (blue)

meniscal widths greater than 8 mm.<sup>37</sup> Radiofrequency ablation should be used with caution to avoid injury to adjacent cartilage on the femoral and tibial condyles.

The stepwise progression of our arthroscopic saucerization process is shown in Figure 6. As the discoid meniscus is usually abnormally thick with smooth, rounded edges, an arthroscopic knife, basket punch forceps, or Iris scissors can be used to initiate the resection process for saucerization. Arthroscopic biters (Figure 7) are then used during piecemeal resection of the central portion of the discoid meniscus, followed by further debridement to a stable rim with the arthroscopic shaver.

A straight biter is used to resect the central portion of the discoid meniscus via the AM portal and can be used in combination with the upbiter to negotiate around the lateral femoral condyle to resect the meniscus body. This combination of the straight biter and the upbiter can also be used to resect the posterior horn of the meniscus efficiently through the AL portal with the AM portal used as the viewing portal. A backbiter can also facilitate resection of the anterior horn of the meniscus.

A significant number of discoid lateral meniscus tears have degeneration of the central portion of the meniscus with associated horizontal cleavage tears.<sup>22</sup> In our case, the horizontal tear became obvious as the saucerization was performed when the resection entered the area of




**Figure 6.** Stepwise progression of arthroscopic saucerization for a right knee discoid lateral meniscus viewed from the anterolateral portal. (A) Identification of compete discoid meniscus, (B) Assessment of meniscus stability with probe, (C) Anterior and posterior margins marked with radiofrequency ablation, (D) Resection of discoid meniscus starting with punch forceps, (E) to (H) Piecemeal resection of meniscal tissue with biters and debridement with shaver, LFC: lateral femoral condyle, DLM: Discoid lateral meniscus, ACL: Anterior cruciate ligament

mucoid degeneration. The horizontal tear was probed and found to extend into the peripheral regions of the meniscus (Figure 8).

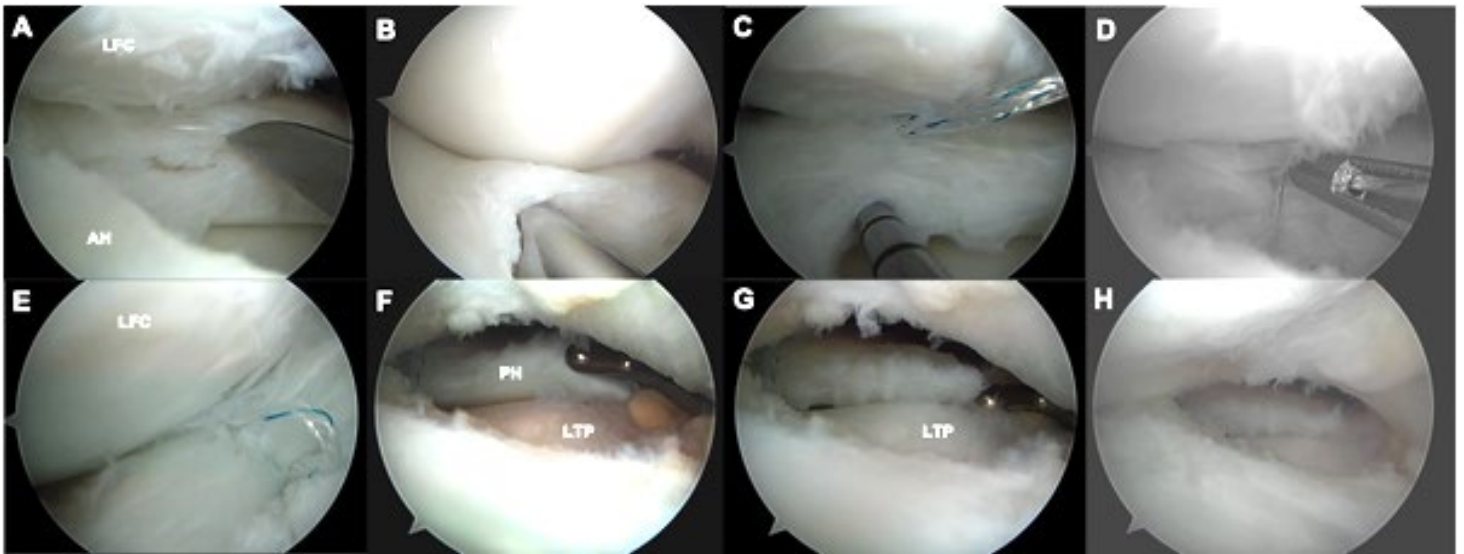
These horizontal tears are amenable to meniscus-based suture techniques that place sutures perpendicular to the horizontal tear.<sup>15,52,53</sup> After rasping, an all-inside meniscus repair was performed with a stitch placed to close the gap between the upper and lower leaves of the horizontal meniscus tear. The repair helps to allow the meniscus to heal and reduce the thickness of the meniscus. In a pediatric knee with limited access and space within the tibiofemoral compartment, the all-inside meniscus device allows such repairs to be performed. In larger tears where multiple stitches are required, the stitches should be placed 3–5 mm apart and at the edge of the tear to prevent propagation. These ‘hay bale’ sutures can help to improve meniscus healing after the horizontal meniscus repair.<sup>52,53</sup>

In cases of tears with peripheral rim instability, we recommend placing the first stitch in the capsular tissue

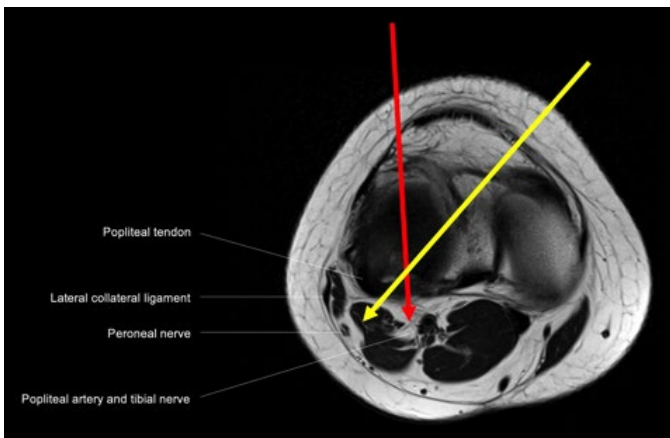


**Figure 7.** (A) Arthroscopic instruments useful in discoid meniscus surgery, (B) Right and left side biters, (C) Right and left back biters

for anchorage to facilitate subsequent reduction of the meniscus back onto the capsule and repair of the tear. For unstable, displaced tears where anatomical reduction cannot be maintained, holding stitches can be placed with an inside-out suture or an outside-in suture to secure reduction. An inside-out stitch may be used at the mid-body of the meniscus via zone-specific cannulas (30- to 45-degree angle) with exit point anterior to the biceps tendon to avoid risk to the posterior neurovascular structures; an outside-in stitch may be used for reduction of the anterior horn. Further placement of all-inside stitches can then be performed for repair of large



**Figure 8.** Arthroscopic all-inside repair of the right knee lateral discoid meniscus tear. (A) Horizontal cleavage tear at junction of body and posterior horn, (B) Meniscus tear debrided to stable rim with use of shaver, (C) to (E) All-inside repair of horizontal cleavage tear through the anteromedial portal, (F), (G) Assessment of lateral meniscus posterior horn stability post repair, (H) Final view after saucerization and tear repair, AH: Anterior horn of lateral meniscus, PH: Posterior horn of lateral meniscus, LTP: Lateral tibial plateau



**Figure 9.** T1 weighted MRI axial view of right knee showing proximity of neurovascular bundle and structures in close proximity to trajectories of arthroscopic instruments passing through anterolateral (red arrow) and anteromedial (yellow arrow) portals, respectively.

complex tears or tears in the red-white zone of the meniscus. The hybrid repair using these techniques is especially useful in discoid meniscus tears in adolescent patients who present with symptomatic large meniscus tears.

Special care must be taken when the viewing portal is switched to the AM portal and AL portal is used as the working portal for repair of the posterior horn of the me-

niscus. The cadaveric studies have shown that this portal combination brings the all-inside meniscus repair device closest to the posterior neurovascular structures.<sup>54</sup> This is especially significant in the pediatric knee with its small size and should be performed with adequate knowledge of the depth limit. Figure 9 shows the proximity of the neurovascular bundle and various structures that are in close proximity. The small knee size also increases the risk of damage to cartilage from instruments due to the constrained space.

Partial meniscectomies are performed in cases of meniscal tears that are irreparable. The most common reason for irreparability is degeneration in the meniscus tear, usually in the setting of delayed presentations, where sutures are unable to be passed through to achieve a stable, anatomical repair.

### Postoperative Care and Rehabilitation

For saucerizations that are performed without meniscal repair, we advocate for early mobilization and allow the patient full weight-bearing with full range of motion in the knee as tolerated immediately after surgery. The goal is to reduce postop stiffness and downtime so that the patient may achieve earlier return to function and sports.

When a concomitant meniscal repair is performed along with the saucerization, the patients are placed in a hinged knee brace to limit deep knee flexion and are kept on protected weight-bearing for 6 weeks to protect the repair. Isometric quadriceps strengthening is started immediately after surgery for all patients. Our general protocol for range of motion is 0-90 degrees flexion in the hinged knee brace in the first 6 weeks, and the hinged knee brace is taken off after. Full range of motion and full weight-bearing is allowed after 6 weeks. Return to sports is generally permitted at 6–9 months post-surgery, depending on progress in strength recovery.

Depending on the location of tear, type of repair, patient's functional needs, and compliance, this rehabilitation protocol may be adjusted and tailored to each individual patient's needs.

## Discussion

In our earlier series of 24 knees with symptomatic discoid lateral meniscus that underwent saucerization with 8 mm residual peripheral meniscus, significant improvements were achieved in both Lysholm and Ikeuchi scores ( $p < 0.001$ ) over the median follow-up time frame 84 months (range 68–110 months).<sup>10</sup> Median Lysholm score improved to 100 postoperatively from 53 preoperatively, and all 24 knees were rated to have good-excellent results postoperatively on Ikeuchi scores.<sup>10</sup>

Nineteen of the 24 knees had concomitant meniscal tears, all of which were addressed surgically with either the all-inside repair technique or with partial meniscectomy if the tear was deemed irreparable.<sup>10</sup> On subgroup analysis, outcomes of saucerizations with concomitant meniscal repair or partial meniscectomies performed were similar compared to those who had saucerizations performed alone.<sup>10</sup> There were no immediate- or long-term complications in this series, which includes clinically apparent re-tears, instability, recurrent effusion, bleeding, and arthrofibrosis over the study time frame—and no repeat arthroscopies were performed.

Our findings of good outcomes are in line with several earlier studies on meniscoplasty for the discoid

meniscus on short- and mid-term follow-up,<sup>6,29,33,36,55-62</sup> and with Chedels et al.'s long-term outcomes albeit their older patient population with adult patients as the majority.<sup>3</sup>

As the meniscus starts off completely vascular at birth and gradually diminishes over time, dropping to 10% to 30% to resemble the adult meniscus by age 10 years,<sup>27</sup> the reparative potential may be higher in the pediatric population compared to adults with the increased blood supply.<sup>23</sup> Bisicchia et al.'s case report of re-growth of an incomplete discoid lateral meniscus after arthroscopic partial resection in an 11-year-old boy<sup>63</sup> and Stein et al.'s case report of discoid meniscus regeneration in a 5-year-old girl after prior saucerization<sup>64</sup> are encouraging evidence in support of this theory. Tears that extend to areas that have yet to become avascular may therefore heal in this younger population, making saucerization and meniscal repair in this age group potentially able to yield even better outcomes on long term follow-up.

The discoid lateral meniscus has a higher risk of injury to the meniscus compared to the normal meniscus and are innately different between the complete and incomplete types both histologically and biologically.<sup>65</sup> The complete discoid lateral menisci are also more likely to have associated tears compared to incomplete discoid lateral menisci<sup>19</sup> and are more likely to have a horizontal tear configuration, compared to the incomplete discoid lateral menisci where higher frequencies of radial tears have been reported.<sup>2,19,20</sup> Surgeons should thus be vigilant in the inspection for associated tears in the complete discoid lateral meniscus, which may not be apparent until after saucerization, especially in the small pediatric knee.

Koh et al. advocated repair or minimal resection of meniscal tissue in horizontal cleavage tears based on cadaveric biomechanical findings of substantially decreased contact area and increased contact pressure with resection of either one or both leaves of the horizontal tear.<sup>14</sup> Efforts should therefore be made to conserve meniscal tissue as much as possible, especially when dealing with the pediatric patient population to reduce degenerative

change over time. Importantly, repair of the degenerative horizontal tear can yield good results,<sup>15,16,17</sup> evidenced by validated patient reported outcomes scores<sup>15,16,17</sup> and healing rates on follow-up arthroscopy.<sup>16</sup>

Meniscus repair preserves meniscus tissue and is complementary to saucerization in the management the symptomatic discoid lateral meniscus where degenerative tears and instability are common as it addresses both tears and instability to improve load transmission. This may be especially useful in the younger patient population for healing given their improved blood supply compared to adults. In cases of difficult reductions and complex tears, hybrid meniscus repairs using the inside-out, outside-in, and all-inside meniscus repair techniques can be used for best results.

## Summary

Saucerization of the discoid lateral meniscus to leave 8 mm of residual peripheral meniscus recreates the standard crescent shaped meniscus with good mid- to long-term outcomes and is well suited to the pediatric and adolescent population. Concomitant meniscus repair to address meniscal tears and instability in conjunction with the saucerization allows improved load transmission and should be performed to prevent the development of secondary osteoarthritis.

## Additional Links

*Discoid Meniscus:* <https://bit.ly/3nfruCq>

*Arthroscopic Saucerization for Discoid Lateral Meniscus:* <https://bit.ly/3noN5IL>

## References

- Kim JG, Han SW, Lee DH. Diagnosis and Treatment of Discoid Meniscus. *Knee Surg Relat Res.* 2016;28(4):255-262.
- Bin SI, Kim JC, Kim JM, et al. Correlation between type of discoid lateral menisci and tear pattern. *Knee Surg Sports Traumatol Arthrosc.* 2002 Jul;10(4):218-22.
- Chedal-Bornu B, Morin V, Saragaglia D. Meniscopectomy for lateral discoid meniscus tears: Long-term results of 14 cases. *Orthop Traumatol Surg Res.* 2015 Oct;101(6):699-702.
- Ikeuchi H. Arthroscopic treatment of the discoid lateral meniscus. Technique and long-term results. *Clin Orthop Relat Res.* 1982 Jul;(167):19-28.
- Seong SC, Park MJ. Analysis of the discoid meniscus in Koreans. *Orthopedics.* 1992 Jan;15(1):61-5.
- Wasser L, Knörr J, Accadbled F, et al. Arthroscopic treatment of discoid meniscus in children: clinical and MRI results. *Orthop Traumatol Surg Res.* 2011 May;97(3):297-303.
- Kelly BT, Green DW. Discoid lateral meniscus in children. *Curr Opin Pediatr.* 2002;14:54-61.
- Fleissner PR, Eilert RE. Discoid lateral meniscus. *Am J Knee Surg.* 1999;12:125-31.
- Yaniv M, Blumberg N. The discoid meniscus. *J Child Orthop.* 2007;1:89-96.
- Ng YH, Tan SHS, Lim AKS, et al. Meniscopectomy leads to good mid-term to long-term outcomes for children and adolescents with discoid lateral meniscus. *Knee Surg Sports Traumatol Arthrosc.* 2021 Feb;29(2):352-357.
- McDermott ID, Amis AA. The consequences of meniscectomy. *J Bone Joint Surg Br.* 2006 Dec;88(12):1549-56.
- Ahn JH, Kim KI, Wang JH, et al. Long-term results of arthroscopic reshaping for symptomatic discoid lateral meniscus in children. *Arthroscopy.* 2015 May;31(5):867-73.
- Okazaki K, Miura H, Matsuda S, et al. Arthroscopic resection of the discoid lateral meniscus: long-term follow-up for 16 years. *Arthroscopy.* 2006 Sep;22(9):967-71.
- Koh JL, Yi SJ, Ren Y, et al. Tibiofemoral Contact Mechanics with Horizontal Cleavage Tear and Resection of the Medial Meniscus in the Human Knee. *J Bone Joint Surg Am.* 2016 Nov 2;98(21):1829-1836.
- Tiftikçi U, Serbest S. Repair of isolated horizontal meniscal tears with all-inside suture materials using the overlock method: outcome study with a minimum 2-year follow-up. *J Orthop Surg Res.* 2016 Oct 28;11(1):131.
- Kamimura T, Kimura M. Meniscal Repair of Degenerative Horizontal Cleavage Tears Using Fibrin Clots: Clinical and Arthroscopic Outcomes in 10 Cases. *Orthop J Sports Med.* 2014 Nov 10;2(11):2325967114555678.
- Kurzweil P, Krych AJ, Anz A, et al. Favorable Reoperation Rate at 2 Years Following Repair of Horizontal Cleavage Tears Using an All Suture-Based Technique: A

- Prospective, Multicenter Trial. *Arthrosc Sports Med Rehabil*. 2021 Mar 13;3(3):e773-e780.
18. Tapasvi S, Shekhar A, Eriksson K. Discoid lateral meniscus: current concepts. *J ISAKOS*. 2021 Jan;6(1):14-21.
19. Yamaguchi N, Chosa E, Tajima T, et al. Symptomatic discoid lateral meniscus shows a relationship between types and tear patterns, and between causes of clinical symptom onset and the age distribution. *Knee Surg Sports Traumatol Arthrosc*. 2021 Jun 10.
20. Chen G, Zhang Z, Li J. Symptomatic discoid lateral meniscus: a clinical and arthroscopic study in a Chinese population. *BMC Musculoskelet Disord*. 2016 Aug 5;17:329.
21. Restrepo R, Weisberg MD, Pevsner R, et al. Discoid Meniscus in the Pediatric Population:: Emphasis on MR Imaging Signs of Instability. *Magn Reson Imaging Clin N Am*. 2019 May;27(2):323-339
22. Elvey MH, Konan S, House CV, et al. Horizontal cleavage tear of discoid medial meniscus diagnosed on MRI and treated with arthroscopic partial resection. *Knee Surg Sports Traumatol Arthrosc*. 2011;19(11):1860-1867.
23. Watanabe M, Takeda S, Ikeuchi H. *Atlas of arthroscopy*. 3rd ed. Tokyo: Igaku-Shoin; 1979. pp. 75-130.
24. Papadopoulos A, Kirkos JM, Kapetanios GA. Histomorphologic study of discoid meniscus. *Arthroscopy*. 2009;25:262-8.
25. Kramer DE, Micheli LJ. Meniscal tears and discoid meniscus in children: diagnosis and treatment. *J Am Acad Orthop Surg*. 2009;17:698-707.
26. Atay OA, Pekmezci M, Doral MN, et al. Discoid meniscus: an ultrastructural study with transmission electron microscopy. *Am J Sports Med*. 2007;35:475-8.
27. Clark CR, Ogden JA. Development of the menisci of the human knee joint. Morphological changes and their potential role in childhood meniscal injury. *J Bone Joint Surg Am*. 1983 Apr;65(4):538-47.
28. Hart ES, Kalra KP, Grottkau BE, et al. Discoid lateral meniscus in children. *Orthop Nurs*. 2008 May-Jun;27(3):174-9; quiz 180-1.
29. Chambers HG, Chambers RC. The Natural History of Meniscus Tears. *J Pediatr Orthop*. 2019 Jul;39(Issue 6, Supplement 1 Suppl 1):S53-S55.
30. Kushare I, Klingele K, Samora W. Discoid Meniscus: Diagnosis and Management. *Orthop Clin North Am*. 2015 Oct;46(4):533-40.
31. Ahn JH, Lee YS, Ha HC, et al. A novel magnetic resonance imaging classification of discoid lateral meniscus based on peripheral attachment. *Am J Sports Med*. 2009;37:1564-9.
32. Ahn JH, Lee SH, Yoo JC, et al. Arthroscopic partial meniscectomy with repair of the peripheral tear for symptomatic discoid lateral meniscus in children: results of minimum 2 years of follow-up. *Arthroscopy*. 2008;24:888-98.
33. Wong T, Wang CJ. Functional analysis on the treatment of torn discoid lateral meniscus. *Knee*. 2011 Dec;18(6):369-72.
34. Singh K, Helms CA, Jacobs MT, et al. MRI appearance of Wrisberg variant of discoid lateral meniscus. *AJR Am J Roentgenol*. 2006 Aug;187(2):384-7.
35. Klingele KE, Kocher MS, Hresko MT, et al. Discoid lateral meniscus: prevalence of peripheral rim instability. *J Pediatr Orthop*. 2004;24:79-82.
36. Good CR, Green DW, Griffith MH, et al. Arthroscopic treatment of symptomatic discoid meniscus in children: classification, technique, and results. *Arthroscopy*. 2007;23:157-63.
37. Hayashi LK, Yamaga H, Ida K, et al. Arthroscopic meniscectomy for discoid lateral meniscus in children. *J Bone Joint Surg Am*. 1988 Dec;70(10):1495-500.
38. Moser MW, Dugas J, Hartzell J, et al. A hypermobile Wrisberg variant lateral discoid meniscus seen on MRI. *Clin Orthop Relat Res*. 2007 Mar;456:264-7.
39. Van Steyn MO, Mariscalco MW, Pedroza AD, et al. The hypermobile lateral meniscus: a retrospective review of presentation, imaging, treatment, and results. *Knee Surg Sports Traumatol Arthrosc*. 2016 May;24(5):1555-9.
40. Dickhaut SC, DeLee JC. The discoid lateral-meniscus syndrome. *J Bone Joint Surg Am*. 1982 Sep;64(7):1068-73.
41. Mutlu S, Mutlu H, Mutlu B, et al. Symptoms of discoid lateral menisci. *J Orthop*. 2014;11(4):180-182.
42. Patel NM, Cody SR, Ganley TJ. Symptomatic bilateral discoid menisci in children: a comparison with unilaterally symptomatic patients. *J Pediatr Orthop*. 2012 Jan-Feb;32(1):5-8.

43. Kelly BT, Green DW. Discoid lateral meniscus in children. *Curr Opin Pediatr*. 2002 Feb;14(1):54-61.
44. Andrish JT. Meniscal Injuries in Children and Adolescents: Diagnosis and Management. *J Am Acad Orthop Surg*. 1996 Oct;4(5):231-237.
45. Rao PS, Rao SK, Paul R. Clinical, radiologic, and arthroscopic assessment of discoid lateral meniscus. *Arthroscopy*. 2001 Mar;17(3):275-277.
46. Silverman JM, Mink JH, Deutsch AL. Discoid menisci of the knee: MR imaging appearance. *Radiology*. 1989 Nov;173(2):351-4.
47. Samoto N, Kozuma M, Tokuhisa T, et al. Diagnosis of discoid lateral meniscus of the knee on MR imaging. *Magn Reson Imaging*. 2002 Jan;20(1):59-64.
48. Araki Y, Ashikaga R, Fujii K, et al. MR imaging of meniscal tears with discoid lateral meniscus. *Eur J Radiol*. 1998 May;27(2):153-60.
49. Francavilla ML, Restrepo R, Zamora KW, et al. Meniscal pathology in children: differences and similarities with the adult meniscus. *Pediatr Radiol*. 2014 Aug;44(8):910-25; quiz 907-9.
50. Pai DR, Strouse PJ. MRI of the pediatric knee. *AJR Am J Roentgenol*. 2011 May;196(5):1019-27.
51. Cuéllar A, Cuéllar R, Cuéllar A, et al. The Effect of Knee Flexion Angle on the Neurovascular Safety of All-Inside Lateral Meniscus Repair: A Cadaveric Study. *Arthroscopy*. 2015;31(11):2138-2144.
52. Saliman JD. The circumferential compression stitch for meniscus repair. *Arthrosc Tech*. 2013 Jul 12;2(3):e257-64.
53. Woodmass JM, Johnson JD, Wu IT, et al. Horizontal Cleavage Meniscus Tear Treated With All-inside Circumferential Compression Stitches. *Arthrosc Tech*. 2017 Aug 14;6(4):e1329-e1333.
54. Mao DW, Upadhyay U, Thalanki S, et al. All-Inside Lateral Meniscal Repair via Anterolateral Portal Increases Risk of Vascular Injury: A Cadaveric Study. *Arthroscopy*. 2020;36(1):225-232.
55. Atanda A Jr, Wallace M, Bober MB, Mackenzie W. Arthroscopic Treatment of Discoid Lateral Meniscus Tears in Children With Achondroplasia. *J Pediatr Orthop*. 2016;36(5):e55-e58.
56. Carabajal M, Allende GJ, Masquijo JJ. Mid-term results of arthroscopic remodelling combined with peripheral repair in children with unstable discoid meniscus. Resultados a mediano plazo de la remodelación artroscópica asociada a reparación periférica en niños con menisco discoidal inestable. *Rev Esp Cir Ortop Traumatol (Engl Ed)*. 2020;64(3):206-212.
57. Carter CW, Hoellwarth J, Weiss JM. Clinical outcomes as a function of meniscal stability in the discoid meniscus: a preliminary report. *J Pediatr Orthop*. 2012;32(1):9-14.
58. Hagino T, Ochiai S, Senga S, et al. Arthroscopic treatment of symptomatic discoid meniscus in children. *Arch Orthop Trauma Surg*. 2017 Jan;137(1):89-94.
59. Haskel JD, Uppstrom TJ, Dare DM, et al. Decline in clinical scores at long-term follow-up of arthroscopically treated discoid lateral meniscus in children. *Knee Surg Sports Traumatol Arthrosc*. 2018 Oct;26(10):2906-2911.
60. Kose O, Celiktas M, Egerci OF, et al. Prognostic factors affecting the outcome of arthroscopic saucerization in discoid lateral meniscus: a retrospective analysis of 48 cases. *Musculoskelet Surg*. 2015 Aug;99(2):165-70.
61. Lee SW, Chun YM, Choi CH, et al. Single-leaf partial meniscectomy in extensive horizontal tears of the discoid lateral meniscus: Does decreased peripheral meniscal thickness affect outcomes? (Mean four-year follow-up). *Knee*. 2016 Jun;23(3):472-7.
62. Ohnishi Y, Nakashima H, Suzuki H, et al. Arthroscopic treatment for symptomatic lateral discoid meniscus: The effects of different ages, groups and procedures on surgical outcomes. *Knee*. 2018 Dec;25(6):1083-1090.
63. Bisicchia S, Tudisco C. Re-growth of an incomplete discoid lateral meniscus after arthroscopic partial resection in an 11 year-old boy: a case report. *BMC Musculoskelet Disord*. 2013 Oct 7;14:285.
64. Stein MI, Gaskins RB 3rd, Nalley CC, et al. Regeneration of a discoid meniscus after arthroscopic saucerization. *Am J Orthop (Belle Mead NJ)*. 2013 Jan;42(1):E5-8.
65. Inoue H, Furumatsu T, Machara A, et al. Histological and biological comparisons between complete and incomplete discoid lateral meniscus. *Connect Tissue Res*. 2016 Sep;57(5):408-16.