

Sentence comprehension among healthy cognitive ageing adults: an fMRI study

Afrina Sallehuddin ^{1*}, Mazlyfarina Mohamad ^{1*}, Elyqa Farra Nabillah Mohamad Ariffin ¹, Neil Russell Mennie ², Rogayah A Razak ³, Mohd Azmarul A Aziz ⁴, Mizhanim Mohamad Shahimin ¹, Leong Yuh Yang ⁵, Norshuhada Sahnun ⁶ and Muhammad Shahidan Muhammad Sakri ⁷

¹ Faculty of Health Sciences, Universiti Kebangsaan Malaysia, Kuala Lumpur, Malaysia.

² Faculty of Psychology, Chulalongkorn University, Bangkok, Thailand.

³ Faculty of Social Sciences and Liberal Arts, UCSI University, Kuala Lumpur, Malaysia.

⁴ School of Health Sciences, Universiti Sains Malaysia, Kelantan, Malaysia.

⁵ Department of Radiology, Hospital Chanselor Tunku Mukhriz, Kuala Lumpur, Malaysia.

⁶ Department of Radiology, UKM Specialist Children's Hospital, Kuala Lumpur, Malaysia.

⁷ Aerobe Sdn. Bhd., Kuala Lumpur, Malaysia.

* Correspondence: sallehuddinafrina@gmail.com, mazlyfarina@ukm.edu.my; Tel.: +6016-200-4557

Received: 16 June 2024; **Accepted:** 9 September 2024; **Published:** 15 March 2025

Edited by: Norshariza Nordin (Universiti Putra Malaysia, Malaysia)

Reviewed by: Nurfaizatul Aisyah Ab Aziz (Universiti Sains Malaysia, Malaysia);

Kheng Seang Lim (Universiti of Malaya, Malaysia); Rafaella Georgiou (University of Ioannina, Greece);

Konstantinos Drosos (European University Cyprus, Cyprus)

<https://doi.org/10.31117/neuroscirn.v8i1.376>

Abstract: Language performance issues can occur before impairments in episodic memory, visuospatial construction ability, or mental state in those at risk for mild cognitive impairment (MCI). However, the neural basis for this change is unclear. This study aimed to investigate the neural correlates of sentence comprehension in healthy cognitive ageing (HCA). Thirteen healthy, elderly subjects between the age of 50-70 years old were recruited within Klang Valley. Functional magnetic resonance imaging (fMRI) scanning was conducted while participants engaged in a Malay picture-to-sentence matching comprehension task. During the task, participants silently read a sentence and were required to select one of three images that best describes the context of the sentence. The fMRI data were analysed using statistical parametric mapping (SPM12) to identify brain regions involved in sentence comprehension. Results showed activation in the left inferior occipital gyrus (IOG), medial temporal gyrus (MTG), inferior temporal gyrus (ITG), inferior frontal gyrus (IFG), and left parietal lobe, suggesting that these areas are involved in sentence processing. We conclude that HCAs present similar patterns of neural brain activation, and these regions are integrated to support sentence comprehension processing. Further research may include younger adults and a larger population sample to better represent findings in the Malaysian ageing population.

Keywords: Sentence comprehension; Aging; fMRI; Language; Brain imaging

©2025 by Sallehuddin *et al.* for use and distribution according to the Creative Commons Attribution (CC BY-NC 4.0) license (<https://creativecommons.org/licenses/by-nc/4.0/>), which permits unrestricted non-commercial use, distribution, and reproduction in any medium, provided the original author and source are credited.

1.0 INTRODUCTION

Malaysia's geriatric population has rapidly increased in recent years. According to the Department of Statistics Malaysia (DOSM), Malaysia is expected to become an old-age nation by 2030, as the percentage of people aged 65 years and over has increased from 7.0% to 7.3%. Age-related disorders, such as cognitive impairment and dementia, will increase rapidly in the future, paralleling global ageing and becoming a pressing issue in Malaysia ([Hussin et al., 2019](#); [Lai et al., 2022](#)). The National Health and Mobility 2018: Elderly Study reported an 8.7% prevalence of dementia among the Malaysian older population, higher than the average 5% to 8% worldwide prevalence of dementia declared by the World Health Organisation (WHO) ([Institute for Public Health, 2019](#)). With increasing life expectancy, older adults must preserve and improve their cognitive abilities to sustain their independence and quality of life ([Gavelin et al., 2020](#)).

Language production deficits occur early during Alzheimer's disease (AD) ([Pistono et al., 2021](#)). Language impairment in AD is continuous and affects several domains. These impairments include confrontational naming, information retrieval, verbal paraphrasing, language comprehension, complex sentences, and semantic and syntactic processing ([Nasiri et al., 2022](#)). Although sensory and cognitive deterioration is common in the elderly ([Peelle et al., 2010](#)), language abilities exhibit impaired and spared performance patterns. Language comprehension in healthy ageing may be stable under certain conditions but may struggle to comprehend spoken phrases when rendered more challenging by linguistic or auditory difficulties ([Lee et al., 2022](#)).

Sentence comprehension (SC) is the process of interpreting the strings of information or meanings of individual words within a sentence. From a linguistic perspective, understanding a sentence involves the following three phases. It starts with syntactic and lexical parsing, assigns thematic roles, and builds a conceptual sentence representation. Age-related declines in language comprehension have been extensively reported in the literature ([Grossman et al., 2002](#); [Dede et al., 2016](#); [Fitzhugh et al., 2019](#)). Substantial evidence supports the claim that the elderly face challenges in understanding grammatically complicated sentences compared to younger subjects ([Park & Reuter-Lorenz, 2009](#); [Diaz et al., 2014](#)).

SC is a critical language task that calls on cognitive and linguistic abilities and necessitates processing several

components that establish word dependencies at the sentence level. Sentence-related activities can also help detect distinct phases of cognitive deficits. They can be used to identify not only elementary grammar problems but also cognitive capacities in different subtypes of MCI ([Segkouli et al., 2017](#)).

Given that language impairment is common in AD. It occurs early in the disease course; Taler & Phillips ([2008](#)) believed that MCI individuals' performance on language tasks is timely and will contribute to the goal of identifying early markers of cognitive impairment in AD. They also highlighted evidence that patients with MCI who have impairments in various domains, including language, are more likely to acquire AD than those with only memory impairment.

The feasibility of using fMRI to map language-related functions has been demonstrated in previous studies ([De Carli et al., 2007](#); [Agarwal et al., 2019](#)). fMRI is a class of imaging methods developed to demonstrate regional and time-varying alterations in brain metabolism ([Glover, 2011](#)). These metabolic changes can result from task-induced changes in the cognitive state or unregulated processes in the resting brain. It is a non-invasive technology for determining which brain areas are active in cognitive function and their pattern and extent of activity. In this study, we used task-based fMRI with the blood oxygenation level-dependent (BOLD) method, one of the most common methods used to study the functional organisation of the brain ([Batouli & Sisakhti, 2020](#)).

Malay, also known as Bahasa Indonesia (in Indonesia) and Bahasa Melayu (in Malaysia, Singapore, and Brunei), is primarily spoken in Southeast Asia. Malay and English have similarities; both are subject-verb-object (SVO) word-order languages with similar typological (syntactic) characteristics ([Laumann et al., 2017](#)). However, there are differences in sentence comprehension between Malay and English, possibly due to differences in morphology and syntax ([Mat Awal et al., 2007](#); [Rusli & Montgomery, 2020](#)).

For sentence structures, both English and Malay have the word order of subject-verb-object (SVO) i.e., Akram is cleaning his room/*Akram sedang membersihkan biliknya* ([How et al., 2015](#); [Yap et al., 2017](#); [Aziz et al., 2020](#)). Given Malaysia is a multilingual and multicultural country, the languages spoken are broadly diglossic and polyglossic ([Yap et al., 2017](#)). The diversity of languages poses challenges for monolingual assessment scales developed in English and based on Western norms to

represent the multilingual Malaysian population. Therefore, the adapted version of the sentence-to-picture naming task ([Aziz et al., 2020](#)) helps to reduce variability in that the items have been adapted to suit the culture and language of the Malaysian adult population.

Acknowledging the differences in morphology and syntax properties between the Malay language and English ([Azmi et al., 2016](#)), we aim to investigate the brain networks responsible for sentence comprehension among Malaysian healthy ageing adults (HCA). Our objectives: (1) employ an experimental design to investigate the brain networks responsible for sentence comprehension in HCA and (2) to determine the association of behavioural data extracted from the Malay sentence-to-picture matching task ([Aziz et al., 2020](#)) with the activation of brain areas involved in sentence comprehension among the HCAs.

According to previous neuroimaging studies ([Binder et al., 2017](#); [Walenski et al., 2019](#)), we hypothesised that specific brain networks, particularly in the left hemisphere (e.g. Broca's and Wernicke's areas), would also be activated for SC in Malaysian HCA adults. Besides, we predict a significant association between the behavioural performance on the Malay sentence-to-picture matching task and the activation of brain regions involved in SC, such that better task performance correlates with increased activation in these regions. This information is relevant for neuropsychologists, speech therapists, neurosurgeons, and other healthcare professionals who assess language impairments in patients in Malaysia.

2.0 MATERIALS AND METHODS

This is a cross-sectional study. The Universiti Kebangsaan Malaysia (UKM) Ethics Committee (IEC) (JEP-2022-061) granted ethics approval, and written consent was obtained from participants before testing.

2.1 Participants

Thirteen (7 females) right-handed healthy Malaysian older adults, aged between 50 and 70 years old (mean 59.1 years \pm 5.6) residing within Klang Valley, participated in this study (**Table 1**).

We employed a convenient sampling method. All participants were screened for eligibility before the survey based on the inclusion and exclusion criteria. Inclusion criteria were that subjects were fluent in *Bahasa Melayu* or Malay language, had no medical history of Alzheimer's or other psychiatric, neurological,

or cognitive impairment disorders based on the DSM-5 criteria, and were cooperative for MRI. Participants were excluded if they acquired any form of visual impairment (i.e., low visual acuity, astigmatism, cataract, colour blindness), Parkinson's disease, substance misuse, or any structural abnormalities.

Table 1. Demographic and performance data were obtained from 13 healthy cognitive aging (HCA) participants.

Parameters	All (Mean \pm SD)
Age	59.1 \pm 5.61
Years of education	11.8 \pm 3.24
Language proficiency score (%)	80.1 \pm 4.3
IADL score	7.7 \pm 0.76
CDR score	0.50 \pm 0.76
Malay picture-to-sentence matching (SC) accuract rate (%)	47.7 \pm 10.8
Malay picture-to-sentence matching (SC) RT time (milliseconds)	7643 \pm 7887

CDR: Clinical dementia rating; IADL: Lawton instrumental activities of daily living scale; RT: Response time; SC: Sentence comprehension; SD: Standard deviation.

2.2 Cognitive function, social activity, and physical functioning assessments

The screening stage includes participants undergoing a face-to-face or call interview to be selected for participation. To examine whether participants were cognitively healthy, a clinical dementia rating (CDR) scale was administered to detect potential signs of mild cognitive impairment or dementia, with severity ratings in the range of a 5-point scale (0 = None; 0.5 = Questionable; 1.0 = MCI; 2.0 = Moderate MCI; 3.0 = Severe). The CDR assesses several domains, such as memory, attention, judgment and problem-solving, community affairs, home and hobbies, and personal care ([Manning & Ducharme, 2010](#)). The rating for MCI on the CDR is staged at the 1.0 level.

The Lawton Instrumental Activities of Daily Living Scale (IADL)-Malay Version evaluation test ([Kadar et al., 2018](#)) was performed to examine the functional ability of the subjects ([Lawton & Brody, 1969](#)). Participants were asked to rate themselves (0 = unable or need assistance; 1 = slightly able; 2 = able) on their ability to use a telephone, do housekeeping, prepare food, perform laundry, transport mobility, medication handling, financial management, and purchase items. Obtaining a score of >14 indicates mild and severe functional disabilities. These items are scored by (0/14), where 14 items indicate full function and a lower score reflects a higher level of dependency.

2.3 Sentence comprehension task

The Malay sentence-to-picture matching task, developed by Aziz et al. (2020), was designed as a structured assessment to evaluate sentence comprehension, focusing on two key conditions: reversibility and complexity. The task aimed to measure participants' abilities to understand both active and passive reversible sentences. Verbs were selected for familiarity and imageability to ensure they were relevant and easily understood by the participants. The task consists of 40 sentences, with 20 active and 20 passive sentences (refer to the examples below) respectively. These stimuli were individually listed and presented to participants using the E-Prime 3.0 program (Figure 1) (Psychology Software Tools, 2016), a comprehensive stimulus presentation software. Participants had to correctly match either of three displayed images to the corresponding sentence. These stimuli were derived from the work of Aziz et al. (2020), which outlines the development and validation of this assessment tool.

Active Sentence

"Wanita itu sedang menunggu bas di perhentian bas"

Translation: The woman is waiting for the bus at the bus stop.

Passive Sentence

"Kek yang berada di atas meja itu telah dimakan habis oleh Amir"

Translation: The cake on the table has been finished by Amir.

2.4 fMRI data and image acquisition

fMRI scans were conducted in the Department of Radiology, UKM Specialist Children's Hospital, in Cheras, Federal Territory of Kuala Lumpur, Malaysia. Functional images were acquired using a 3T magnetic resonance imaging (MRI) system (MAGNETOM Skyra, Siemens AG Healthcare, Erlangen, Germany) equipped with a blood oxygenation level-dependent imaging protocol and echo-planar imaging capabilities, and a radiofrequency head coil was used for signal transmission and reception.

A gradient-echo echo-planar imaging pulse sequence with the following parameters was used: repetition time (TR) = 2190 ms, echo time (TE) = 26 ms, flip angle (FA) = 90°, field of view (FOV) = 220 × 220 mm, matrix size = 64 × 64, resolution = 3 × 3 mm², interleaved sequence: 41 slices per volume with a distance between slices of 1 mm and slice thickness of 3 mm. In addition, high-resolution anatomical images of the entire brain were

obtained using a T1-weighted multiplanar reconstruction (MPR) spin-echo pulse sequence with the following parameters: TR = 1900 ms, FOV = 220 × 220 mm, FA = 8°, matrix size = 64 × 64, and slice thickness = 1 mm. The total duration of the structural and functional imaging scans was approximately 30 min.

2.5 Procedures

All participants received thorough instructions on responding to the stimuli before scanning. Before entering the magnet bore, participants were instructed on the word-by-word presentation method and probe. As head movements can result in signal intensity fluctuations over time from any one voxel and offer a major confounder in fMRI examinations, the subjects were also instructed not to move their heads during the scan. Along with the head coil, immobilising devices were employed to reduce head movement.

A training session was also conducted to ensure all participants understood the task. When everything was ready, the SC tasks began, and behavioural accuracy was evaluated while imaging data were collected. Participants indicated their response by pressing one of the four buttons with the thumb and index finger of the left or right hand. The participants responded to a sentence as soon as they felt they had the correct response, and the subject's response initiated the next sentence. Visual stimuli were back-projected onto a screen using an LCD projector compatible with high magnetic fields. The subject viewed the screen using a mirror system on the head coil.

2.6 Preprocessing and functional imaging data analysis

All the functional (T2*-weighted), structural (T1-weighted) images and image analyses were processed and performed on a personal computer utilising the software MATLAB 9.13 R2022b (C. Moler, MathWorks Inc., USA) and Statistical Parametric Mapping (SPM12) (Functional Imaging Laboratory, Wellcome Department of Imaging Neuroscience, Institute of Neurology, University College of London). Raw data in Digital Imaging and Communication (DICOM) (.dcm) formats were converted into the Neuroimaging Informatics Technology Initiative (NIFTI) (.nii) format.

The first eight EPI scans were removed to avoid magnetic saturation, and the slice-timing correction was added to the preprocessing techniques (Parker et al., 2017). Subsequently, functional pictures were realigned to ensure the brain location was constant across all

Table 2: Activated regions during the sentence comprehension (SC) task.

Brain Region	Hemisphere (Left / Right)	Cluster Size	T Score	Coordinates (mm)		
				x	y	z
Occipital Inferior	R	461	10.21	33	-76	-1
Medial Temporal	L	294	8.98	-45	-73	-10
Inferior Temporal	L	176	6.57	39	5	32
Occipital Middle	L	204	7.47	-27	-67	29
	R	35	5.67	33	-67	26
Precentral	L	324	8.16	-39	5	32
Inferior Frontal	R	109	8.41	39	5	32
Angular	R	49	6.45	27	-58	44
Frontal Middle	R	80	6.51	36	8	59
Postcentral	L	22	5.16	-39	-40	59
	R	8	5.44	45	-28	50
Supplementary Motor Area	L	9	5.65	-9	11	53
	R	11	6.38	9	17	50
Parietal Supplementary	R	16	6.04	27	-64	59

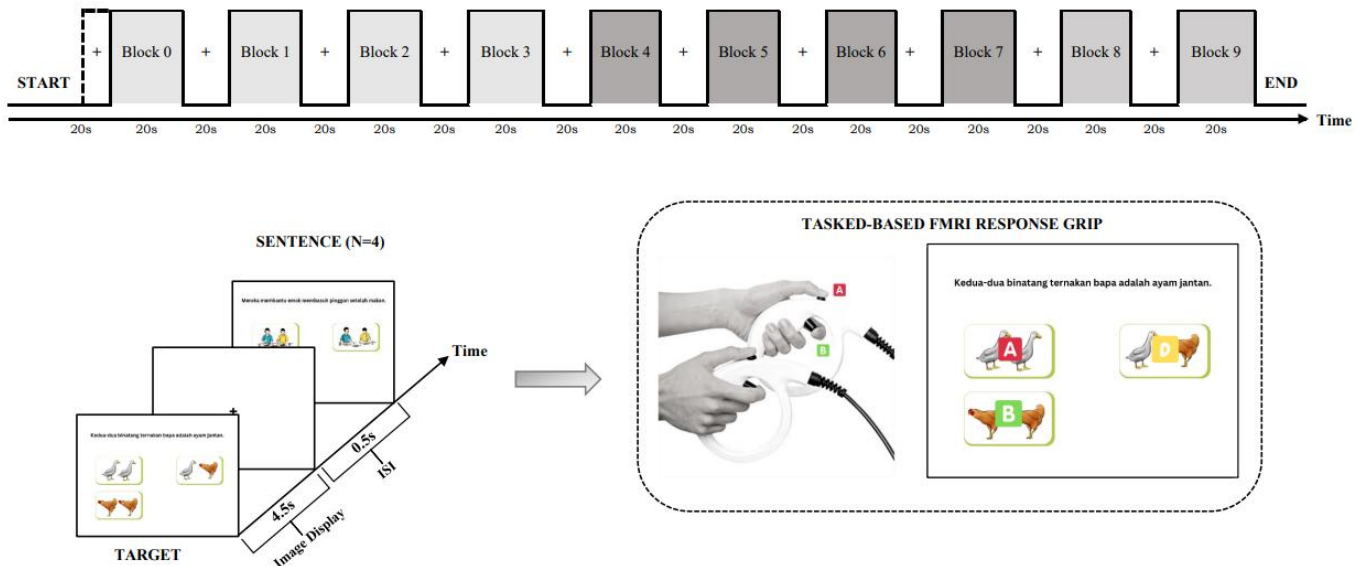


Figure 1. A block-design paradigm comprises 10 blocks, with 4 sentences and 12 images per block. A presentation stimulus consists of one sentence presented on top, with 3 images underneath. The stimulus for each block was presented in random order. The task begins with simple instructions and a fixation cross before the stimulus presentation. The duration of each stimulus presented is 4.5 seconds, with an inter-stimuli interval (+) of 0.5 seconds. The response key in E-Prime was altered to ensure task compatibility with the fMRI modality and response grip.

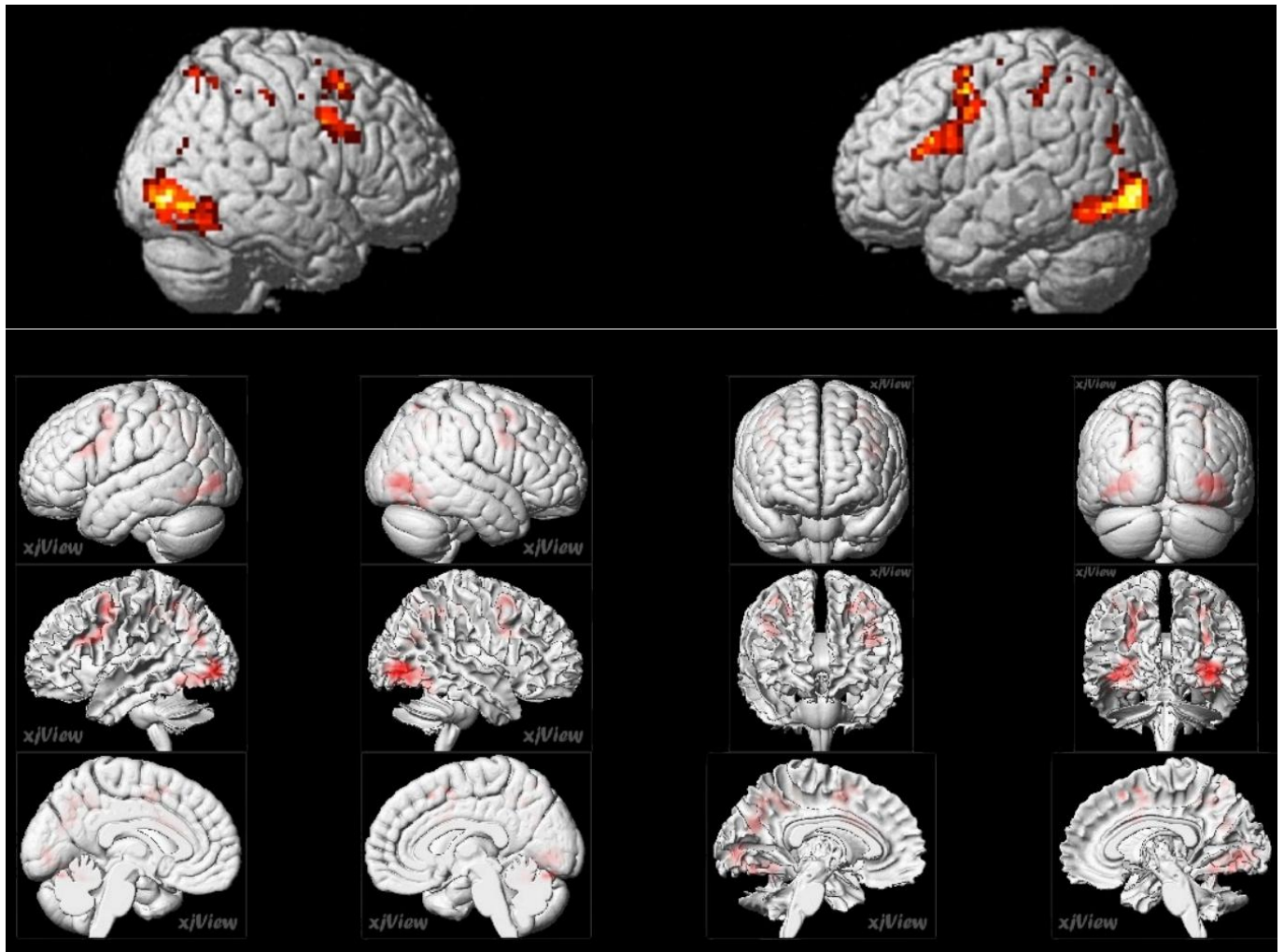


Figure 2. The highest activation was observed in the left occipital gyrus ($x=33, y=-76, z=-1$), significant at $P < 0.05$ (corrected for FWE) during the Malay-Sentence-to-Picture matching task among HCA participants. **Abbreviations:** FWE, family-wise error corrected.

images. This step was performed to rectify any movement of the subject throughout the scanning process. In addition, it was utilised to eliminate picture drift using a six-parameter affine transformation in the x , y , and z dimensions and the pitch, roll, and yaw directions.

Co-registration is necessary to register two images using the same or distinct modalities. A typical image processing approach for changing the range of pixel intensity values is normalisation. The data were normalised using SPM12's 12-parameter affine modifications to the Montreal Neurological Institute (MNI) template brain. Its principal role is to transform an input image into a set of easily identifiable pixel values (Zafar et al., 2015). Before incorporating nonlinear deformations, the brain images were matched to a template image using an affine transformation.

Subsequently, the images were smoothed with a 6-mm full-width-at-half maximum Gaussian kernel. According to Blaiotta et al. (2017), smoothing fMRI data can increase the signal-to-noise ratio (SNR) and sensitivity. A random-effects model was used to perform group-level analysis, commonly referred to as second-level analysis. Statistical maps were superimposed on normalised T1-weighted images. The SPM12 software's automated anatomical labelling Atlas 3 (AAL3v1) was used to name the activation cluster centroids and neighbouring areas of activation.

2.7 Statistical analyses

All data were analysed using the Statistical Package for Social Sciences (SPSS) version 28 (IBM Corp. in Armonk, NY). A significant value was set at $P < 0.05$. A Pearson correlation was used to determine the relationship between the mean accuracy score of the SC task and the

number of voxels in MFG and left IFG region among HCA ageing adults.

3.0 RESULTS

Table 1 provides descriptive statistics, including the mean age, response accuracy, education level, cognitive function, and social activity and physical assessment scores.

3.1 Whole brain analysis

Results obtained from group analysis of the fMRI data revealed a pattern of neural recruitment centred around the occipital, frontal, and parietal gyri. The Montreal Neurological Institute coordinates the significant activation sites found in the group analysis of the sample depicted in **Table 2** and **Figure 2**.

Results of the present study reveal that 15 significant clusters were activated with one cluster with duplicated brain regions. Cluster 1 is the primary cluster with 461 voxels activated. Brain regions activated across the frontal, parietal and occipital lobe with peak brain areas including the left cerebellum, bilateral inferior occipital gyrus (IOG), bilateral middle occipital gyrus (MOG), right opercular part of the inferior frontal gyrus (IFG), right middle frontal gyrus (MFG), right superior parietal gyrus (SPG), right angular gyrus (AG) and motor areas consisted of bilateral supplementary motor area (SMA), bilateral postcentral gyrus (post-CG) and left precentral gyrus (PCG).

3.2 ROI analysis

ROI analysis was performed on all subjects for every MNI coordinate of cortical areas active for SC tasks. However, correlation analyses using Pearson correlation between mean accuracy scores in SC tasks and the number of voxels among HCA participants are concentrated on the MFG and left IFG regions.

The results indicated that the relationship between the activation in the MFG region with the accuracy score was not significant, $r([13]) = [0.517]$, $p = [0.07]$. Similar findings were found for the IFG region, $r([13]) = [0.506]$, $p = [0.78]$, indicating no significant correlation between the two variables.

4.0 DISCUSSION

SC is a complex process involving coordinated activity of multiple brain regions, reflecting the degree of impairment an older adult may experience. SC activates a network of cortical areas in the brain, the most important of which are the left lateral superior temporal cortex (Wernicke's area) and the left inferior frontal

gyrus (Broca's area) ([Agarwal et al., 2019](#); [Walenski et al., 2019](#)). The present study investigated the neural networks for sentence comprehension among healthy cognitive Malaysian ageing adults (HCA). Following our results, SC tasks evoked brain activation in the cerebellum, IOG, MOG, IFG, MFG, SPG, AG, SMA, post-CG, and PCG. These findings support the hypothesis that Broca's and Wernicke's areas are activated during SC tasks, whereas Broca's area consists of the PCG, IFG, MFG, and SMA.

The right IOG has the highest cluster size, followed by the left PCG, left IOG, left MOG, and the right opercular of the IFG. According to De Carli et al. ([2007](#)), the occipital lobe is the visual processing section of the brain. It is linked to visuospatial processing, the perception of distance and depth, colour determination, object and face identification, and memory formation. In this study, participants were required to actively look at a series of images via a small head coil mirror whilst performing the Malay sentence-to-picture naming task in the MRI. This may explain the high cluster size found in the IOG region. Although the IOG obtained the highest activation, it is important to acknowledge its contribution to task performance and is independent of language processing.

The IFG is known to process speech, and its opercular component, also known as the pars opercularis, is the area of the frontal lobe that overlies the insular cortex and is related to phonological assembly, lexical retrieval, and verbal working memory ([Walenski et al., 2019](#)). The left IFG and PCG incorporate information about the sounds in words and the sequencing of these sounds ([Binding et al., 2022](#)). Speech planning and verbal and nonverbal semantics are connected to MFG. Studies on language function have found that the cerebellum controls verbal fluency (both semantic and formal), expressive and receptive grammar processing, recognising and fixing grammatical errors, and writing abilities.

The ITG region (BA 20) was also activated in this study, reflecting its important role in recognising and interpreting visual stimuli ([Langner et al., 2018](#)). A meta-analysis by Binder et al. ([2009](#)) reported similar semantic studies to obtain activation in the ITG region, suggesting the ITG's involvement in the early stages of the lexical-semantic stream. In the context of sentence comprehension, the ITG is engaged when the participants are processing the visual recognition of the words and letters displayed on the screen. This information is then known to be relayed to other

language-processing regions of the brain (e.g. MTG, Wernicke and Broca's area, AG) for further processing.

In several previous language studies, the premotor cortex was often active in both phonological and semantic tasks, showing activation in motor regions. During the SC task, the left PCG, bilateral post-CG, and bilateral SMA were all activated. The activation of the left motor region may be due to hand movement since the participants in our paradigms performed the tasks by pressing the probe buttons. According to De Carli et al. (2007), SMA is specialised in language processing linked to phonological and articulatory encoding processes. In contrast, the PCG, which governs voluntary motor movements, is engaged in speech production. In contrast, the parietal lobe and post-CG are significant components of the somatosensory cortex and have been linked to language perception. Furthermore, the SPG is part of the parietal lobe association cortex and is involved in planned movements, spatial reasoning, and attention.

Significant evidence supports the involvement of Wernicke's area in the SC tasks. As previously stated, only the AG in Wernicke's area group was activated. AG is notably involved in reading and transitioning between written and spoken language. This region was also linked to the ability to comprehend metaphors (Agarwal et al., 2019). Wernicke's region is well established to play a role in language comprehension and production (Buchweitz et al., 2009). However, damage to Wernicke's region of the brain does not always result in language comprehension issues (Richards & Berninger, 2013). Based on such evidence, it is apparent that language involves a broad range of brain regions, not just one or two. Instead, Wernicke's area appears part of the broad brain network responsible for language production and comprehension.

Correlated fluctuations in spontaneous brain activity, as measured by BOLD fMRI signals, reveal which regions are physiologically linked, either directly or indirectly, via polysynaptic linkages. Cortical ROI analysis findings and computed whole-brain maps for each ROI can be utilized to investigate the language comprehension network. As previously indicated, we focused on the MFG and IFG with the acquired behavioural data for ROI analysis. The MFG and IFG are part of the prefrontal cortex and have been linked to higher brain processes, such as decision-making, problem-solving, planning, organization, motivation, discipline, and emotional control.

Brocas' area encompasses the IFG's pars opercularis and pars triangularis, which are generally responsible for expressive motor speech and involve verbal fluency, phonological processing, grammar processing, and attention during speech. Although Broca's area is primarily associated with language production, it also plays a significant role in language comprehension. Studies have shown that it is especially important to provide the ability to use syntactic information to determine the meanings of complex and ambiguous sentences.

Correlation analyses using Pearson correlation between mean accuracy scores in the SC task with the number of voxels among HCA participants concentrated on the right MFG and left opercular IFG region revealed that the correlation between MFG and accuracy score was not significant. This may be due to the small sample size. While there is consensus that semantic processing declines with age, it is an open question whether syntactic processing shows similar declines. In this study, the behavioural analysis revealed a significant age-related decline in semantic and syntactic processing, as indicated by the low accuracy during the SC tasks. The age-related decline in semantic processing observed in the present study is consistent with the findings of previous studies (Lee et al., 2022).

Previous studies mainly found an age-related decline in comprehension of complex sentences, and the present results suggest that there is also a decline in neural efficiency, seen in errors during syntactic processing of simple structures of Malay sentences. Normal ageing leads to slower and less accurate picture naming and increases in "tip of the tongue states" (TOTs), where the meaning of a word is available, but the form is frustrated out of reach (Binder, 2017). Typical ageing is associated with widespread grey and white matter brain changes, which show considerable regional variation across the brain in timing and rate of decline. Older adults with relatively preserved performance in cognitive domains that typically decline with age show increases in neural activity, particularly in prefrontal regions. This recruitment often involves bilateral activation in conditions where younger adults only activate the right hemisphere. This suggests functional reorganization, wherein recruited left-hemisphere regions take on right-hemisphere processing functions (Diaz et al., 2014).

The strengths and limitations of this study should be acknowledged. The Malay sentence-to-picture naming task administration is a novelty in identifying the neural

networks of sentence comprehension among the Malaysian population. The main limitation of this study is the low sample size. Therefore, our findings may be deemed insufficient to draw conclusions and are considered preliminary. Although the findings may be valid for a specific study population, they are insufficient to generalize our conclusions to the overall population. To improve the representation of the Malaysian population in future research, increasing the number of participants will be essential.

While involving the ageing population in task-based studies is beneficial for understanding their cognitive and physical health, visual limitations were a significant concern. According to Brosseau & Cohen (1996), older adults are generally categorized into three sub-groups: young-old (65-74 years), middle-old (75-84 years), and old-old (85 years and older). Many potential participants reported cataracts, near-sightedness, far-sightedness, or inability to wear contact lenses. Additionally, current participants might have errors in their performance scores due to undiagnosed visual impairments rather than lower comprehension abilities. Although all participants were asked about their vision during screening, more rigorous visual acuity assessments are necessary. Future studies should take these limitations into account.

5.0 CONCLUSIONS

In the present study, we investigated the effect of functional magnetic resonance imaging (fMRI) on localizing critical areas involved in language function, specifically SC tasks in HCA. Significant activations were found, and the sensitivity and specificity of fMRI were exceptionally constant among subjects. In responding to

SC tasks, the left and right IOG and MOG, right IFG and MFG, and right parietal gyrus comprised the SPG and AG. In addition, other non-primary motor areas were consistently active throughout the SC tasks, implying a specific role for motor regions (especially the SMA), including the right and the left postcentral gyri and the left precentral gyrus in language processing. We also discovered no significant relationship between the engaged areas, particularly the MFG and IFG, and behavioural data (accuracy score).

Despite the limited sample size, the current study provides insight into the brain areas engaged in SC tasks. However, more participants, including individuals over 65, should be included in future studies to examine the relationship between active regions and behavioural data. This study provides useful information for neuropsychologists, researchers, and clinical workers involved in providing treatment plans for Malaysian ageing adults to detect early biomarkers for neurodegenerative diseases (e.g., Alzheimer's, and mild cognitive impairment).

Acknowledgements:

The study was supported by the FRGS Grant Scheme (grant code: FRGS/1/2021/SKK06/UKM/02/8).

Author Contributions:

AS, MM and EFNMA performed the experiments, analyzed the data, and wrote the paper; LYY, NS and MSMS contributed to MRI use and assistance; NRM, RAR, MAAA and MMS contributed research materials and reviewed the manuscript. All authors reviewed the manuscript.

Conflicts of Interest:

The authors declared no conflict of interest.

REFERENCES

- Agarwal, S., Sair, H. I., Gujar, S., & Pillai, J. J. (2019). Language mapping with FMRI. *Topics in Magnetic Resonance Imaging*, 28(4), 225–233. <https://doi.org/10.1097/rmr.000000000000216>
- Aziz, M. a. A., Hassan, M., Razak, R. A., & Garraffa, M. (2020). Syntactic abilities in Malay adult speakers with aphasia: a study on passive sentences and argument structures. *Aphasiology*, 34(7), 886–904. <https://doi.org/10.1080/02687038.2020.1742283>
- Azmi, M. N. L., Ching, L. T. P., Jamaludin, N. B., Ramli, M. N. H. B., Razali, M. H. B., Amram, M. a. Y. B., & Jayakumar, K. A. (2016). The comparisons and contrasts between english and malay languages. *English Review Journal of English Education*, 4(2), 209. <https://doi.org/10.25134/erjee.v4i2.335>
- Batouli, S. a. H., & Sisakhti, M. (2020). Some points to consider in a task-based FMRI study: a guideline for beginners. *Frontiers in Biomedical Technologies*, 7(1), 2725. <https://doi.org/10.18502/fbt.v7i1.2725>
- Binder, J. R. (2017). Current controversies on Wernicke's area and its role in language. *Current Neurology and Neuroscience Reports*, 17(8), 1–10. <https://doi.org/10.1007/s11910-017-0764-8>
- Binder, J. R., Desai, R. H., Graves, W. W., & Conant, L. L. (2009). Where is the semantic system? a critical review and meta-analysis of 120 functional neuroimaging studies. *Cerebral Cortex*, 19(12), 2767–2796. <https://doi.org/10.1093/cercor/bhp055>
- Binding, L. P., Dasgupta, D., Giampiccolo, D., Duncan, J. S., & Vos, S. B. (2022). Structure and function of language networks in temporal lobe epilepsy. *Epilepsia*, 63(5), 1025–1040. <https://doi.org/10.1111/epi.17204>

- Blaiotta, C., Freund, P., Cardoso, M. J., & Ashburner, J. (2017). Generative diffeomorphic modelling of large MRI data sets for probabilistic template construction. *NeuroImage*, *166*, 117–134. <https://doi.org/10.1016/j.neuroimage.2017.10.060>
- Brosseau, J., & Cohen, H. (1996). The representation of semantic categories in aging. *Experimental Aging Research*, *22*(4), 381–391. <https://doi.org/10.1080/03610739608254018>
- Buchweitz, A., Mason, R. A., Tomitch, L. M. B., & Just, M. A. (2009). Brain activation for reading and listening comprehension: An fMRI study of modality effects and individual differences in language comprehension. *Psychology & Neuroscience*, *2*(2), 111–123. <https://doi.org/10.3922/j.psns.2009.2.003>
- De Carli, D., Garreffa, G., Colonnese, C., Giuliotti, G., Labruna, L., Briselli, E., Ken, S., Macrì, M. A., & Maraviglia, B. (2007). Identification of activated regions during a language task. *Magnetic Resonance Imaging*, *25*(6), 933–938. <https://doi.org/10.1016/j.mri.2007.03.031>
- DeDe, G., & Knilans, J. (2016). Language comprehension in aging. In *John Benjamins Publishing Company eBooks* (pp. 107–133). John Benjamins Publishing Company, Netherland. <https://doi.org/10.1075/z.200.05ded>
- Diaz, M. T., Johnson, M. A., Burke, D. M., & Madden, D. J. (2014). Age-related differences in the neural bases of phonological and semantic processes. *Journal of Cognitive Neuroscience*, *26*(12), 2798–2811. https://doi.org/10.1162/jocn_a.00665
- Fitzhugh, M. C., Braden, B. B., Sabbagh, M. N., Rogalsky, C., & Baxter, L. C. (2019). Age-related atrophy and compensatory neural networks in reading comprehension. *Journal of the International Neuropsychological Society*, *25*(6), 569–582. <https://doi.org/10.1017/s1355617719000274>
- Gavelin, H. M., Dong, C., Minkov, R., Bahar-Fuchs, A., Ellis, K. A., Lautenschlager, N. T., Mellow, M. L., Wade, A. T., Smith, A. E., Finke, C., Krohn, S., & Lampit, A. (2020). Combined physical and cognitive training for older adults with and without cognitive impairment: A systematic review and network meta-analysis of randomized controlled trials. *Ageing Research Reviews*, *66*, 101232. <https://doi.org/10.1016/j.arr.2020.101232>
- Glover, G. H. (2011). Overview of functional magnetic resonance imaging. *Neurosurgery Clinics of North America*, *22*(2), 133–139. <https://doi.org/10.1016/j.nec.2010.11.001>
- Grossman, M., Cooke, A., DeVita, C., Alsop, D., Detre, J., Chen, W., & Gee, J. (2002). Age-related changes in working memory during sentence comprehension: an fMRI study. *NeuroImage*, *15*(2), 302–317. <https://doi.org/10.1006/nimg.2001.0971>
- How, S. Y., Chan, S. H., & Abdullah, A. N. (2015). Language vitality of Malaysian languages and its relation to identity. *GEMA Online Journal of Language Studies*, *15*(2), 119–139. <https://doi.org/10.17576/gema-2015-1502-08>
- Hussin, N. M., Shahar, S., Yahya, H. M., Din, N. C., Singh, D. K. A., & Omar, M. A. (2019). Incidence and predictors of mild cognitive impairment (MCI) within a multi-ethnic Asian populace: a community-based longitudinal study. *BMC Public Health*, *19*(1), 1–11. <https://doi.org/10.1186/s12889-019-7508-4>
- Institute for Public Health. (2019). National health and morbidity survey 2018 (NHMS 2018): elderly health. *Methodology and General Findings*, *1*, 132. <https://iku.moh.gov.my/images/IKU/Document/REPORT/NHMS2018/NHMS2018ElderlyHealthVolume1.pdf>
- Kadar, M., Ibrahim, S., Razaob, N. A., Chai, S. C., & Harun, D. (2018). Validity and reliability of a Malay version of the Lawton instrumental activities of daily living scale among the Malay speaking elderly in Malaysia. *Australian Occupational Therapy Journal*, *65*(1), 63–68. <https://doi.org/10.1111/1440-1630.12441>
- Lai, W., Hon, Y., Pang, G. M., Chong, E. M., Nordin, N., Tiong, L., Tan, S. H., Sapian, R. A., Lee, Y., & Rosli, N. (2022). Dementia of the ageing population in Malaysia: a scoping review of published research. *Ageing and Health Research*, *2*(2), 100077. <https://doi.org/10.1016/j.ahr.2022.100077>
- Langner, R., Eickhoff, S. B., & Bilalić, M. (2018). A network view on brain regions involved in experts' object and pattern recognition: Implications for the neural mechanisms of skilled visual perception. *Brain and Cognition*, *131*, 74–86. <https://doi.org/10.1016/j.bandc.2018.09.007>
- Laumann, T. O., Snyder, A. Z., Mitra, A., Gordon, E. M., Gratton, C., Adeyemo, B., Gilmore, A. W., Nelson, S. M., Berg, J. J., Greene, D. J., McCarthy, J. E., Tagliazucchi, E., Laufs, H., Schlaggar, B. L., Dosenbach, N. U. F., & Petersen, S. E. (2017). On the stability of BOLD fMRI correlations. *Cerebral Cortex*, *27*(10), 4719–4732. <https://doi.org/10.1093/cercor/bhw265>
- Lawton, M. P., & Brody, E. M. (1969). Assessment of older people: self-maintaining and instrumental activities of daily living. *The Gerontologist*, *9*(3 Part 1), 179–186. https://doi.org/10.1093/geront/9.3_part_1.179
- Lee, Y. S., Rogers, C. S., Grossman, M., Wingfield, A., & Peelle, J. E. (2022). Hemispheric dissociations in regions supporting auditory sentence comprehension in older adults. *Ageing Brain*, *2*, 100051. <https://doi.org/10.1016/j.nbas.2022.100051>
- Manning, C. A., & Ducharme, J. K. (2010). Dementia syndromes in the older adult. In *Handbook of Assessment in Clinical Gerontology* (pp. 155–178). Academic Press, United States. <https://doi.org/10.1016/b978-0-12-374961-1.10006-5>
- Mat Awal, N., Abu Bakar, K., Abdul Hamid, N. Z., & Jalaluddin, N. H. (2007). Morphological differences between Bahasa Melayu and English: constraints in students' understanding. In *The Second Biennial International Conference on Teaching and Learning of English in Asia : Exploring New Frontiers (TELiA2)*, 14-16 June 2007, Holiday Villa Beach & Spa Resort, Langkawi (pp. 1 – 11). Perpustakaan Sultanah Bahiyah, Universiti Utara Malaysia, Malaysia. <https://repo.uum.edu.my/id/eprint/3264>

- Nasiri, M., Moayedfar, S., Purmohammad, M., & Ghasisin, L. (2022). Investigating sentence processing and working memory in patients with mild Alzheimer and elderly people. *PLoS ONE*, *17*(11), e0266552. <https://doi.org/10.1371/journal.pone.0266552>
- Park, D. C., & Reuter-Lorenz, P. (2009). The adaptive brain: aging and neurocognitive scaffolding. *Annual Review of Psychology*, *60*(1), 173–196. <https://doi.org/10.1146/annurev.psych.59.103006.093656>
- Parker, D., Liu, X., & Razlighi, Q. R. (2017). Optimal slice timing correction and its interaction with fMRI parameters and artifacts. *Medical Image Analysis*, *35*, 434–445. <https://doi.org/10.1016/j.media.2016.08.006>
- Peelle, J. E., Troiani, V., Wingfield, A., & Grossman, M. (2010). Neural processing during older adults' comprehension of spoken sentences: age differences in resource allocation and connectivity. *Cerebral Cortex*, *20*(4), 773–782. <https://doi.org/10.1093/cercor/bhp142>
- Pistono, A., Senoussi, M., Guerrier, L., Rafiq, M., Giméno, M., Péran, P., Jucla, M., & Pariente, J. (2021). Language network connectivity increases in early Alzheimer's disease. *Journal of Alzheimer's Disease*, *82*(1), 447–460. <https://doi.org/10.3233/jad-201584>
- Psychology Software Tools. (2016). E-Prime 3.0 [Computer software]. Psychology Software Tools. <https://www.pstnet.com>
- Richards, T. L., & Berninger, V. W. (2013). Brain mapping of language processing using functional MRI connectivity and diffusion tensor imaging. In *Functional Brain Mapping and the Endeavor to Understand the Working Brain*. IntechOpen, Croatia. <https://doi.org/10.5772/56501>
- Rusli, Y. A., & Montgomery, J. (2020). Sentence comprehension and working memory in Malay adults. *GEMA Online Journal of Language Studies*, *20*(1), 16–34. <https://doi.org/10.17576/gema-2020-2001-02>
- Segkouli, S., Paliokas, I., Tzovaras, D., Lazarou, I., Karagiannidis, C., Vlachos, F., & Tsolaki, M. (2017). A computerized test for the assessment of mild cognitive impairment subtypes in sentence processing. *Aging Neuropsychology and Cognition*, *25*(6), 829–851. <https://doi.org/10.1080/13825585.2017.1377679>
- Taler, V., & Phillips, N. A. (2008). Language performance in Alzheimer's disease and mild cognitive impairment: A comparative review. *Journal of Clinical and Experimental Neuropsychology*, *30*(5), 501–556. <https://doi.org/10.1080/13803390701550128>
- Walenski, M., Europa, E., Caplan, D., & Thompson, C. K. (2019). Neural networks for sentence comprehension and production: An ALE-based meta-analysis of neuroimaging studies. *Human Brain Mapping*, *40*(8), 2275–2304. <https://doi.org/10.1002/hbm.24523>
- Yap, N. T., Razak, R. A., Haman, E., Łuniewska, M., & Treffers-Daller, J. (2017). Construction of the Malay cross-linguistic lexical task: a preliminary report. *Language Studies Working Papers*, *8*, 47–61. <https://centaur.reading.ac.uk/70928/>
- Zafar, R., Malik, A. S., Kamel, N., & Dass, S. C. (2015). Importance of realignment parameters in fMRI data analysis. In *2015 IEEE International Conference on Signal and Image Processing Applications (ICSIPA)* (pp. 546-550). Institute of Electrical and Electronics Engineers, United States. <https://doi.org/10.1109/ICSIPA.2015.7412251>