



**EDITORIAL**

- 4 **Joining the Call to End Nuclear Weapons, Before They End Us**  
Lapeña JFF

**GUEST EDITORIAL**

- 6 **Ending Nuclear Weapons, Before They End Us**  
Abbasi K, Ali P, Barbour V, Birch M, Blum I, Doherty P, Haines A, Helfand I, Horton R, Juva K, Lapeña JF Jr, Mash R, Mironova O, Mitra A, Monteiro C, Naumova EN, Onazi D, Ruff T, Sahni P, Tumwine J, Umaña C, Yonga P, Zielinski C

**ORIGINAL ARTICLES**

- 9 **Hearing Loss in High-Risk Newborns: The Effectiveness of One-stage Hearing Screening in the Neonatal Intensive Care Unit of the Jose R. Reyes Memorial Medical Center**  
Zambales CJG, Reala ET
- 15 **Radiologic CT Scan Assessment of Eustachian Tube Dimensions in a Sample of Filipino Adults with Chronic Otitis Media at the Rizal Medical Center: A Retrospective Study**  
Real GJV, Artates AMV, Lapiña GF, Grullo PER
- 20 **Association of Demographic Profiles and Clinical Characteristics of Patients with Aural Foreign Bodies at the Emergency Room of the East Avenue Medical Center with Clinical Outcomes: A Cross-Sectional Study**  
Sustino FD, Almazan MNA
- 26 **Diagnostic Accuracy of STOP-BANG Score in Detecting Obstructive Sleep Apnea Among Patients at the Rizal Medical Center**  
Nano ADM, Sarte MAA, Ambrocio GMC, Grullo PER
- 30 **Simulation in Transcutaneous Injection Laryngoplasty Using a 3D-printed Laryngeal Injection Task Trainer (LITT)**  
Tan DI, Dela Cruz APC, Aljibe MSO, Carrillo RJD, Fullante PB
- 37 **Low-Cost Phantom Model for Simulation Training in Ultrasound-Guided Ethanol Ablation of a Cystic Thyroid Nodule**  
Duguil DYS, Rojas RS, Capuz MKA
- 42 **Safety Outcome of Yap Technique in Structural Rhinoplasty with PCL Mesh as Unilateral Extended Spreader Graft and End-to-End Septal Extension Graft: A Four-Year Single Surgeon Experience**  
Sy JC, Rojo-Tan JG, Alfanta EM, Yap EC

**CASE REPORTS**

- 47 **No Burp Syndrome or Retrograde Cricopharyngeal Dysfunction in a Filipina College Student: A Case Report**  
Gaticales CAS, Velasquez RF, Fortuna MCS
- 51 **Excision of a Large Lingual Thyroglossal Duct Cyst via Median Labiomandibular Glossectomy (Trotter Procedure) and Hyoid Osteotomy: A Case Report**  
Suñer MAKD, Que-Ansorge C, Cruz ETS, Samson ES

**SURGICAL INNOVATIONS AND INSTRUMENTATION**

- 55 **3D Printed Human Laryngeal Model: A Tool for Laryngeal Framework Surgery Training**  
Bautista MAS, Espina JB

**FEATURED GRAND ROUNDS**

- 60 **Fibrous Dysplasia of the Temporal Bone Presenting with Chronic Suppurative Otitis Media**  
Alvarez AD, Uy DC

**FROM THE VIEWBOX**

- 64 **Post-Operative Features of a Symptom-Free Canal-Wall Down Mastoidectomy**  
Yang NW

**UNDER THE MICROSCOPE**

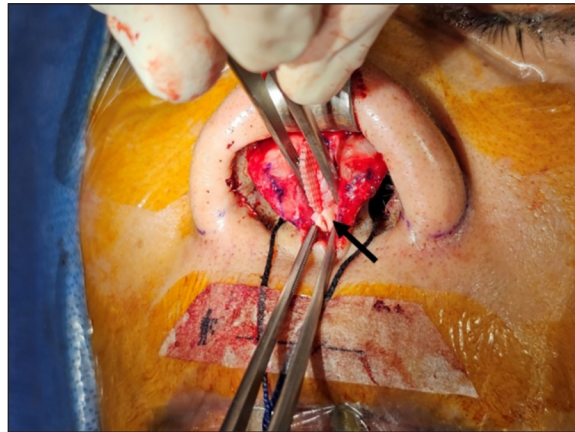- 66 **Mesenchymal Chondrosarcoma of the Maxillary Alveolar Bone in a 6-Year-Old Girl**  
Curso KAJO, Mirhan CVL, Yturralde EMH, Carnate JM

**PASSAGES**

- 69 **Remigio I. Jarin, MD (1934 - 2024)**  
Jarin PSL
- 70 **Theodore M. Carvajal, MD (1976 - 2025)**  
Lunaria FE
- 71 **Joy P. Ambos, MD (1972 - 2025)**  
Dumanon DRA

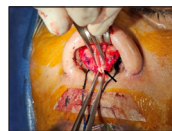**CAPTOONS**

- 72 **DokNet's World**  
Billones WU

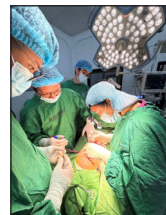

- Joining the Call to End Nuclear Weapons, Before They End Us
- Ending Nuclear Weapons, Before They End Us
- Hearing Loss in High-Risk Newborns: The Effectiveness of One-stage Hearing Screening in the Neonatal Intensive Care Unit of the Jose R. Reyes Memorial Medical Center
- Radiologic CT Scan Assessment of Eustachian Tube Dimensions in a Sample of Filipino Adults with Chronic Otitis Media at the Rizal Medical Center: A Retrospective Study
- Association of Demographic Profiles and Clinical Characteristics of Patients with Aural Foreign Bodies at the Emergency Room of the East Avenue Medical Center with Clinical Outcomes: A Cross-Sectional Study
- Diagnostic Accuracy of STOP-BANG Score in Detecting Obstructive Sleep Apnea Among Patients at the Rizal Medical Center
- Simulation in Transcutaneous Injection Laryngoplasty Using a 3D-printed Laryngeal Injection Task Trainer (LITT)
- Low-Cost Phantom Model for Simulation Training in Ultrasound-Guided Ethanol Ablation of a Cystic Thyroid Nodule
- Safety Outcome of Yap Technique in Structural Rhinoplasty with PCL Mesh as Unilateral Extended Spreader Graft and End-to-End Septal Extension Graft: A Four-Year Single Surgeon Experience
- No Burp Syndrome or Retrograde Cricopharyngeal Dysfunction in a Filipina College Student: A Case Report
- Excision of a Large Lingual Thyroglossal Duct Cyst via Median Labiomandibular Glossectomy (Trotter Procedure) and Hyoid Osteotomy: A Case Report
- 3D Printed Human Laryngeal Model: A Tool for Laryngeal Framework Surgery Training
- Fibrous Dysplasia of the Temporal Bone Presenting with Chronic Suppurative Otitis Media
- Post-Operative Features of a Symptom-Free Canal-Wall Down Mastoidectomy
- Mesenchymal Chondrosarcoma of the Maxillary Alveolar Bone in a 6-Year-Old Girl  
Remigio I. Jarin, MD (1934 - 2024)  
Theodore M. Carvajal, MD (1976 - 2025)  
Joy P. Ambos, MD (1972 - 2025)  
DokNet's World

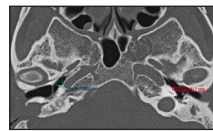
**COVER IMAGES**



"Open structured rhinoplasty using PCL mesh as septal extension graft and then covered with septal and conchal cartilages"  
Samsung Galaxy S23 Ultra  
By Eduardo C. Yap, MD




"Passing on the scalpel: A mentor's wisdom shapes the next generation of surgeons"  
iPhone 16 Pro Max  
By Frederick Mars B. Untalan, MD



"Temporal Bone CT scan in Axial view measuring the Eustachian tube dimension in Pre tympanic diameter"  
CT Scan image  
By Gladys Jan V. Real, MD



"The Slate of the Twin Lakes"  
Samsung Galaxy S23  
By Jefferson A. Alamani, MD



"Starless Sky"  
6"x9" Oil on Canvas  
By Karen June P. Dumlaog, MD