

Benedick B. Borbe, MD
Ferdinand G. Pamintuan, MD

Department of Otorhinolaryngology
Head and Neck Surgery
Jose B. Lingad Memorial General Hospital

Correspondence: Dr. Benedick B. Borbe
Department of Otorhinolaryngology
Head and Neck Surgery
Jose B. Lingad Memorial General Hospital
Dolores, San Fernando, Pampanga 2000
Philippines
Phone: +63 45 409 6688 local 144
Email: bbborbe@yahoo.com

The authors declared that this represents an original material, which has not been submitted, published, nor considered for publication elsewhere, in full or in part, in print or electronic media. It has been read and approved by all the authors, and the requirements for authorship have been met, and each believes that the manuscript represents honest work.

Disclosures: The authors signed disclosures that there were no financial or other relationships, intellectual passion, political or religious beliefs, and institutional affiliations that might have led to a conflict of interest in this study.

Presented at the quarterly meeting of the Philippine Academy of Craniomaxillofacial Surgery, Quezon City, July 9, 2025.

Data Availability and Sharing Statement: Datasets for the study are publicly available in the data repository listed: Zenodo [<https://zenodo.org/>] with DOI: 10.5281/zenodo.15875950.



Creative Commons (CC BY-NC-ND 4.0)
Attribution - NonCommercial - NoDerivatives 4.0 International

Anthropometric Analysis of the Anterior Maxillary Fixation Points – A Step in Optimizing L-plates for Zygomaticomaxillary Fractures

ABSTRACT

Objective: To determine and group the anthropometric norms of the zygomaticomaxillary (ZM) fixation points as a basis for optimizing the design of maxillary L-plates, from a sample population aged 19 to 59, in a tertiary government hospital in Central Luzon, Philippines.

Methods:

Design: Retrospective Review of CT scans

Setting: Tertiary Government Training Hospital

Participants: CT scan images of 110 surgical patients from the Department of ORL-HNS, obtained between January 2023 and December 2024 were measured

Results: A total of 169 maxillae were analyzed, comprising 85 right and 84 left sides. The maxillary width (MW) of males (30.59 ± 2.86 mm) was found to be wider than the MW of females (29.68 ± 2.69 mm) by 0.91 mm. The zygomatic width (ZW) and its inclination angle (IA), on the other hand, were not significantly different. There were also no significant differences in the MW, ZW, and IA between the right and left sides; with the MW mean at 30.17 ± 2.81 mm and a range of 24.40–36.80 mm, the ZW mean at 20.22 ± 2.47 mm and a range of 15.40–28.30 mm, and the IA mean at 111.13 ± 11.29 degrees and a range of 78.50–131.70 degrees. To capture the range of maxillary sizes among patients, a quartile-based grouping was introduced. The MW, ZW, and IA of the L-plates were classified into small (27.80 mm, 18.30 mm, 104.15 degrees), medium (29.80 mm, 19.90 mm, 110.70 degrees), and large (32.35 mm, 22.05 mm, 120.20 degrees) sizes, respectively.

Conclusion: This study established reference values for the MW, ZW and IA to optimize the maxillary L-plate design for ZM fractures. The novel quartile-based grouping provided options for future L-plate measurements – potentially creating a better fit for patients, streamlining design in implant production, and improving the efficiency and outcomes of maxillofacial surgeons.

Keywords: maxillary fractures; zygomaticomaxillary buttress; tomography, spiral computed; titanium; fracture fixation, internal



The midface, specifically the zygomaticomaxillary (ZM) area, is one of the most commonly fractured sites of the facial skeleton – in the Philippines, it is involved in 37% of ballistic and 56% of motorcycle-related injuries.^{1,2} Open reduction through a vestibular approach followed by internal fixation with titanium implants remain the standard surgical treatment.³ However, when multiple midfacial bones are involved, reconstitution of the facial structure and function can be particularly challenging.⁴ Conventional titanium L-plates have limited screw holes. They are thin and not ideal for comminuted fractures, prone to stress after repeated bending, side-specific, hence, less adaptable, and mostly sourced from non-Asian countries.⁵ These make them less ideal especially for cases that require fixation along the primary load-bearing facial buttress.

To the best of our knowledge, based on a search of HERDIN Plus, the Western Pacific Region Index Medicus (WPRIM), the Directory of Open Access Journals (DOAJ), MEDLINE (PubMed and PubMed Central), and Google Scholar using the search terms “maxillary fracture,” “zygomaticomaxillary buttress,” “computed tomography,” “titanium implant,” and “internal fixation,” no local research to refine this implant has been published to date.

This paper aims to determine and group the anthropometric norms of the ZM fixation points, specifically its lengths and angle at the ZM buttress, based on a sample of patients aged 19 to 59 in a tertiary government hospital in Central Luzon, Philippines. This may serve as an initial phase in optimizing the design of maxillary L-plates, and tailoring them for adult patients with ZM fractures.

METHODS

With approval of the Research and Ethics Committee of the Jose B. Lingad Memorial General Hospital (REC Protocol 2024-36A), this retrospective study analyzed plain cranial, facial, paranasal, and temporal bone Computed Tomography (CT) scans performed within the institution between January 2023 and December 2024, for surgical patients of the Department of ORL-HNS aged 19 to 59 years old. Excluded were CT scans that did not show the entirety of the maxilla, those with missing or carious canines and molars, and those with pathologies that distorted the normal maxillary bone anatomy (i.e. tumors, fractures, congenital malformations, previous surgeries, etc.).

The CT scans of patients were obtained using InCise CT (64 Slice, Philips, Netherlands) at ≤ 1 millimeter cuts. Digital Imaging and Communications in Medicine (DICOM) files were reviewed on desktop computers at the Department of Radiology that satisfied the display requirements for clinical review work,⁶ using the full version of either RadiAnt DICOM Viewer (Version 2024.1, Medixant, Poland) or Synapse DICOM Viewer (Version 7.4.100, Fujifilm Healthcare Americas

Corporation, USA) Picture Archiving and Communication System (PACS), because there was a hospital transition from RadiAnt to Synapse toward the end of 2024. The principal investigator, with the on-duty radiology consultant, conducted the measurements. For patient confidentiality, no DICOM file was exported, only the age and sex were collected, and only the principal investigator had access to the compiled database.

The DICOM images were viewed in bone window setting, and placed in the neutral anatomic position to correct asymmetries, by rotating the axes on multiplanar views. (Figure 1) The following measurement points for each of the right and left maxillae were recorded, following the method of Wang *et al.*:⁵

- The maxillary width (MW) was defined by the distance along the surface landmarks of the canine root to the 1st maxillary molar root, as seen on axial plane. (Figure 2)
- The zygomatic width (ZW) was defined by the distance along the surface landmarks of the 1st maxillary molar root to the inferior border of the zygomaticomaxillary crest,⁷ as seen on coronal plane. (Figure 3)
- The zygomatic bone inclination angle (IA) was defined by the degrees of the MW line and ZW line, as they intersect on the surface landmark of the 1st maxillary molar root, as seen on sagittal plane. (Figure 4)

The minimum sample size computed was 110 CT scan studies. This was based on the mean MW of 22 (SD: 2.98 mm) and ZW of 17 (SD: 2.72 mm), from the paper of Wang *et al.*⁵ assuming a 3% margin of error and 95% confidence level. Measurements of the right and left MW, ZW, and IA of both sexes were recorded in a database using 2022 Microsoft® Excel Version 16.67 (Microsoft Corp., Redmond, WA, USA).

The measurements were first tested for normality using Shapiro-Wilk tests, which showed non-normal distribution for all measures (p-values < .05) except for IA (right) and ZW (left). Since the assumption of bivariate normal distribution was not achieved for all ZM fixation points, comparison between the right and left were performed using Mann-Whitney tests (the non-parametric counterpart of the independent T-test). The results of this test showed no significant difference between the right and left sides (p-value > .05); hence, measurements from the two lateralities may be combined. To determine and group the anthropometric norms of the ZM fixation points, with a non-normally distributed data set, quartiles were used to provide three sizes: small, medium and large. For descriptive purposes, the mean, SD, and range (minimum to maximum values) of the ZM fixation points were also presented. Statistical tests were performed using IBM SPSS Statistics Version 25.0 (IBM Corp., Armonk, NY, USA) and StataMP Version 17.0 (StataCorp LLC, Texas, USA).

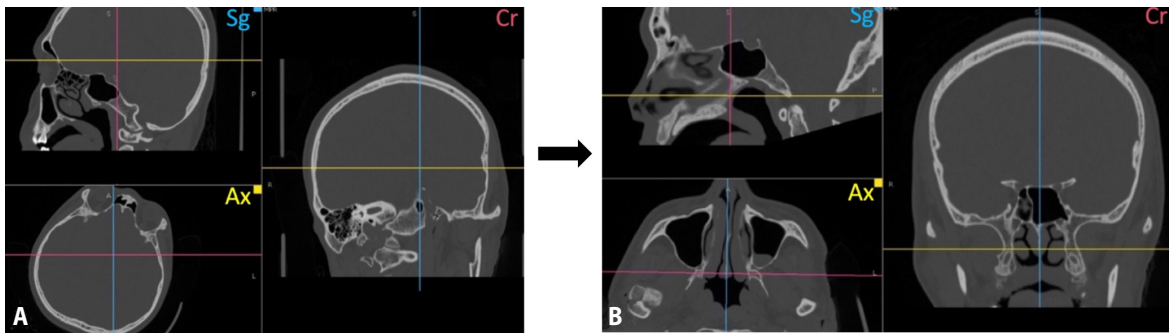


Figure 1. Multiplanar images (bone window) of a patient's plain craniofacial CT scan in Sg (sagittal), Ax, (axial), and Cr (coronal) views showing **A.** asymmetry from initial patient positioning; and **B.** correction of asymmetry and placement of images in the neutral anatomic planes by rotating all three axes in the DICOM viewer program.

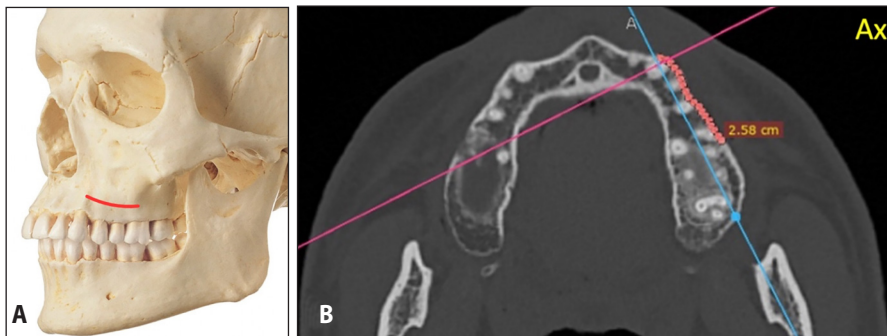


Figure 2. Maxillary Width (MW) **A.** as seen on a skull model (solid line); and **B.** measured along the surface landmarks of the canine root to the 1st maxillary molar root, on axial view of a plain craniofacial CT scan in bone window (dotted line).

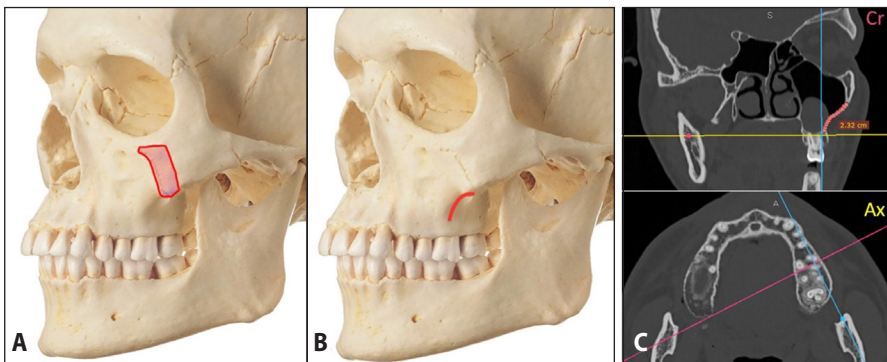


Figure 3. Skull model showing **A.** location of the zygomaticomaxillary crest (solid outline); **B.** Zygomatic Width (ZW) (solid line); and **C.** ZW was measured along the surface landmarks of the 1st maxillary molar root to the inferior border of the zygomaticomaxillary crest, on coronal view of a plain craniofacial CT scan in bone window (dotted line).

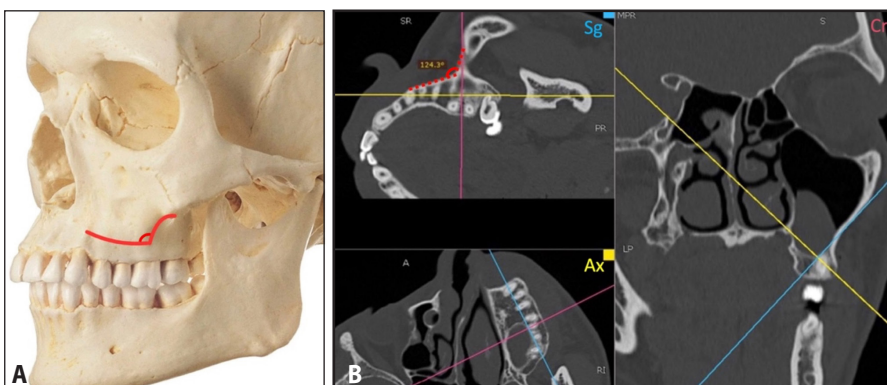



Figure 4. Zygomatic bone inclination angle (IA) of the MW and ZW lines, as seen on a **A.** skull model (solid line); and **B.** measured by the degrees as they intersect on the surface landmark of the 1st maxillary molar root, on sagittal view of a plain craniofacial CT scan in bone window (dotted line).



RESULTS

Out of 1,177 surgical patients from the Department of ORL-HNS between January 2023 and December 2024, 542 CT scan files were reviewed, and exactly 110 satisfied the inclusion and exclusion criteria, comprising 50 females and 60 males. The MW of males (30.59 ± 2.86 mm, 18.30 mm, 104.15°), medium (Q2: 29.80 mm, 19.90 mm, 110.70°), and large (Q3: 32.35 mm, 22.05 mm, 120.20°) sizes were established to reflect anatomical variability among patients. Statistical analysis showed no significant difference between the right and left sides which supports bilateral facial symmetry.

A total of 169 independent maxillae were analyzed, comprising 85 measurements for the right and 84 measurements for the left. Mann-Whitney tests showed no significant difference in the MW ($p = .73$), ZW ($p = .49$), and IA ($p = .90$) between the right and left sides; this demonstrated that both lateralities were comparable in size and could be pooled into a single dataset.

From the combined left and right measurements, quartiles were used (since the combined data were found to be non-normally distributed) to capture the range of maxillary sizes among patients. These quartiles served as the basis to group the L-plates into small (Q1: 27.80 mm, 18.30 mm, 104.15 degrees), medium (Q2: 29.80 mm, 19.90 mm, 110.70 degrees), and large (Q3: 32.35 mm, 22.05 mm, 120.20 degrees) sizes respectively. (Table 1)

Table 1. Values and analysis of the right and left Maxillary Widths (MW), Zygomatic Widths (ZW) and Zygomatic Bone Inclination Angle (IA) of females and males

		FEMALE	MALE	RIGHT	LEFT	COMBINES				
	Subjects	50	60	85	84	110				
	Maxillae	78	91			169				
MW (in mm)	Mean	29.68	30.59	30.09	30.25	30.17				
	SD	2.69	3.86	2.78	2.86	2.81				
	Min	25.50	24.40	25.30	24.40	Min	Q1	Q2	Q3	Max
	Max	35.90	36.80	35.70	36.80	24.40	27.80	29.80	32.35	38.80
	p-value	.036		.730						
ZW (in mm)	Mean	20.06	20.36	20.09	20.35	20.22				
	SD	2.49	2.46	2.57	2.38	2.47				
	Min	15.50	15.40	15.40	15.80	Min	Q1	Q2	Q3	Max
	Max	26.30	28.30	28.30	26.30	15.40	18.30	19.90	22.05	28.30
	p-value	.448		.496						
IA (degrees)	Mean	111.04	111.21	111.02	111.24	111.13				
	SD	10.93	11.65	11.40	11.25	11.29				
	Min	78.50	80.10	78.50	80.10	Min	Q1	Q2	Q3	Max
	Max	131/70	130.00	131.70	130.00	78.50	104.15	110.70	120.20	131.70
	p-value	.927		.900						

MW Maxillary width; ZW Zygomatic width; IA Zygomatic bone inclination angle; Min Minimum measurement obtained; Q1 First quartile (25th percentile); Q2 Second quartile or Median (50th percentile); Q3 Third quartile (75th percentile); Max Maximum measurement obtained

DISCUSSION

This study provided accurate anthropometric measurements of the ZM fixation points, respectively, its MW, ZW, and IA, and categorized them using a quartile-based grouping. The resulting small (Q1: 27.80 mm, 18.30 mm, 104.15°), medium (Q2: 29.80 mm, 19.90 mm, 110.70°), and large (Q3: 32.35 mm, 22.05 mm, 120.20°) sizes were established to reflect anatomical variability among patients. Statistical analysis showed no significant difference between the right and left sides which supports bilateral facial symmetry.

Maxillofacial fractures represent a significant global burden with midfacial fractures accounting for a majority of these injuries.⁸ The anatomic form and functional stability of the midface is governed by facial buttresses with the ZM buttress being its strongest load-bearing structure.⁹ It is involved in zygomatic (15%), maxillary (16.4%), quadripod (10.7%), LeFort I (0.2%) and LeFort II (0.8%) fractures.¹⁰ Given the biomechanical importance of the ZM region, stabilization using L-shaped titanium implants is imperative for a successful surgery.^{9,11}

Our study offers a foundational reference for the optimization of L-plate design which proposes a patient-matched system. Bilateral symmetry of the facial skeleton is largely attributed to embryology, particularly in the midface where paired maxillary prominences fuse to form mirror-image anatomy.¹² The observed symmetry in this study may support the possibility of designing side-neutral (reversible) plates, simplifying implant selection.

Measuring the adult male and female fixation points reflected the known craniofacial dimorphism between the two sexes; also to minimize variability (i.e. ongoing craniofacial growth among children and maxillary-mandibular atrophy in the elderly), only adult patients with intact canines and molars were included.¹³ By focusing on this sample where the skull size and dentoalveolar architecture are already stable, the study ensured consistent and reproducible measurements.

The three dimensions measured determine the surface landmarks where the implant will be fixated – with the MW serving as the L-plate's horizontal leg, the ZW as its vertical leg, and the IA as its angle. The non-normal distribution of the obtained measurements point to the anatomical variability influenced by genetic and environmental factors. Hence, the introduction of a quartile-based grouping of sizes addresses the anatomical range across adult patients. This three-tiered framework provided options for future L-plate measurements that can enhance the match of implants used, decrease operative time and bending attempts, prevent short- and long-term complications, and overall improve the stability for ZM fracture fixation.⁵

While patient-specific implants (PSIs) are already the gold standard for fracture fixation in developed nations, its adoption in the Philippine

healthcare setting remains a challenge. High costs (e.g., equipment, software, infrastructure), limited availability of experts and centers (e.g., entities that are adept in designing and fabricating timely and reliable PSIs consistently), and restricted accessibility through public health systems have been identified as barriers for developing nations.^{14,15} Given these constraints, optimized L-plates offer an alternative for the time being and bridge PSIs and mass production. It can potentially serve as a compromise between individualized care and the financial/logistical challenges that come with it, that is based on local data, streamlined for mass production, and scalable to improve surgical efficiency and outcomes.

There are, however, several limitations to our study. While it suggested valuable anthropometric insights, the setting was only one tertiary government hospital, with patients mostly coming from Pampanga, Bulacan, Tarlac, and a few neighboring provinces of Central Luzon, Philippines. A multi-center study across the Philippines may be done to determine if the derived anthropometric norms in this research are generalizable to the adult Filipino patient. Also, only the lengths and angle of the ZM fixation points were analyzed; further research on factors that can influence implant design may be undertaken,

such as bone density, cortical thickness, and measurements and comparison with existing L-plates in the market. We also did not include a comparative analysis of the derived anthropometric norms with the dimensions of existing L-plates in the market, that may have further underscored the need for optimization and demonstrated the practical advantages of the proposed system. A future study may explore this, as well as evaluate actual experiences of surgeons using these L-plates, and with regard to usual fracture patterns encountered in their practice. This may elucidate how appropriate the L-plates are for Filipino patients. Lastly as a future endeavor, a feasibility study involving finite element analysis (FEA) may be done to assess the biomechanical viability of this proposed L-plate system as a proof of concept.

In conclusion, this study established future reference values for the MW, ZW, and IA to optimize the maxillary L-plate design for ZM fractures. To capture the range of maxillary sizes, a novel quartile-based grouping was introduced. This system provided options for future L-plate measurements – potentially creating better fit for patients, streamlining design in implant production, and improving the efficiency and outcomes of maxillofacial surgeons in resource-challenged settings such as ours.

ACKNOWLEDGEMENTS

We thank the consultants and staff of the Radiology Department, especially Dr. Rina Sapungan and Ms. Merry Ortillo, MSc, for their support during data gathering. We are also grateful to Ms. Madonna Valenzuela, MME, for the assistance and explanation of statistical data. Lastly, we thank Dr. Joman Laxamana; Dr. Erwin Enriquez; Dr. Marc Santiago; Dr. Timothy Manalang, MPH; and Engr. John Dizon, PhD, for providing feedback and invaluable input in pre-reviewing our manuscript.

REFERENCES

- Garimbao JF. Maxillofacial gunshot and blast injuries seen in a tertiary military hospital. *Philipp J Otolaryngol Head Neck Surg.* 2019 Dec 2;34(2):29-31. DOI: 10.32412/pjohns.v34i2.1121.
- de la Cruz RAR, Tuazon RS. Motorcycle-related cranio-maxillofacial injuries at a tertiary hospital in the Philippines. *Philipp J Otolaryngol Head Neck Surg.* 2016 Nov 30;31(2):27-30. DOI: 10.32412/pjohns.v31i2.231.
- Manson PN, Hoopes JE, Su CT. Structural pillars of the facial skeleton: an approach to the management of LeFort fractures. *Plast Reconstr Surg.* 1980 Jul;66(1):54-62. DOI: 10.1097/00006534-198007000-00010; PubMed PMID: 7394047.
- Jacob OA, Prathap A. Maxillary Fractures and Fractures of the Zygomaticomaxillary Complex. In: Bonanthaya K, Panneerselvam E, Manuel S, Kumar VV, Rai A. (Eds.) *Oral and Maxillofacial Surgery for the Clinician.* Singapore: Springer; 2021. p. 1125-1199.
- Wang YT, Chen CH, Wang PF, Lin CL. Development of a novel anatomical thin titanium mesh plate with reduction guidance and fixation function for Asian zygomatic-orbitomaxillary complex fracture. *J Craniomaxillofac Surg.* 2018 Apr;46(4):547-557. DOI: 10.1016/j.jcms.2017.11.009; PubMed PMID: 29422224.
- Radiology Informatics Committee. Picture archiving and communication systems (PACS) and guidelines on diagnostic display devices. 3rd Ed. London: The Royal College of Radiologists; 2019 Feb [cited 2025 May 20]. Available from: https://www.bsir.org/media/resources/bfcr192_pacs-diagnostic-display.pdf.
- Cornelius CP, Audigé L, Kunz C, Buitrago-Téllez CH, Rudderman R, Prein J. The Comprehensive AOCMF Classification System: Midface Fractures - Level 3 Tutorial. *Craniomaxillofac Trauma Reconstr.* 2014 Dec;7(Suppl 1):S068-91. DOI: 10.1055/s-0034-1389561; PubMed PMID: 25489392.
- Zhang ZX, Xie L, Li Z. Global, regional, and national burdens of facial fractures: a systematic analysis of the global burden of Disease 2019. *BMC Oral Health.* 2024 Feb 28;24(1):282. DOI: 10.1186/s12903-024-04048-5; PubMed PMID: 38418992.
- Medeiros YL, Loures AO, Silva BN, Reher P, Devito KL, Carvalho MF. Tomographic analysis of nasomaxillary and zygomaticomaxillary buttress bone thickness for the fixation of miniplates. *Int J Oral Maxillofac Surg.* 2021 Aug;50(8):1034-1039. DOI: 10.1016/j.ijom.2020.11.006; PubMed PMID: 33280988.
- Germar GG, Cruz MY. A four-year study of the demographic distribution and treatment of maxillofacial fractures admitted at the Philippine General Hospital. *Acta Medica Philippina.* 2009;43(3):16-25.
- Pakdel AR, Whyne CM, Fialkov JA. Structural biomechanics of the craniomaxillofacial skeleton under maximal masticatory loading: Inferences and critical analysis based on a validated computational model. *J Plast Reconstr Aesthet Surg.* 2017 Jun;70(6):842-850. DOI: 10.1016/j.bjps.2017.01.021; PubMed PMID: 28291687.
- Bardhan S, Bhargava N, Dighe S, Vats N, Naganathan SR. Emergence of a left-right symmetric body plan in vertebrate embryos. *Curr Top Dev Biol.* 2024;159:310-342. DOI: 10.1016/bs.ctdb.2024.01.003; PubMed PMID: 38729680.
- Moldez MA, Sato K, Sugawara J, Mitani H. Linear and angular Filipino cephalometric norms according to age and sex. *Angle Orthod.* 2006 Sep;76(5):800-5. DOI: 10.1043/0003-3219(2006)076[0800:LAAFCN]2.0.CO;2; PubMed PMID: 17029513.
- Shahrubudin N, Koshy P, Alipal J, Kadir MHA, Lee TC. Challenges of 3D printing technology for manufacturing biomedical products: A case study of Malaysian manufacturing firms. *Heliyon.* 2020 Apr 12;6(4):e03734. DOI: 10.1016/j.heliyon.2020.e03734. PubMed PMID: 32322726.
- Philippine Council for Health Research and Development: 3D-printed polyetheretherketone (PEEK) osteosynthesis plates for simple mandibular fractures [Internet]. Manila: PCHRD; [cited 2025 Jul 9]. Available from: <https://www.pchrd.dost.gov.ph/heartnovation/3d-printed-polyetheretherketone-peek-osteosynthesis-plates-for-simple-mandibular-fractures>.