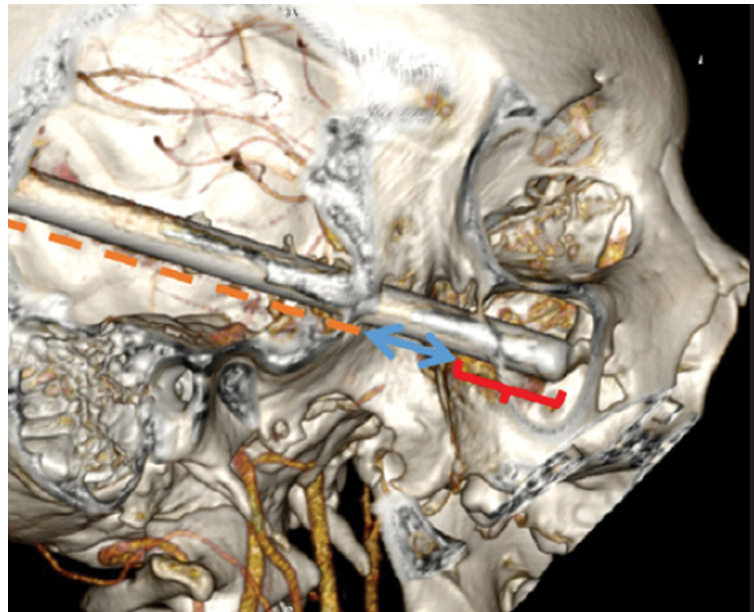


**EDITORIAL**

- 3 **Bridging the Publication Gap: A Special Supplemental Issue of Case Reports**  
Soriano-Castañeda SR, Chua AH

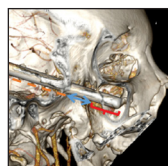**CASE REPORTS**

- 4 **Coexisting Parotid Cholesteatoma and Temporal Bone Carcinoma: A Case Report**  
de Castro DJC, Laganao CRD
- 9 **Langerhans Cell Histiocytosis Presenting as a Complicated Case of Otitis Media in a One-Year-Old Girl: A Case Report**  
Yap KBA, Monroy AA
- 13 **Mucosa-Associated Lymphoid Tissue (MALT) Lymphoma of the Nasopharynx in a 21-Year-Old Woman: A Case Report**  
Tagata MKC
- 17 **A Case of Penetrating Craniomaxillofacial Injury in the Time of COVID-19**  
Baccay OGM, Santos-Perez JM, Amable JPM
- 21 **Concurrent Late Post-Tonsillectomy Hemorrhage and Dengue Fever in a 17-Year-Old Girl: A Case Report**  
Tan JGR, Ramos RZH
- 24 **Multiple Odontogenic Keratocysts as Initial Manifestation of Gorlin-Goltz Syndrome: A Case Report**  
Gernale-Songahid GBL, Acuin MA, Uy-Chua JL
- 29 **A Case of a Migrating Foreign Body in the Esophagus of a 65-Year-Old Woman**  
Ramos MLQ, Samson ES
- 33 **Thyroid Tuberculosis with Papillary Thyroid Carcinoma in a 19-Year-Old Woman: A Case Report**  
Banawol JL, Soriano RG
- 36 **Triple Primary Malignancy (Synchronous Papillary and Follicular Thyroid Carcinomas and Diffuse B-Cell Lymphoma of the Submandibular Gland and Cervical Lymph Nodes) in a 70-Year-Old Woman**  
Roxas ARJPM
- 41 **Giant Pleomorphic Adenoma in a 64-Year-Old Woman: A Case Report**  
Barrios MLB, Peñaflor NAI
- 45 **The Supraclavicular Artery Island Flap: A Practical Approach for Reconstruction of Extensive Cervicofacial Defects Following Giant Cavernous Hemangioma Resection**  
Dulnuan HGP, Lahoz ACF, Cabungcal ACA
- 50 **A Case Report on Madelung Disease in a 59-Year-Old Man**  
Baytec HJS, Orosa III JB

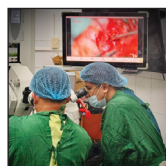

- Bridging the Publication Gap: A Special Supplemental Issue of Case Reports
- Coexisting Parotid Cholesteatoma and Temporal Bone Carcinoma: A Case Report
- Langerhans Cell Histiocytosis Presenting as a Complicated Case of Otitis Media in a One-Year-Old Girl: A Case Report
- Mucosa-Associated Lymphoid Tissue (MALT) Lymphoma of the Nasopharynx in a 21-Year-Old Woman: A Case Report
- A Case of Penetrating Craniomaxillofacial Injury in the Time of COVID-19
- Concurrent Late Post-Tonsillectomy Hemorrhage and Dengue Fever in a 17-Year-Old Girl: A Case Report
- Multiple Odontogenic Keratocysts as Initial Manifestation of Gorlin-Goltz Syndrome: A Case Report
- A Case of a Migrating Foreign Body in the Esophagus of a 65-Year-Old Woman
- Thyroid Tuberculosis with Papillary Thyroid Carcinoma in a 19-Year-Old Woman: A Case Report
- Triple Primary Malignancy (Synchronous Papillary and Follicular Thyroid Carcinomas and Diffuse B-Cell Lymphoma of the Submandibular Gland and Cervical Lymph Nodes) in a 70-Year-Old Woman
- Giant Pleomorphic Adenoma in a 64-Year-Old Woman: A Case Report
- The Supraclavicular Artery Island Flap: A Practical Approach for Reconstruction of Extensive Cervicofacial Defects Following Giant Cavernous Hemangioma Resection
- A Case Report on Madelung Disease in a 59-Year-Old Man

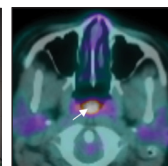
**COVER IMAGES**



"The Lucky Fisherman. A foreign body (metal rod) penetrating the craniomaxillofacial region" 3D image rendered by RadiAnt DICOM viewer version 2021.2.2.  
By Oliver Gabriel M. Baccay, MD




"Mastering the art of ear surgery: Ear surgeon fosters collaboration and innovation in the operating room"  
iPhone 16 Pro Max  
By Frederick Mars B. Untalan, MD



"PET/CT images showing nasopharyngeal thickening with FDG-avid cervical lymphadenopathy"  
Images processed with Horos  
By Ma. Katrina C. Tagata, MD



"A curious sea turtle says hello and reminds us all to protect our seas. Taken at Port Barton, Palawan"  
Samsung Galaxy S9  
By Hycel S. More, MD



"Cool Sci-Fi Mermaid with Helmet"  
Acrylic painting, (20" x 30")  
By Camille S.A. Espina, MD and Mariano B. Caparas, MD