



Ji-ilhan L. Banawol, MD
Ronaldo G. Soriano, MD

Department of Otorhinolaryngology
Head and Neck Surgery
Dr. Paulino J. Garcia Memorial Research
and Medical Center

Thyroid Tuberculosis with Papillary Thyroid Carcinoma in a 19-Year-Old Woman: A Case Report

ABSTRACT

Objective: To discuss a case of papillary thyroid carcinoma with concomitant thyroid tuberculosis in terms of clinical presentation and treatment.

Methods:

Design: Case Report
Setting: Tertiary Government Training Hospital
Patient: One

Results: A 19-year-old Filipina consulted with a four-year history of a left thyroid nodule. She was clinically euthyroid with unremarkable systemic examination. Fine needle aspiration cytology (FNAC) was suspicious for malignancy and she underwent total thyroidectomy. Histopathology revealed papillary thyroid carcinoma of the left lobe, microcarcinoma of the isthmus and incidental note of tuberculosis (TB) of the right lobe. Management included oral anti-TB medications and surveillance.

Conclusion: Tuberculosis of the thyroid gland is rare but should be considered as a differential diagnosis in a patient with exposure to tuberculosis. Co-existence of thyroid tuberculosis with papillary thyroid carcinoma is an even more rare condition. Mycobacterium tuberculosis may be associated with the development of carcinoma due to its tumorigenic effects but further studies are needed to establish this association.

Keywords: *thyroid; mycobacterium tuberculosis; thyroid carcinoma, papillary; coinfection, thyroidectomy; tuberculosis, extrapulmonary; granuloma; neck neoplasm*

Thyroid tuberculosis occurs rarely at 0.1-0.4%¹ attributed to colloid being bactericidal, the gland having extensive vascularity, with high iodine content.² Papillary thyroid cancer, on the other hand, is the most common subtype (80-85%) of well-differentiated thyroid carcinoma.³ The co-existence of thyroid carcinoma with thyroid tuberculosis is extremely rare.⁴ To the best of our knowledge, only six cases of thyroid TB and papillary thyroid cancer have been reported in the English literature,⁵ thus, treatment and diagnostic approach have not been established. Using

Correspondence: Dr. Ronaldo G. Soriano
Department of Otorhinolaryngology
Head and Neck Surgery
Dr. Paulino J. Garcia Memorial Research and Medical Center
Mabini St., Cabanatuan City, Nueva Ecija 3100
Philippines
Phone: +63 998 551 3139
Email: ronsorianomd@gmail.com

The authors declared that this represents original material that is not being considered for publication or has not been published or accepted for publication elsewhere, in full or in part, in print or electronic media; that the manuscript has been read and approved by all the authors, that the requirements for authorship have been met by each author, and that each author believes that the manuscript represents honest work. Verbal consent was obtained from the patient for publication of this case report and accompanying images.

Disclosures: The authors signed disclosures that there are no financial or other (including personal) relationships, intellectual passion, political or religious beliefs, and institutional affiliations that might lead to a conflict of interest.

Presented at the Philippine Society of Otolaryngology-Head and Neck Surgery Interesting Case Contest, Philippine Society of Otolaryngology-Head and Neck Surgery Mid-Year Convention, Limketkai Luxe Hotel Cagayan de Oro, May 4, 2019.

Presented at the Inter-Departmental Interesting Case Contest (Second Place), Dr. Paulino J. Garcia Memorial Research and Medical Center, October 10, 2018.



Creative Commons (CC BY-NC-ND 4.0)
Attribution - NonCommercial - NoDerivatives 4.0 International

“thyroid,” “tuberculosis” and “papillary carcinoma” as keywords, a search of HERDIN Plus, the Western Pacific Region Index Medicus (WPRIM), Directory of Open Access Journals (DOAJ) and MEDLINE (PubMed and PubMed Central) revealed no reported cases of co-existent thyroid tuberculosis and papillary thyroid cancer in the Philippines. We discuss the co-incident clinical presentation of these pathological lesions and their treatment.

CASE REPORT

This is a case of a 19-year-old Filipina who consulted with an anterior neck mass of four years duration and was clinically euthyroid. Neck ultrasound showed an enlarged 5.9 x 3.8 x 4.2cm left thyroid lobe with a defined 4.9 x 3.0 x 3.0 cm inhomogeneous solid mass with disorganized internal echoes occupying it entirely, and a 3.7 x 1.4 x 2.2 cm right thyroid lobe with normal echo pattern, and no cervical lymphadenopathy. Fine needle aspiration cytology (FNAC) was suspicious for malignancy. The patient underwent left thyroid lobectomy with isthmusectomy, and because frozen sections revealed papillary thyroid carcinoma, a total thyroidectomy was done.

On final histopathology, the left thyroid lobe showed well formed to complex papillae with fibrovascular core (Figure 1A) and orphan Annie nuclei and nuclear grooves (Figure 1B) consistent with papillary thyroid carcinoma. The isthmus showed micropapillary thyroid carcinoma. The right thyroid lobe showed an incidental finding of chronic granulomatous inflammatory process (Figure 2A) with Langhan’s type giant cells consistent with tuberculosis. (Figure 2B) No lymphovascular invasion or extrathyroidal extension was noted.

Review of history and records revealed no history of tuberculosis infection, and an unremarkable chest radiograph. However, she admitted exposure to pulmonary tuberculosis (PTB) from her father who underwent PTB treatment for six months, four years prior to development of the thyroid pathology. Sputum acid fast bacilli (AFB) on Direct Sputum Smear Microscopy (DSSM) and Gene Xpert were unremarkable. Anti-TB medications were started post-operatively (Rifampicin, Isoniazid, Ethambutol and Pyrazinamide for two months followed by Rifampicin and Isoniazid for four months). Since papillary thyroid carcinoma was categorized as low risk using the 2015 American Thyroid Association (ATA) Risk Stratification,⁶ Levothyroxine 100mcg

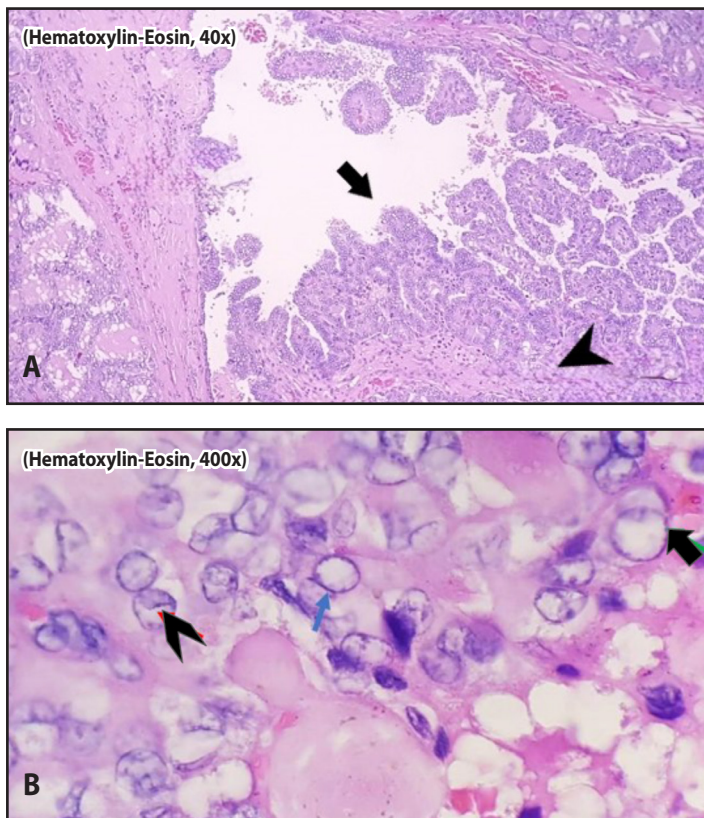


Figure 1. Thyroid left lobe histopathological section. **A.** Hematoxylin-eosin low power magnification (40X), showing well formed to complex papillae (arrow), with fibrovascular core (arrowhead); and **B.** Hematoxylin-eosin high power magnification (400X) showing orphan Annie nuclei (arrow) and nuclear grooves (arrowhead)

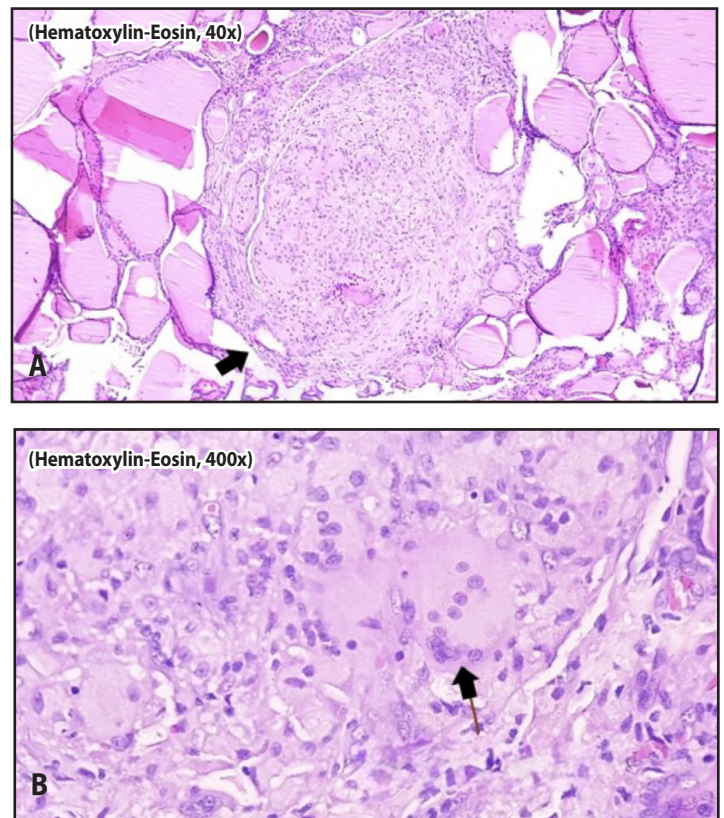


Figure 2. Thyroid right lobe histopathologic section. **A.** Hematoxylin-eosin low power magnification (40X) showing chronic granulomatous inflammatory process (arrow); and **B.** Hematoxylin-eosin, high power magnification (400 X) showing Langhans-type giant cell (arrow)



once a day was started and she was advised to obtain repeat TSH and ionized Calcium after six weeks, serum thyroglobulin after six months, and neck ultrasound after three years for surveillance. One year after the surgery and TB treatment, our patient had good wound healing and no evidence of tumor recurrence on physical examination and neck ultrasound.

DISCUSSION

Filipinos have been reported as the ethnic group with the highest incidence of thyroid cancer.⁷ Papillary carcinoma was seen in our patient's left thyroid lobe, with an incidental finding of thyroid tuberculosis in the right thyroid lobe. The usual presentation of thyroid cancer and tuberculosis is a solitary thyroid nodule.⁸ In our case, the left thyroid had a nodule with an unremarkable right thyroid lobe on ultrasound. The FNAC interpretation was suspicious for malignancy. Final histopathology revealed the presence of both papillary thyroid carcinoma and thyroid tuberculosis occurring in separate lobes of the patient's thyroid gland. An FNAC with acid-fast bacilli is considered the best method for the diagnosis of TB pre-operatively.⁹ However, the majority of thyroid tuberculosis cases are solely diagnosed based on the post-operative histopathological examination as with our case.⁵ The absence of a nodule in the right thyroid lobe where Langhan's cells were post-operatively seen in our asymptomatic patient made preoperative diagnosis challenging; and the absence of TB infection in the left lobe with papillary carcinoma made this case difficult. It would be interesting to find out if there was a previous TB infection in the left

lobe before it developed or progressed to papillary thyroid carcinoma, although this is pure conjecture at this stage.

The coexistence of malignant lesions and TB in the same anatomical location in a patient is extremely rare but has been reported in various organs⁵ such as the lung,¹⁰ colon,¹¹ and breast.¹² Tuberculous mycobacteria can induce DNA damage by producing nitric oxide and reactive oxygen species.¹³ It induces antiapoptotic activity by upregulation of B-cell lymphoma 2 gene expression and elevates prostaglandins.¹⁴ The combination of DNA damage, apoptosis inhibition and chronic inflammation gives rise to a microenvironment that is highly favorable for tumorigenesis.⁵

In our case, the thyroid nodule presented four years after PTB exposure which may have contributed to the development of papillary thyroid carcinoma, but we can only speculate in this case. The management differs; thyroid tuberculosis is treated with anti-TB medications combined with thyroidectomy,¹⁵ while papillary thyroid carcinoma involves thyroidectomy and RAI therapy. Our patient was categorized as low-risk based on the 2015 American Thyroid Association Risk Stratification, so no RAI was done. One year after the surgery and TB treatment, our patient had good wound healing and no tumor recurrence.

In summary, we discussed a case of co-existent papillary thyroid carcinoma and thyroid TB. Treatment and management should focus on appropriately addressing both entities to achieve the best outcome for the patient.

REFERENCES

- Rankin FW, Graham AS. Tuberculosis of the thyroid gland. *Ann Surg.* 1932 Oct;96(4):625-648. DOI: 10.1097/0000658-193210000-00013; PubMed PMID: 17866857 PubMed Central PMCID: PMC1391802.
- Zivaljevic V, Paunovic I, Diklic A. Tuberculosis of thyroid gland: A case report. *Acta Chir Belg.* 2007 Jan-Feb; 107(1);70-72. DOI:10.1080/00015458.2007.11680016; PubMed PMID: 17405604.
- Siddesh G, Girish TU, Mohammed R, Manjunath K. Tuberculosis of thyroid gland - a rare case report. *Thyroid Disorders Ther.* 2012;1(1):1-2. DOI:10.4172/2167-7948.1000103.
- Chakroun A, Bouziri S, Zoghleml I, Chiboub D, Nedira R. Papillary thyroid cancer (PTC) coexisting with thyroid tuberculosis: about cases. *Endocrine Abstracts.* 2024;101 PS3-21-09. DOI:10.1530/endoabs.101.PS3-21-09.
- Meng L, Hu S, Huang L, Xu C. Papillary thyroid cancer coexisting with thyroid tuberculosis: A case report. *Oncol Lett.* 2014 Feb 21;7(5):1563-1565. DOI: 103892/ol.2014.1901; PubMed PMID: 24765176; PubMed Central PMCID: PMC3997685.
- Haugen BR, Alexander EK, Bible KC, Doherty GM, Mandel SJ, Nikiforov YE, et al. 2015 American Thyroid Association Management Guidelines for Adult Patients with Thyroid Nodules and Differentiated Thyroid Cancer; The American Thyroid Guidelines Task Force on Thyroid Nodules and Differentiated Thyroid Cancer. *Thyroid.* 2016 Jan;26(1):1-133. DOI:10.1089/thy.2015.0020; PubMed PMID:26462967; PubMed Central PMCID: PMC4739132.
- Gundo W. World Health Organization Representative Office for the Philippines. It's time to end TB in the Philippines. [website article]. 2019 March 24. [cited 2025 June 30] Available from: <https://www.who.int/philippines/news/commentaries/detail/it-s-time-to-end-tb-in-the-philippines>.
- Kindie EA, Belachew TH, Habte LT, Abera SA, Dejen AM, Abebe SA, et al. Thyroid tuberculosis mimicking multinodular goiter: a case report. *J Med Case Rep.* 2024 Jul 9;18(1):324. DOI:10.1186/s13256-024-04592-2; PubMed PMID: 389787808; PubMed Central PMCID: PMC11232122.
- Goel MM, Budhwar P. Fine needle aspiration cytology and immunocytochemistry in tuberculous thyroiditis: a case report. *Acta Cytol.* 2008 Sep-Oct; 52(5):602-606. DOI: 10.1159/000325606; PubMed PMID: 18833825.
- Arliny Y, Yanifitri DB, Purqan M, Fachri M. Coexistence of pulmonary tuberculosis and small cell lung carcinoma: A significant problem in tuberculosis-endemic country? *Narra J.* 2023 Aug;3(2);e135. DOI: 1052225/narra.v3i2.135; PubMed PMID:38454974; PubMed Central PMCID: PMC10919731.
- Mallik S, Datta A, Sivasankar R, Malik A. Coexistence of carcinoma and tuberculosis in the cecum: A clinical conundrum. *Cureus.* 2024 Apr 21;16(4):e58675. DOI: 107759/cureus.58675; PubMed PMID: 38774173; PubMed Central PMCID: PMC11107136.
- Tulasi NR, Raju PC, Damodaran V, Radhika TS. A spectrum of coexistent tuberculosis and carcinoma in the breast and axillary lymph nodes: report of five cases. *Breast.* 2006 Jun;15(3):437-439. DOI: 10.1016/j.breast.2005.07.008; PubMed PMID:16198111.
- Falagas ME, Kouranos VD, Athanassa Z, Kopterides P. Tuberculosis and malignancy. *QJM.* 2010 Jul;103(7):461-487. DOI:10.1093/qjmed/hcq068; PubMed PMID:20504861.
- Zhang J, Jiang R, Takayama H, Tanaka Y. Survival of virulent Mycobacterium tuberculosis involves preventing apoptosis induced by Bcl-2 upregulation and release resulting from necrosis in J774 macrophages. *Microbiol Immunol.* 2005;49:845-852. DOI: 10.1111/j.1348-0421.2005.tb03673; PubMed PMID:16172539.
- Baidya A, Singha, Bhattacharjee R, Dalal BS. Tuberculosis of the thyroid gland: two case reports. *Oxf Med Case Reports.* 2015 Apr 16;2015(4):262-264. DOI: 10.1093; PubMed PMID:26634141; PubMed Central PMCID: PMC4664839.