

ISSN 1220-8841 (Print)
ISSN 2344-4959 (Online)

ROMANIAN
NEUROSURGERY

Vol. XXXIX | No. 3

September 2025

A bullous surprise. A rare VP shunt
complication

Mitrajit Sharma,
Awdhesh Kumar Yadav,
Aman Singh,
Aanchal Datta

DOI: 10.33962/roneuro-2025-059



A bullous surprise. A rare VP shunt complication

Mitrajit Sharma, Awdhesh Kumar Yadav, Aman Singh, Aanchal Datta

King George's Medical University, Lucknow, Uttar Pradesh, INDIA

ABSTRACT

We report a rare case of subcutaneous cerebrospinal fluid loculations, or bullae, along the anterior abdominal wall following ventriculoperitoneal shunt in an 8-year-old female with a history of tubercular meningitis and hydrocephalus. The patient presented with headache, nausea, and two soft, transilluminated swellings on the right side of her abdomen, three years after initial shunt placement and subsequent revision for peritoneal end malfunction. Imaging revealed gross ventriculomegaly and anterior parietal wall collections along the shunt tract. Intraoperatively, loculated CSF collections were found near the abdomen, and the lower end of the shunt was revised. Fluid analysis confirmed CSF composition. The patient recovered well postoperatively with resolution of ventriculomegaly and was discharged on prophylactic antibiotics. Subcutaneous CSF loculations in the anterior abdominal wall represent a unique and previously undocumented complication of VP shunts. Potential mechanisms include protracted CSF drainage, tissue plane dissection secondary to elevated intra-abdominal pressure, or catheter misplacement, exacerbated by prior abdominal surgeries and adhesions. This case highlights the importance of considering rare presentations of shunt malfunction and the need for thorough clinical and radiological evaluation. Early diagnosis and prompt surgical intervention, typically shunt revision, are crucial for effective management and improved patient outcomes.

INTRODUCTION

Ventriculoperitoneal (VP) shunts have been the primary treatment modality for hydrocephalus since the mid-20th century; despite their widespread use and advancements in surgical techniques, VP shunts are associated with a significant complication rate, reportedly reaching nearly 50% [1,2]. These complications can be broadly classified into cranial and extra-cranial, of which abdominal complications being more frequently encountered [3]. Abdominal complications include, but are not limited to, pseudocyst formation, shunt infection, bowel perforation, and distal catheter migration, with incidence varying significantly in published series [3,4]. The shunt system comprises a proximal catheter placed in the cerebral ventricle, a valve to regulate CSF flow, a reservoir, and a distal catheter that drains into the peritoneal cavity [5]. Complications can arise at any point along the shunt pathway, from the ventricular catheter to the distal peritoneal catheter, and can manifest in diverse ways depending on the location and nature of the

Keywords

ventriculoperitoneal shunt,
hydrocephalus,
CSF loculations,
abdominal wall,
complication



Corresponding author:
Mitrajit Sharma

King George's Medical University,
Lucknow, Uttar Pradesh, India

mitrajitsurgery@gmail.com

Copyright and usage. This is an Open Access article, distributed under the terms of the Creative Commons Attribution Non-Commercial No Derivatives License (<https://creativecommons.org/licenses/by-nc-nd/4.0/>) which permits non-commercial re-use, distribution, and reproduction in any medium, provided the original work is unaltered and is properly cited.

The written permission of the Romanian Society of Neurosurgery must be obtained for commercial re-use or in order to create a derivative work.

ISSN online 2344-4959
© Romanian Society of
Neurosurgery



First published
September 2025 by
London Academic Publishing
www.lapub.co.uk

problem. They can manifest as shunt infection, CSF ascites, bowel perforation, and distal catheter migration [8][9]. Shunt infection is a significant concern, as obstruction of the distal catheter must be treated as an emergency because it can lead to a significant increase in intracranial pressure. Infection rates vary in reports from 5% to 15% and typically manifest as fever, headache, and neck stiffness, although these symptoms may be subtle or absent, particularly in infants. Wound breakdown and skin erosion over the shunt tract can also occur, increasing the risk of infection and requiring surgical revision.

CSF ascites is a rare complication characterized by the accumulation of CSF in the abdominal cavity, leading to abdominal distension and discomfort. Bowel perforation is another rare but serious complication that can result from direct erosion of the shunt catheter into the bowel lumen, leading to peritonitis and sepsis. Distal catheter migration can occur in various directions, including into the chest cavity, retroperitoneal space, or even through the abdominal wall. The management of these extra-abdominal complications depends on the specific nature of the problem, but often involves surgical revision of the shunt system [10]. We present an operated case of tubercular meningitis with ventriculomegaly with shunt in situ, who presented with a peculiar complication of subcutaneous CSF filled bullae over the abdomen.

CASE PRESENTATION

An 8-year-old female presented to our department with complaints of headache and nausea, accompanied by two swellings on the right side of her abdomen for 20 days. She had a history of tubercular meningitis with hydrocephalus and underwent a right parietal medium pressure VP shunt three years prior. Within a month post-procedure, she was readmitted with recurrent ventriculomegaly, which was attributed to peritoneal end malfunction, and the lower assembly of the shunt was revised. She recovered and was subsequently followed up.

Upon presentation, the two abdominal swellings or CSF bullae were measured to be 4cm by 3 cm, soft, non-reducible, and brilliantly transilluminated, with a parchment-like thinned-out layer of epidermis covering them. (Figure 1 & 2) Deep palpation revealed no underlying collection.

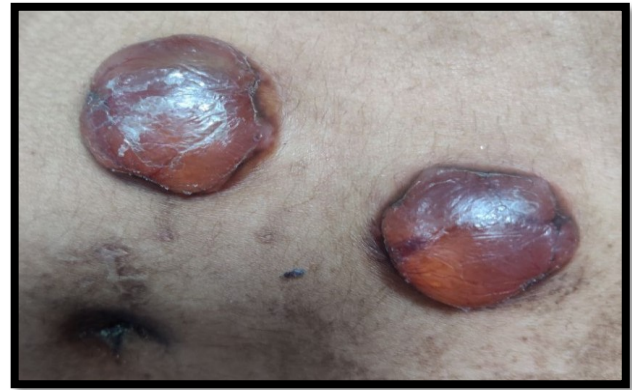

Figure 1. Thinned out parchment like epidermis with CSF bullae

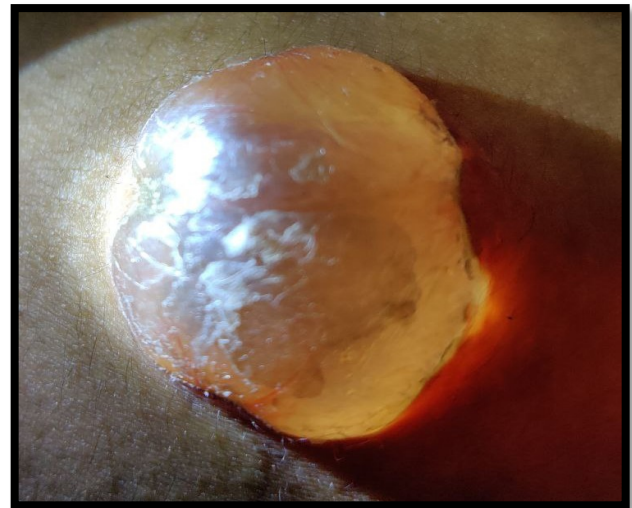


Figure 2. Brilliant transillumination of the CSF bullae.

Ultrasonography suggested two anterior parietal wall collections, with the shunt passing within the swellings. (Figure 3) A CT scan of the brain revealed gross ventriculomegaly.

She underwent shunt revision from the left side. Intraoperatively, the abdominal end was found to be intraperitoneal, but there were loculated collections of CSF along the shunt tract near the abdomen. The lower end was removed, and the CSF loculations were excised via a superficial incision. The fluid was sent for routine microscopy and culture. The reports were consistent with that of CSF collected from the ventricles, and she was placed on prophylactic antibiotics. Ventriculomegaly was reduced within 3-4 days, and she was discharged uneventfully on the 6th postoperative day. She is currently in follow-up and is doing well.

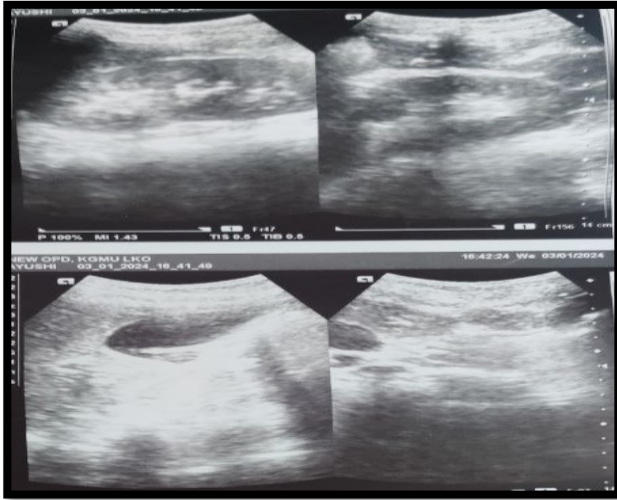


Figure 3. USG showing abdominal wall swelling with the shunt within it.

DISCUSSION

Malfunction of ventriculoperitoneal shunts in children may be difficult to diagnose early because the symptoms and signs are nonspecific [11]. In addition to a thorough clinical examination, radiological investigations, including plain radiography, ultrasound, CT and nuclear medicine scans, are essential to establish the diagnosis [3]. The imaging techniques can aid early detection of intraabdominal complications. Radiography can reveal the location of the shunt tip, displaced bowel gases, soft-tissue mass of pseudocyst, and intraperitoneal free air. CT scans can be used to reveal intraabdominal complications such as abscesses, pseudocysts, fluid collection, and bowel perforation.

The development of CSF loculations along the anterior abdominal wall in our patient constitutes a unique and previously undocumented complication of VP shunts, for which the underlying mechanisms are likely multifactorial. Protracted CSF drainage may result in the formation of seromas or loculated fluid collections, particularly in regions characterized by distinct tissue planes. A plausible explanation posits the gradual dissection of CSF along these tissue planes, potentially secondary to elevated intra-abdominal pressure or catheter misplacement. The placement of VP shunts necessitates meticulous navigation of the peritoneal space, a region notable for its complex anatomy and predisposition to adhesions, especially in patients with prior abdominal surgical interventions. Our patient,

having undergone two prior surgical procedures, including a revision of the distal shunt component, may have been predisposed to conditions conducive to this complication. These adhesions can compartmentalize the peritoneal cavity, thereby impeding the normal distribution of CSF and increasing the susceptibility of certain areas to fluid accumulation.

CONCLUSION

Ventriculoperitoneal shunting remains a cornerstone intervention for managing hydrocephalus across diverse patient populations. Despite its widespread application and established efficacy, the procedure is not devoid of potential complications, with abdominal sequelae constituting a significant subset. Abdominal complications following VP shunt placement can manifest in various forms, encompassing catheter migration, bowel perforation, peritonitis, abscess formation, and pseudocyst development. Management strategies for these complications are equally diverse, ranging from conservative measures such as observation and antibiotics to more invasive interventions like shunt revision, catheter repositioning, or even complete shunt removal. Subcutaneous CSF loculations in the anterior abdominal wall are a very rare consequence. In such cases, shunt revision is usually performed to correct the problem. Early diagnosis and prompt intervention are critical for effective management and to improve patient outcomes. Ultimately, a comprehensive understanding of these potential complications, coupled with vigilant monitoring and timely intervention, is essential to optimize outcomes and minimize morbidity in patients undergoing VP shunt procedures.

REFERENCES

1. Chung JJ, Yu JS, Kim JH, Nam SJ, Kim MJ. Intraabdominal Complications Secondary to Ventriculoperitoneal Shunts: CT Findings and Review of the Literature. 2009.
2. Xu J, Poole C, Sahyouni R, Chen JW. Noninvasive thermal evaluation for shunt failure in the emergency room. *Surgical Neurology International* [Internet]. 2019 Dec 27 [cited 2025 Feb];10:254. Available from: https://doi.org/10.25259/sni_324_2019
3. Agha F, Amendola MA, Shirazi KK, Amendola BE, Chandler WF. Unusual abdominal complications of ventriculoperitoneal shunts. *Radiology* [Internet]. 1983 Feb 1 [cited

- 2025 May];146(2):323. Available from: <https://doi.org/10.1148/radiology.146.2.6849079>
4. Furtado LMF, Val Filho JADC, Faleiro RM, Vieira JAL, Santos AKD dos. Abdominal Complications Related to Ventriculoperitoneal Shunt Placement: A Comprehensive Review of Literature. 2021.
 5. Ferras M, McCauley N, Stead T, Ganti L, Desai B. Ventriculoperitoneal Shunts in the Emergency Department: A Review. *Cureus* [Internet]. Cureus, Inc.; 2020 Feb 3 [cited 2025 Feb]; Available from: <https://doi.org/10.7759/cureus.6857>
 6. Stoddard T, Kavic SM. Laparoscopic Ventriculoperitoneal Shunts: Benefits to Resident Training and Patient Safety. *JLS Journal of the Society of Laparoscopic & Robotic Surgeons* [Internet]. 2011 Jan 1 [cited 2025 Feb];15(1):38. Available from: <https://doi.org/10.4293/108680811x13022985131093>
 7. Popa F, Grigorean VT, Onose G, Popescu M, Strâmbu V, Sandu AM. Laparoscopic treatment of abdominal complications following ventriculoperitoneal shunt. *Journal of Medicine and Life* [Internet]. 2009 Nov 15 [cited 2025 Feb];2(4):426. Available from: <https://europepmc.org/article/MED/20108757>
 8. Bolster F, Fardanesh R, Morgan T, Katz D, Daly B. Cross-sectional imaging of thoracic and abdominal complications of cerebrospinal fluid shunt catheters. 2015.
 9. Zenda T, Sawada E, Araki I. Ventriculoperitoneal Shunt-related Intrapelvic Abscess. *Internal Medicine* [Internet]. 2019 Nov 28 [cited 2025 May];59(7):1017. Available from: <https://doi.org/10.2169/internalmedicine.3908-19>
 10. Wong JM, Ziewacz JE, Ho AL, Panchmatia JR, Bader AM, Garton H, Laws ER, Gawande AA. Patterns in neurosurgical adverse events: cerebrospinal fluid shunt surgery. *Neurosurgical FOCUS* [Internet]. American Association of Neurological Surgeons; 2012 Nov 1 [cited 2025 May];33(5). Available from: <https://doi.org/10.3171/2012.7.focus12179>
 11. Muñoz-Santanach D, Maza VTS de la, Canto SC, Cubells CL. Escala clínica para el diagnóstico de disfunción de válvula ventriculoperitoneal en niños en el Servicio de Urgencias. *Anales de Pediatría* [Internet]. 2015 Jul 29 [cited 2025 Feb];84(6):311. Available from: <https://doi.org/10.1016/j.anpedi.2015.06.009>