

Rare occurrence of Bilateral Dentigerous Cyst involving Impacted and Malformed Maxillary Central Incisors

**Dr. Prachi Nayak, M.D.S¹, Dr. Sushruth Nayak, M.D.S², Dr. Himanshi, M.D.S³,
Dr. Nandini Bhardwaj, M.D.S⁴**

¹Professor Department of Oral and Maxillofacial Pathology and Oral Microbiology M.M. College of Dental Sciences & Research M.M (Deemed to be university) Mullana, Ambala, Haryana.

²Professor & Head Department of Oral and Maxillofacial Pathology and Oral Microbiology M.M. College of Dental Sciences & Research M.M (Deemed to be university)Mullana, Ambala, Haryana.

³Lecturer Department of Oral and Maxillofacial Pathology and Oral Microbiology M.M. College of Dental Sciences & Research M.M (Deemed to be university) Mullana, Ambala, Haryana.

⁴Lecturer Department of Oral and Maxillofacial Pathology and Oral Microbiology M.M. College of Dental Sciences & Research M.M (Deemed to be university) Mullana, Ambala, Haryana.

Department of Oral and Maxillofacial Pathology and Oral Microbiology, Maharishi Markandeshwar College of Dental Sciences & Research Maharishi Markandeshwar (Deemed to be university) Mullana, Ambala, Haryana - 133207.

Corresponding Author:

Dr. Sushruth Nayak, M.D.S

Professor & Head Department of Oral and Maxillofacial Pathology and Oral Microbiology
M.M. College of Dental Sciences & Research M.M (Deemed to be university)
Mullana, Ambala, Haryana -133207 INDIA. Phone: +91-9755443274
E-mail: sushruth79@mmumullana.org

Total number of pages: Nine

Total number of words count for abstract: Sixty eight

Total number of words count for text: Thousand

Total number of photographs: Six

KEYWORDS

ABSTRACT

dentigerouscyst,
malformed
tooth, maxilla.

Abstract:

Dentigerous cysts are one of the common lesions of the maxillofacial region, surrounding the unerupted crown by attaching to its cervical portion. Dentigerous cyst is reported to be associated with unerupted, supernumerary teeth, odontomas and rarely deciduous teeth. Rarely does it involve central incisors and supernumerary teeth. This case report involves an unusual case of dentigerous cyst in the maxillary anterior region involving unerupted, malformed maxillary central incisors.

Introduction:

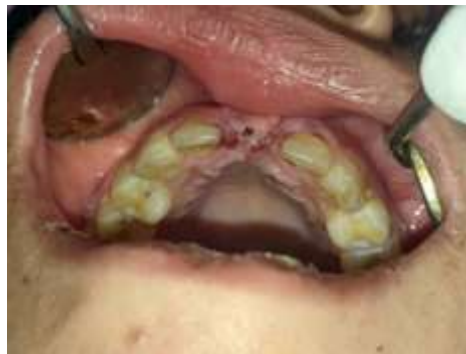Dentigerous cysts are one of the common lesions of the maxillofacial region, surrounding the unerupted crown by attaching to its cervical portion.^{1,2} Term Dentigerous means “containing tooth”. It accounts for 15.2% -33.7% of all odontogenic cysts.^{3,4} Dentigerous cyst may occur at any age but most incidence reported in second and third decade of life. Higher number of cases reported in males as compared to females.⁵ Dentigerous cyst is reported to be associated with unerupted, supernumerary teeth, odontomas and rarely deciduous teeth.⁶ Most commonly affected teeth are mandibular 3rd molar followed by maxillary canine, mandibular premolar and maxillary

3rd molar. Rarely does it involve central incisors and supernumerary teeth.^{7,8} We report an unusual case of dentigerous cyst in the maxillary anterior region involving unerupted, malformed maxillary central incisors.

Case Report:

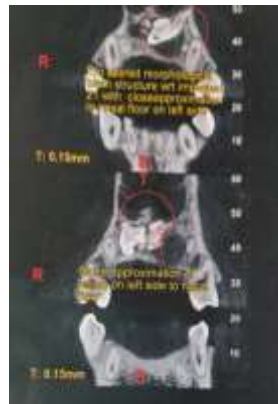A 22 year old female patient reported to the Oral medicine and radiology department with swelling and pus discharge in maxillary anterior region. She gave a history of trauma in the maxillary anterior region at the age of 5 years. Patient complained of dull, non radiating pain and pus discharge since 2 – 3 weeks. She had visited the local practitioner in her village who gave an incision on the alveolar ridge area to drain the pus. For short period it gave her relief. Then she reported to our institute. On intra oral examination a solitary, diffuse swelling in maxillary labial vestibular area was visible extending from left lateral incisor to right lateral incisor region. Both the central incisors were missing. Swelling was fluctuant and tender on palpation (Figure 1).

Figure 1: Diffuse swelling in maxillary labial vestibular area was visible extending from left lateral incisor to right lateral incisor region



Computerised tomography of the maxilla revealed well defined, radiodense lesion representing impacted teeth with morphologically altered teeth wrt 11, 21 region. Well defined radiodensity similar to that of enamel, dentin and pulp arranged haphazardly simulating that of a malformed tooth structure in its greatest dimension. Lesion in maxillary anterior region was of size mesiolaterally 19.2 mm, antero posteriorly of 11.4 mm with altered tooth structure in it. The lesion was bordered with well-defined radiolucent margin. No nasal breach on right side but close approximation of impacted tooth to nasal floor of right side. Thinning of buccal and palatal cortical plates was observed wrt impacted 21 having altered morphology. Distally placed morphologically altered 11 was with close approximation with nasal floor (Figure 2). Provisional diagnosis of dentigerous cyst associated with malformed incisors was given.

Figure 2: Well defined radio density simulating that of a malformed tooth structure in its greatest dimension



Patient was operated under local anesthesia. To avoid excessive bone loss, teeth were partially exposed and removed with surrounding soft tissue (Figure 3). The enucleated specimen contained 2 malformed hard tissues (tooth specimen) and bits of soft cystic lining (Figure 4).

Figure 3: Partial exposure and removal of teeth with surrounding tissue

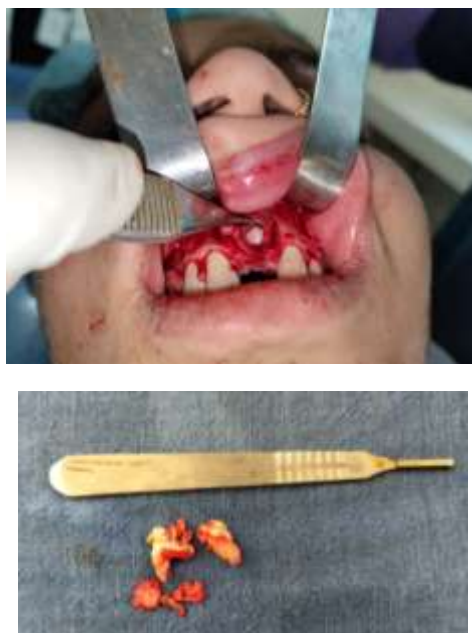

Figure 4: Grossed specimen

The H and E stained soft tissue section revealed the presence of non-keratinized stratified squamous epithelial lining resembling reduced enamel epithelium and connective tissue wall surrounding the cystic lumen. The cystic lining was 2-3 cell layer in thickness without any rete ridge formation. The connective tissue wall was composed of plump fibroblasts, delicate collagen fiber bundles, blood vessels along with areas of extravasated RBC's. Presence of moderate amount of chronic inflammatory cell infiltrate was observed (Figure 5). The H and E stained decalcified section of tooth revealed the presence of tooth like structure composed of dentin, a thin layer of cementum along with pulp tissue (Figure 6). Overall features were suggestive of dentigerous cyst associated with impacted and malformed incisors.

Figure 5: The cystic lining resembling reduced enamel epithelium along with connective tissue

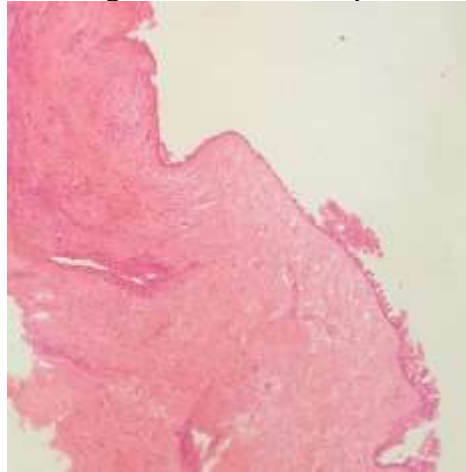
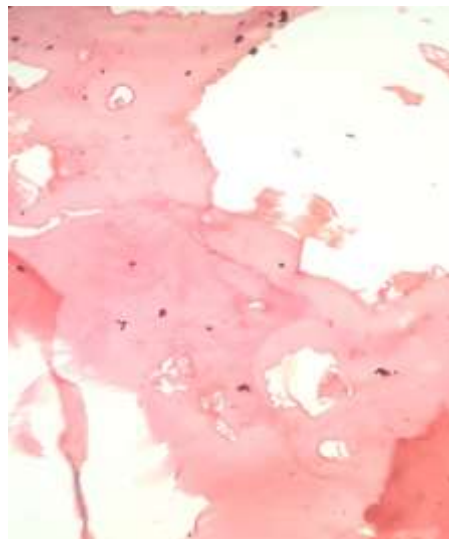

Figure 6: decalcified section of tooth revealed the presence of tooth like structure composed of dentin, a thin layer of cementum along with pulp tissue



Discussion:

Intrafollicular theory for pathogenesis of dentigerous cyst formation states that fluid accumulation occurs between the layers of inner and outer enamel epithelium. According to Main's theory the impacted tooth exerts pressure on the follicle and obstructs the venous outflow which induces rapid transformation of serum across the capillary walls.⁹ This pathogenesis is mainly developmental and occurs in mature teeth.¹⁰ Another concept is of inflammatory etiology which states that inflammation at the apex of a deciduous tooth may leads to development of an inflammatory dentigerous cyst.¹¹ This type usually occurs in immature teeth as a result of inflammation of a non vital deciduous teeth or some other source spreading to involve the tooth follicle.¹⁰

In our case the cyst was probably of inflammatory origin. There are few cases mentioned in the literature reporting the occurrence of deciduous cyst associated with bilateral impacted and deformed maxillary central incisors. Majority of the cases reported mandible as the common site

of occurrence. In this unique case the dentigerous cyst was enclosing both the maxillary central incisors.

Trauma plays an important role in delayed eruption of teeth.¹² Andersson has reported a 20% prevalence of traumatic dental injuries (TDI) in children and adolescents.¹³ These traumatic injuries in primary dentitions can affect the development of permanent teeth. Damage or disturbances to permanent teeth and gingiva can range from mild to severe. TDI can cause pulpal necrosis, internal/external root resorptions and can influence the development of maxillofacial region.¹⁴

It is unusual to report many pathologies in the same region as in our case we have reported the presence of deformed and impacted maxillary central incisors bilaterally, associated with Dentigerous cyst where post trauma the patient reported missing both the maxillary central incisors and swelling in the same region. In this unusual case the history of trauma in primary teeth causes malformed bilateral incisors and also association of dentigerous cyst preventing the eruption of both the central incisors.

Conclusion:

While most of the teeth post trauma are accompanied by fractures or resorptions of tooth roots. In this case it is noted bilateral maxillary centrals were malformed and instead were associated with dentigerous cyst.

References:

1. Shear M, Speight PM. Dentigerous Cyst of the Oral and Maxillofacial region. 4th ed USA:Blackwell Publishing Professional;2007.p.59-75
2. Boyczuk MP, Berger JR, Lazowski SK. Identifying a deciduous Dentigerous cyst. J Am Dent Assoc 1995;126:643-4.
3. Arjona Amo M et al. Conservative management of Dentigerous Cysts in Children. J Clin ExpDent.2015;7(5):671-674.
4. Shamimul H et al. Dentigerous Cyst in association with Impacted Inverted Mesiodens:Report of a rare case with a brief review of literature. International Journal of Applied and Basic Medical Research. 2014;4(1):61-64.
5. Shear M. Dentigerous (follicular) cyst in :Cysts of Oral Region,2nd ed. Bristol:Wright PSG; p.56-75.
6. Agrawal M, RaghavendrsPD, Singh B, Agrawal N. Multiple teeth in a single Dentigerous cyst follicle:A Perplexity. Ann Maxillofac Surg 2011;1:187-9.
7. Desai RS, Vanaki SS, PuranikRS, Tegginamani AS. Dentigerous cyst associated with permanent cenral incisor: a rare case entity. J Indian Soc Pedod Prev Dent. 2005;23(1):49-50.
8. Lustman J, Bodner L. Dentigerous cyst associated with supernumerary teeth. Int J Oral Maxillofac Surg. 1988;17:100-2.
9. Dahiwal P, Sodhi S, Kale L, Khampte N. A rare Dentigerous cyst of Maxillary central incisor associated with multiple impacted teeth: case report and review of literature. J Indian Acad Oraal Med Radiol 2015;27:273-8.
10. Benn A, Altini M. Dentigerous cysts of Inflammatory origin: a clinicopathological study. Oral Surg Oral Med Oral Pathol Oral Radiol Endod. 1996;81:203-9.
11. Kamra S, Pai KM, Vineetha R, Kamath A, Kudwa A. Dentigerous cyst associated with unerrupted mandibular second molar: An unusual entity. J Health Sci Res. 2018;9(1):31-33.
12. Shanmughan AM, Verghese RS, Nair PK et al. BMJ Case Rep. 2023;16:e254051.
13. Andersson L. Epidemiology of traumatic dental injuries. J Endod. 2013;39:52-5.
14. Antipoviene A, Narbutaite J, Virtanen JI. Traumatic dental injuries, treatment and complications in children and adolescents: a register based study. Eur J Dent. 2021;15:557-62.