

Macro anatomical variations of human dry mandible in the perspective of cortico-basal implantology

Goutam Das¹, Madhumita Majumdar², Nandita Datta³, Subhasis Chakraborty⁴, Manoj K Singh⁵, Tamal K Pal⁶

¹Ph.D. Scholar, Department of Oral & Dental Sciences, JIS University, Kolkata and Reader, Department of Periodontics, GNIDSR, Kolkata, India.

²Professor and Head, Department of Oral & Dental Sciences, JIS University, Kolkata, India.

³Professor and Head, Department of Anatomy, Jalpaiguri Government Medical College and Hospital, Jalpaiguri, West Bengal, India.

⁴Department of Anatomy, College of Medicine & Sagore Dutta Hospital, Kolkata, India.

⁵Professor and Head, Department of Periodontics, Hazaribagh College of Dental Sciences & Hospital, Jharkhand, India.

⁶Emeritus Professor & Director (Research), JIS University, Kolkata, India.

*Corresponding Author: Dr. Goutam Das

Ph.D. Scholar, Department of Oral & Dental Sciences, JIS University, Kolkata and Reader, Department of Periodontics, GNIDSR, Kolkata, India

KEYWORDS

Strategic location, cortical bone, rehabilitation, immediate loading, osseo-fixation.

ABSTRACT:

Background: Conventional dental implants are not possible in the edentulous mandible where there is a lack of enough residual alveolar bone. Those cases can be served better with an alternate implant system known as Cortico basal implantology. The implants are inserted into denser and more stable basal and cortical bone. In this unconventional implant system, implants are placed and prosthetically loaded immediately. There is a need to know the macroscopic dimensions of basal cancellous and cortical bone of edentulous mandible to achieve clinical success. **Methods:** Dry mandibles were collected from Department of Anatomy, CMSDH, Kolkata. The basal cancellous and cortical bone samples were obtained from dry mandible with the help of rotary instrument. The thickness of those bones was measured with the help of vernier caliper and/or gauge meter. **Results:** The mean thickness of basal cancellous bone heights of anterior mandible is 20.43 ± 0.08 mm. and cortical bone in anterior, premolar and molar regions are 2.71 ± 0.03 mm., 2.82 ± 0.04 mm., 3.09 ± 0.04 mm. respectively. **Conclusions:** The morphological dimensions of cortical and basal cancellous bone have been derived.

INTRODUCTION

The conventional dental implant system is a successful treatment modality subject to available quality and quantity of residual alveolar bone (1,2). Lack of bone demands bone augmentation for implant insertion which is time consuming, expensive, unpredictable, and moreover morbid for the patients (3,4). In conventional implant system, there is a long waiting period of 4 to 6 months for osteointegration to take place (5). Because of these demerits, there has been an increasing demand of an alternative implant system (6). The target of this system is to access the far-located dense bone to get optimum initial stability of the implant. The cortical bone nearest to the edentulous area is situated underneath the mucosa known as the first cortical (7). This is followed by the cancellous bone of the residual alveolar process. Subjacent to the alveolar process, a thick and denser cancellous bone, located beyond the level of the apices of root is the basal bone, and then most distantly located, highly dense and least resorbable cortical bone is the second cortical (8). This unique bone appears as a radiopaque sharp line in radiographs. The second cortical in case of mandible are the buccal and lingual cortical plates and at the base of the mandible. The implants can better be engaged either into tough cancellous basal bone or into the second cortical bone. The system is known as Basal and Cortical implant. This type of implant must be

loaded immediately (within 72 hours); even in highly resorbed edentulous situations (9,10). For better understanding there is a need-to-know macro anatomical variations of basal and cortical bone for successful insertion of implants. The highly resorbed situations can be successfully treated with this unconventional single stage basal and cortical implants. The implants achieve the optimum initial stability from the dense and least resorbable basal and cortical bone and thus, can be loaded immediately or within 72 hrs.

MATERIALS AND METHODS

To fill-up the gap of knowledge about the morphometry of the basal cancellous and cortical bone of jaws, especially in this part of the country, the present study was designed for the benefit of implant practice. The present morphometric study was designed to measure the width/thickness of the basal cancellous and cortical bone of human dry skull mandibles. Over a period of two years, human dry mandibles (n=50) were procured from the Department of Anatomy, College of Medicine and Sagore Dutta Hospital, Kolkata -700058 (Figure 1). The strategic locations of mandible are (I) basal and cortical bone of mandibular symphysis inter-foraminal area (II) lingual cortical of mandibular premolars areas, and (III) lingual shelf of mandibular third molar area. After obtaining the dry mandible, the strategic locations were selected and marked with marking pen (Figure 2). The basal cancellous and cortical bone from strategic locations of mandible were identified and separated with the help of rotary instrument and diamond disc (Figure 3). From the collected samples the height of the basal cancellous and the thickness of cortical bone were measured with the help of electronic vernier caliper or manual gauge meter as and when suitable (Figure 4).

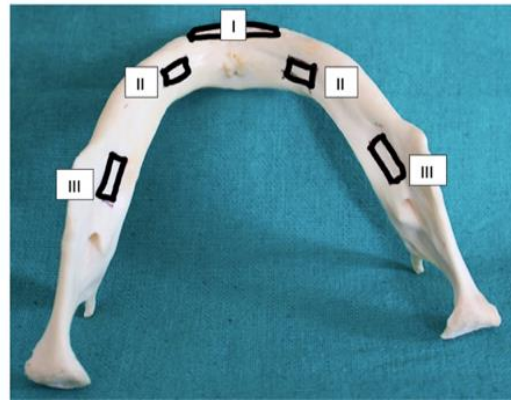
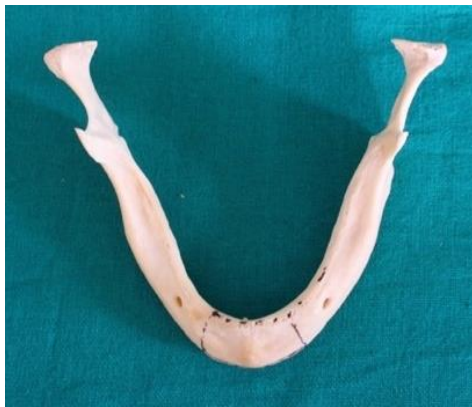

Figure 1. Edentulous mandible. Figure 2. The strategic locations of mandible; Inter-foraminal region (I), Lingual cortical of premolar area (II), lingual shelf cortical of third molar area (III).

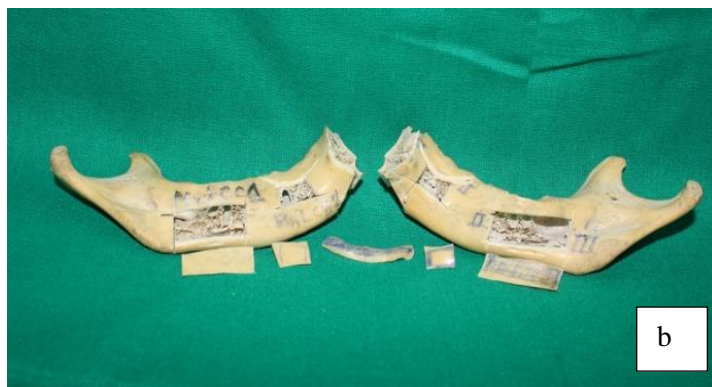
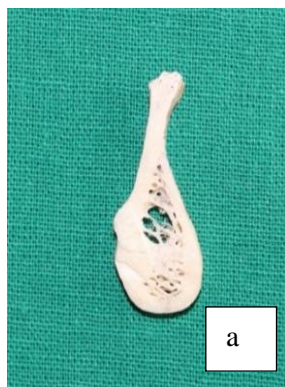
Figure 3. Separated bone samples; (a) Inter-foraminal region-sagittal section (b) Lingual cortical

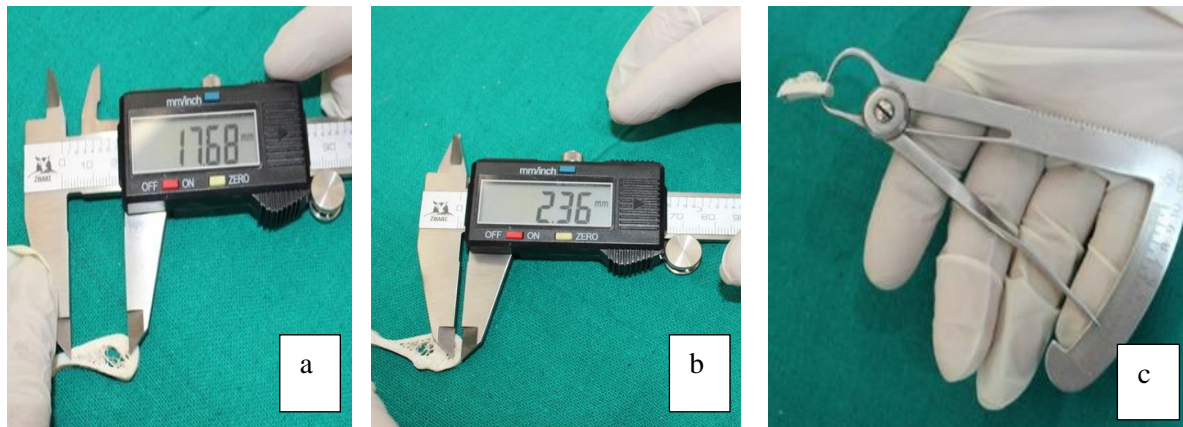


Figure 4. Measurement of (a) height of basal cancellous bone, (b) and (c) thickness of cortical bone with the help of electronic vernier caliper and manual gauge meter.

RESULTS AND STATISTICAL ANALYSIS

The mean thickness of basal trabeculae and cortical plate at strategic locations of mandibles were noted in table (Table-1) and results were represented in bar diagram (Figure 5 to 8). Table- 1 and Figures 5 to 8 tabulates and illustrates the descriptive statistics of the study variables respectively.

The collected data was tabulated in a spreadsheet using Microsoft Excel 2021 and then statistical analysis was carried out using IBM SPSS Statistics for Windows, Version 27.0. (Armonk, NY: IBM Corp). A Shapiro-Wilk's test and a visual inspection of the histograms, normal Q-Q plots, and box plots showed that the collected data were approximately normally distributed. Descriptive statistics were used to report the quantitative variables in terms of the mean/median (Mdn) (central tendency) and standard error (SEM)/inter-quartile range (IQR) (measures of dispersion), along with the minimum and maximum values to report the range. Additionally, the 95% confidence interval (CI) was reported to provide an estimate of the interval within which the true population parameter is expected to lie with 95% confidence.

- **Cancellous Bone - Anterior Region**

In the cancellous bone of the anterior region, the mean value in the third quadrant was 20.47 ± 0.12 mm, with a 95% confidence interval of 20.23 to 20.72. In the fourth quadrant, the mean value was 20.39 ± 0.09961 mm, with a 95% confidence interval of 20.20 to 20.59. For the combined data from both quadrants, the mean value was 20.43 ± 0.08 mm, with a 95% confidence interval of 20.28 to 20.59.

- **Cortical Bone - Anterior Region**

In the cortical bone of the anterior region, the mean value in the third quadrant was 2.71 ± 0.04 mm, with a 95% confidence interval of 2.64 to 2.78. In the fourth quadrant, the mean value was 2.706 ± 0.04 mm, with a 95% confidence interval of 2.63 to 2.79. For the combined data from both quadrants, the mean value was 2.71 ± 0.03 mm, with a 95% confidence interval of 2.65 to 2.76.

- **Cortical Bone - Premolar Region**

In the cortical bone of the premolar region, the mean value in the third quadrant was 2.86 ± 0.06 mm, with a 95% confidence interval of 2.75 to 2.97. In the fourth quadrant, the mean value was 2.78 ± 0.06 mm, with a 95% confidence interval of 2.67 to 2.89. For the combined data from both quadrants, the mean value was 2.82 ± 0.04 mm, with a 95% confidence interval of 2.74 to 2.9.

- **Cortical Bone – Third Molar Region**

In the cortical bone of the third molar region, the mean value in the third quadrant was 3.05 ± 0.06 mm, with a 95% confidence interval of 2.93 to 3.18. In the fourth quadrant, the mean value was 3.125 ± 0.06 mm, with a 95% confidence interval of 3.1 to 3.25. For the combined data from both quadrants, the mean value was 3.09 ± 0.04 mm, with a 95% confidence interval of 3 to 3.17.

Table 1: Descriptive statistics of the study variables

Type of Bone and Region	Quadrants	Mean±SEM	95%CI	Median (Q1-Q3)	Min-Max
Basal Cancellous Bone- Anterior Region (31,32,33 and 41,42,43)	3 rd quadrant (n=150)	20.47±0.12	20.23-20.72	20.23(19.98-21.12)	12-26.67
	4 th quadrant (n=150)	20.39±0.1	20.2-20.59	20.18(19.98-21.03)	17.1-25.12
	Total (N=300)	20.43±0.08	20.28-20.59	20.23(19.98-21.1)	12-26.67
Cortical Bone- Anterior Region (31,32,33 and 41,42,43)	3 rd quadrant (n=150)	2.71±0.04	2.64-2.78	2.8(2.25-3.1)	1.89-3.78
	4 th quadrant (n=150)	2.71±0.04	2.63-2.79	2.87(2.21-3.12)	1.67-4.1
	Total (N=300)	2.71±0.03	2.65-2.76	2.87(2.23-3.1)	1.67-4.1
Cortical Bone- Premolar Region (34,35 and 44,45)	3 rd quadrant (n=100)	2.86±0.06	2.75-2.97	2.78(2.45-3.45)	1.78-3.98
	4 th quadrant (n=100)	2.78±0.06	2.67-2.89	2.76(2.4-3.35)	1.78-3.98
	Total (N=200)	2.82±0.04	2.74-2.9	2.77(2.44-3.35)	1.78-3.98
Cortical Bone- Third Molar Region at Lingual shelf (38 and 48)	3 rd quadrant (n=50)	3.05±0.06	2.93-3.18	2.9(2.78-3.38)	2.35-3.98
	4 th quadrant (n=50)	3.13±0.06	3.01-3.25	2.98(2.85-3.56)	2.34-3.98
	Total (N=100)	3.09±0.04	3-3.17	2.98(2.78-3.38)	2.34-3.98

N: Total sample size (per region) ;n: sample size per quadrant
 SEM: Standard Error of Mean; CI: Confidence Intervals; Q1:First Quartile; Q3:Third Quartile; Q1-Q3:Inter-quartile Range; Min-Minimum value; Max: maximum value

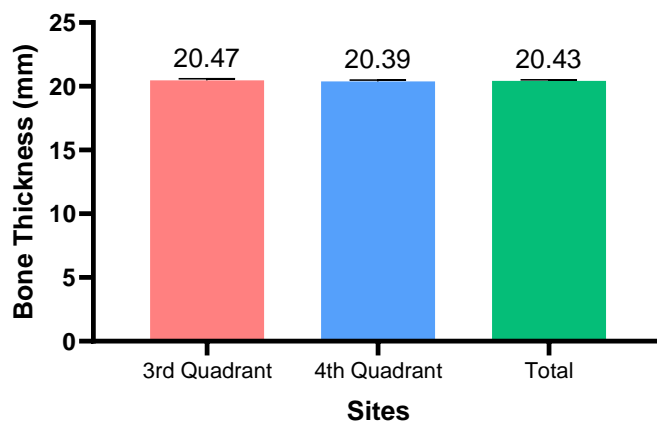


Figure 5: Bar Graph showing the mean and standard error of the mean (SEM) for the Cancellous Bone in the 3141 | Page

Anterior Region, presented for each respective quadrant and for the combined data.

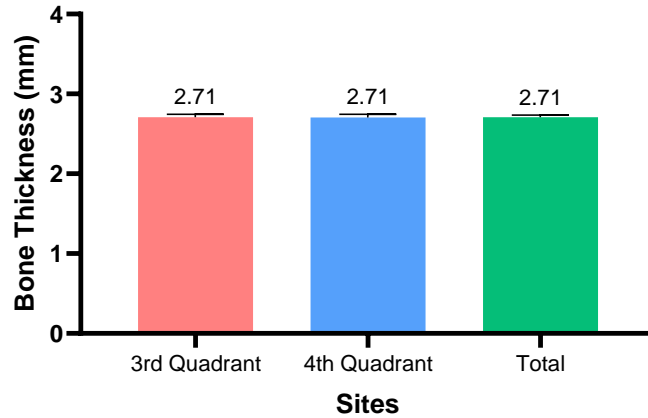


Figure 6: Bar Graph showing the mean and standard error of the mean (SEM) for the Cortical Bone in the Anterior Region, presented for each respective quadrant and for the combined data.

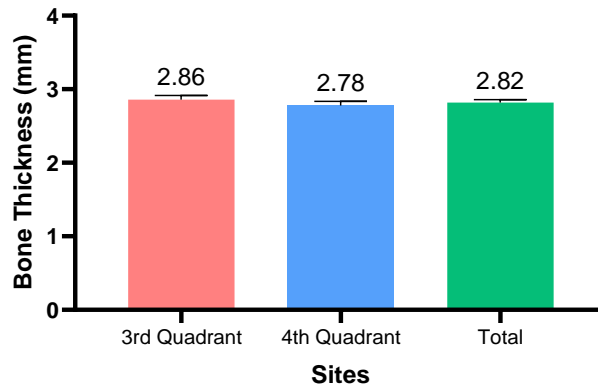


Figure 7: Bar Graph showing the mean and standard error of the mean (SEM) for the Cortical Bone in the Premolar Region, presented for each respective quadrant and for the combined data.

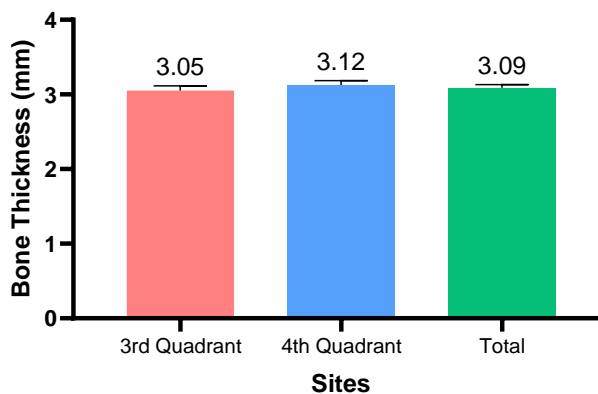


Figure 8: Bar Graph showing the mean and standard error of the mean (SEM) for the Cortical Bone in the third Molar Region, presented for each respective quadrant and for the combined data.

DISCUSSION

In basal and cortical implantology the implants are placed into the basal cancellous or cortical bone and instantly the primary stability is achieved for immediate loading. The cortical implant system wins over the conventional system in the sense that a long-cherished desire of immediate function is addressed positively and successfully (2,11,12,13). The highest degree of availability of basal cancellous bone was seen in mandibular symphysis area.

Especially the basal cancellous bone is very strong and most of the cases the amount of basal trabecular bone was found abandoned. Correspondingly the cortical bone is sufficiently thick. This unique presence of basal cancellous and cortical bone in the symphysis region gives the advantages to the clinician for placement of implants only on basal cancellous bone and there is no need to reach up to the cortical bone.

The lingual cortical bone in premolar areas has got an average thickness 1.78 mm. at the level below mylohyoid muscles, which is essentially enough to engage few of five sharp blades of an implant. The lingual shelf of lingual plate in third molar area provides a thickness of 2.34 mm. which allows implant to be placed in a safer zone below the mylohyoid line (6). There is insignificant difference in the pattern of variations of cortical thickness in the lingual area compared to cortical thickness at the base of the mandible in symphysis area. Almost in all cases of implant placements, such heavily thick cortical bone is not used. The sharp difference in torque for osteotomy of basal cancellous bone and cortical bone clearly indicates that the revolution per minute (RPM) of drill speed is required to be adjusted accordingly. The more the thickness is the more the torque required.

It was also observed that there was not much significant difference of concentration of osteons between cancellous bone and cortical bone. This shows the bone is basically made up of building blocks irrespective of its placements in basal cancellous or in cortical bone.

Such studies should be conducted on various population of world encompassing other ethnic population to reveal the anatomic variation. An approach of such study should also be done using CBCT technique as well.

CONCLUSION

The study reveals the bone dimensions at various strategic locations of human mandible for the purpose of engaging implants for immediate functioning. The overall results support the view that 2.71-3.09 mm. of cortical bone is available throughout the mandible for the anchorage of implants. However, the basal cancellous bone height of 20.43mm. is available for implant engagement.

Financial support and sponsorship: Nil

Conflicts of interest: There are no conflicts of interest.

REFERENCES

1. Pal T.K. Fundamental and history of implant dentistry. *Int. Clin. Dent Res Organ.* 2015;7:6-12.
2. Das Goutam, Pal T.K., Datta Nandita, Roy Sourav. Basal and cortical implants as an alternative to conventional dental implant-a review. *International Journal of Scientific Research.* 2024;13(7):78-79.
3. Saeed F, Muhammad N, Khan AS, Sharif F, Rahim A, Ahmad P, et al. Prosthodontics dental materials: From conventional to unconventional. *Mater Sci Eng C.* 2020 Jan 1;106:110167.
4. Das G, Banerjee S, Chakraborty A, Pal TK. A study on the resistance at bone-implant interface during implant insertion in a cadaver goat jaw model. *J Int Clin Dent Res Organ.* 2016 Dec;8(2):120.
5. Al-Quran FA, Al-Ghalayini RF, Al-Zu'bi BN. Single-tooth replacement: factors affecting different prosthetic treatment modalities. *BMC Oral Health.* 2011 Dec 21;11:34.
6. Das G, Pal T K, Mahata A. Severely atrophied jaws: A case report of full mouth rehabilitation using basal and cortical implants. *IP Int J Periodontol Implantol.* 2020 Dec 28;3(4):143-6.
7. Katranji A, Misch K, Wang HL. Cortical bone thickness in dentate and edentulous human cadavers. *J Periodontol.* 2007 May;78(5):874-8.
8. Wang SH, Shen YW, Fuh LJ, Peng SL, Tsai MT, Huang HL, et al. Relationship between Cortical Bone Thickness and Cancellous Bone Density at Dental Implant Sites in the Jawbone. *Diagnostics.* 2020 Sep 17;10(9):710.
9. Ghalaut P, Shekhawat H, Meena B. Full-mouth rehabilitation with immediate loading basal implants: A case report. *Natl J Maxillofac Surg.* 2019;10(1):91-4.
10. Ali SM, Othman KS, Samad AA, Mahmud PK. Comparison between basal and conventional implants as a treatment modality in atrophied ridges. 2019 Sep 30;38(2):48-54.
11. Todi A, Singh MK, Kayal S, Das G, Chakraborty A. Assessment of insertion force for the placement of cortical implants in various anatomic sites in dried human skulls. *J Indian Soc Periodontol.* 2022;26(6):544-51.
12. Tettamanti L, Andrisani C, Bassi Ma, Vinci R, Silvestre-Rangil J, Tagliabue A. Immediate loading implants: review of the critical aspects. *Oral Implantol.* 2017 Sep 27;10(2):129-39.
13. Ihde S. Indications and Treatment Modalities with Corticobasal Jaw Implants. *Ann Maxillofac Surg.* 2019;9(2):379-86.