

“Analysis Of Correlation Of Fine Needle Aspiration Cytology With Histopathology Finding In Thyroid Lesion”

Dr. karthikeyan^{1*}, Dr. pratheep karthick², Dr. Jahid Husain S³, Dr. Radhakrishnan nair⁴, Prof. Dr. senguttuvan⁵

^{1*} Assistant Professor, Acs Medical college Hospital,

² Assistant Professor, Acs Medical college Hospital.

³ Assistant Professor, Acs Medical college Hospital.

⁴ Postgraduate, Acs medical college Hospital

⁵ Professor, Acs Medical college Hospital.

KEYWORDS

Thyroid Lesion,
FNAC,
Histopathology

Background and objectives:

Fine-needle aspiration cytology (FNAC) is currently employed in evaluating thyroid nodules which harbour malignancy. Fine-needle aspiration cytology is of pivotal diagnostic importance for clinicians in evaluating thyroid nodules and aids in preventing unindicated thyroid surgeries. Studies across the globe have evaluated and compared FNAC (with the Bethesda system of scoring) and histopathology assessment of the thyroid lesions with differing outcomes. Multiple studies from across the globe as well as India have tried to compare the two modalities. In order to garner specific insights on role of FNAC versus histopathology in patients with suspected thyroid swellings visiting our institute for management, we decided to conduct this study. The study is expected to contribute to the limited literature focussing on this domain in the subsets of Indian populations catered to at our center.

Materials and Methods:

The study was done at the Department of Surgery in the ACS medical college and hospital, Chennai. Data of 50 patients who presented to the department with thyroid swellings due to various causes was included in the analysis. An FNAC was performed and subsequently histopathological evaluation was done to assess the diagnosis of the thyroid disorders. A diagnostic accuracy assessment of FNAC vs histopathology was done.

Results: In the current study, it was seen that histopathology and FNAC **corelated highly** in terms of diagnosis of various thyroid lesions. Of the 41 cases identified as colloid goitre on FNAC, 39 were confirmed as accurate by the histopathology (95.12%). In terms of the malignant causes, high degree of agreement was seen for follicular neoplasm but only half the cases of papillary carcinoma were confirmed by histopathology suggesting some false positive rate for papillary CA on FNAC. Overall, there was a high degree of corelation (90% concordance) between the findings of FNAC and the histopathology. An assessment of the **benign vs malignant lesions** was seen done basis the FNAC and histopathology findings. 48 patients (96%) were accurately identified as benign or malignant by the FNAC as confirmed by the histopathology later on. 2 patients were seen to have a mismatch in terms of FNAC and histopathology findings. The results were significant statistically with a P value of <0.0001. The sensitivity and specificity of FNAC was seen to be **83.33%** and **97.73%**. The PPV and NPV for FNAC was **83.33%** and **97.73%**. The overall accuracy of FNAC was **96%**.

Conclusion:

The study was able to conclude that FNAC was a very useful modality for the diagnosis and management of the thyroid swelling. FNAC was seen to have very high accuracy in terms of characterisation of the thyroid swelling. The sensitivity and specificity of FNAC was seen to be 83.33% and 97.73%. The PPV and NPV for FNAC was 83.33% and 97.73%. The overall accuracy of FNAC was 96%. There was a high degree of corelation (90% concordance) between the findings of FNAC

and the histopathology. The findings of this study were in line with the major published literature in this domain both nationally and internationally

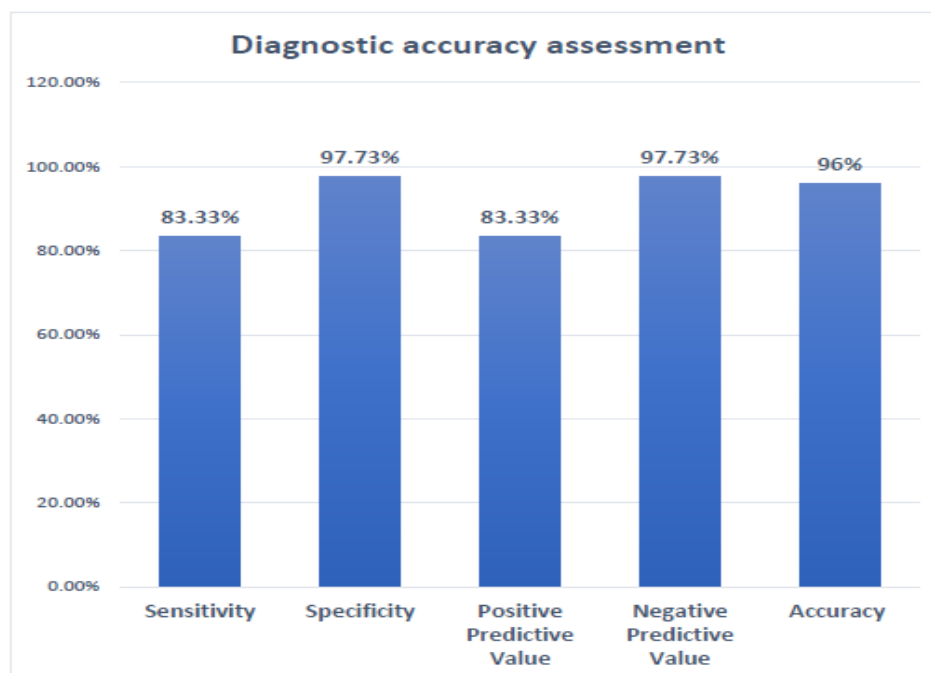
Introduction

Fine-needle aspiration cytology (FNAC) is currently employed in evaluating thyroid nodules which harbour malignancy. Fine-needle aspiration cytology is of pivotal diagnostic importance for clinicians in evaluating thyroid nodules and aids in preventing unindicated thyroid surgeries (9). Tysome JR et al 2009 (10) showed that when combined with the Bethesda system for reporting thyroid cytopathology (TBSRTC), FNAC provides a more robust, reliable, and cost-effective diagnostic outcome. However, FNAC has some disadvantages like having false negative rates and role in indeterminate cytology thyroid nodules (11). Multiple studies from across the globe as well as India have tried to compare the two modalities. In order to garner specific insights on role of FNAC versus histopathology in patients with suspected thyroid swellings visiting our institute for management, we decided to conduct this study. The study is expected to contribute to the limited literature focussing on this domain in the subsets of Indian populations catered to at our center.

Study flow –

1. All the patients presenting with thyroid swelling were screened for an inclusion and exclusion criteria.
2. All patients meeting the inclusion criteria and willing to give the written informed consent were included in the study.
3. A baseline demographic and clinical parameter assessment using a pre-defined proforma was done in terms of age, gender, clinical compliant, final diagnosis, clinical examination and investigational findings like USG, FNAC assessment.
4. Standard operating procedure was followed for evaluation and management of thyroid swelling.
5. An assessment of the various thyroid swellings was done using the FNAC and histopathology.
6. A corelation of the FNAC findings was done with the histopathology as gold standard investigation. A diagnostic assessment in terms of sensitivity, specificity, PPV and NPV was done along with the accuracy assessment.
7. An analysis of the observations was done using the statistical analysis plan laid out below.

Diagnostic Accuracy Assessment



Histopathology diagnosis

Histopathology diagnosis	Number	Percentage
Adenomatous goitre	1	2%
Anaplastic CA	1	2%
Colloid goitre	40	80%
Follicular neoplasm	1	2%
Papillary CA	4	8%
Thyroiditis	3	6%

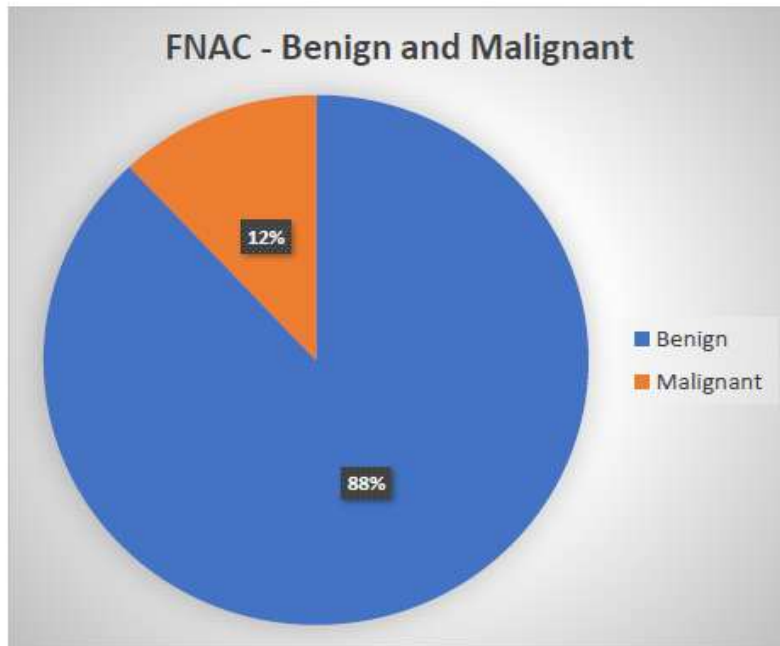
FNAC Diagnosis

FNAC diagnosis	Number	Percentage
Adenomatous goitre	1	2%
Colloid goitre	41	82%
Follicular neoplasm	1	2%
Medullary CA	1	2%
Papillary CA	4	8%
Thyroiditis	2	4%

FNAC – Benign and Malignant classification

FNAC	Number	Percentage
Benign	44	88%
Malignant	6	12%

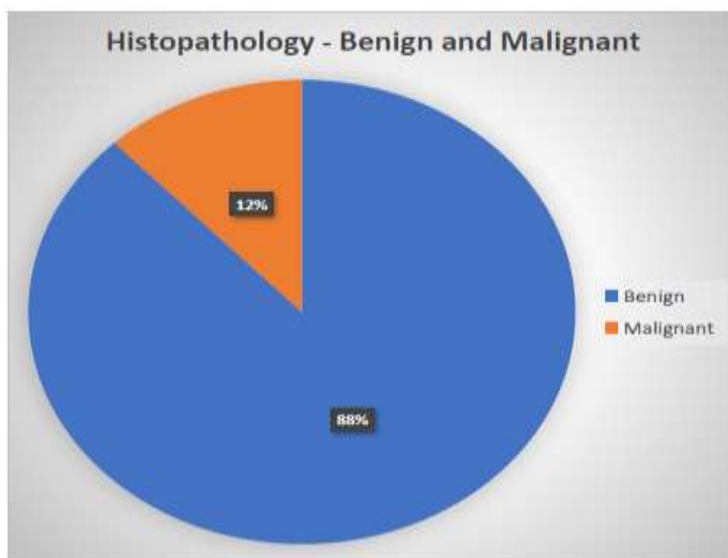
FNAC – Benign and Malignant classification



Histopathology – Benign and Malignant classification

Histopathology	Number	Percentage
Benign	44	88%
Malignant	6	12%

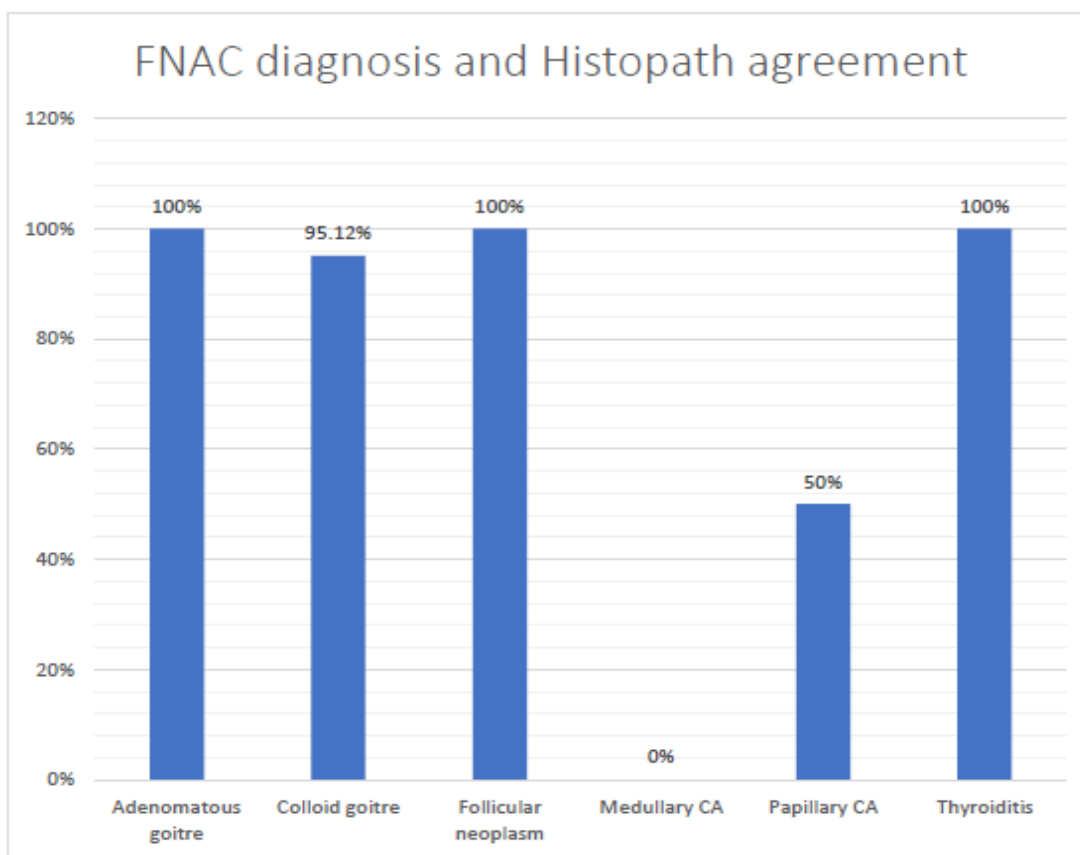
Histopathology – Benign and Malignant classification



Benign and Malignant – correlation

Histopathology and FNAC correlation	Histopathology	
	Malignant	Benign
FNAC		
Malignant	5	1
Benign	1	43

FNAC and histopathology confirmation



Discussion

FNAC and histopathology are two important diagnostic modalities for the evaluation and management of thyroid lesions. To further assess and evaluate the role of these in patients with thyroid lesions, we conducted this study. The study was done at the Department of Surgery in the ACS medical college and hospital, Chennai. Data of 50 patients who presented to the department with thyroid swellings due to various causes was included in the analysis. An FNAC was performed and subsequently histopathological evaluation was done to assess the diagnosis of the thyroid disorders. A diagnostic accuracy assessment of FNAC vs histopathology was done. A summary of the major findings has been provided below –

1. The average age of patients included in the study was 41.40 ± 12.38 years with a range of 21-64 years.
2. The median age was 43 years with an interquartile range of 30-51 years. Most of the patients were seen to be in the age group of 41-60 years (50%) followed by 20-40 years (46%). 2 patients were also seen to be in the age group of 60+ years.
3. There was a female preponderance in the study as seen by the fact that 70% patients were females.

4. The average BMI of patients included in the study was 21.26 ± 1.99 kg/m² with a range of 18.06-24.51 kg/m². The median BMI was 20.81 kg/m² with an interquartile range of 19.95-23.25 kg/m².
5. Most of the patients were seen to present with neck swelling (84%) followed by 4 patients age with dysphagia and hoarseness (8%).
6. The Bethesda classification based assessment of the patients' lesions showed that most of the patients had a Bethesda grade 2 (74%) suggestive of benign lesions

1 Bethesda grade 4 and 5 suggestive of suspected malignancy (8%) or confirmed malignancy (6%).

FNAC Based Findings Based on the FNAC, colloid goitre was the most common diagnosis (82%) followed by papillary CA seen in 4 patients (8%). 2 patients were seen to have thyroiditis (4%) and one patient each were seen to have adenomatous goitre, follicular neoplasm and medullary CA.

At an overall level, it was seen that 44 patients (88%) were seen to have benign lesions while 12% patients had a malignant or suspected malignancy as per the FNAC.

Histopathology based findings Based on the histopathology also, colloid goitre was the most common diagnosis (80%) followed by papillary CA seen in 4 patients (8%). 3 patients were seen to have thyroiditis (6%) and one patient each were seen to have adenomatous goitre, follicular neoplasm and anaplastic CA.

At an overall level, it was seen that 44 patients (88%) were seen to have benign lesions while 12% patients had a malignant or suspected malignancy as per the histopathology assessment.

Diagnostic accuracy assessment – In the current study, it was seen that histopathology and FNAC correlated highly in terms of diagnosis of various thyroid lesions.

Of the 41 cases identified as colloid goitre on FNAC, 39 were confirmed as accurate by the histopathology (95.12%).

In terms of the malignant causes, high degree of agreement was seen for follicular neoplasm but only half the cases of papillary carcinoma were confirmed by histopathology suggesting some false positive rate for papillary CA on FNAC.

Overall, there was a high degree of correlation (90% concordance) between the findings of FNAC and the histopathology.

An assessment of the benign vs malignant lesions was seen done basis the FNAC and histopathology findings. 48 patients (96%) were accurately identified as benign or malignant by the FNAC as confirmed by the histopathology later on. 2 patients were seen to have a mismatch in terms of FNAC and histopathology findings. The results were significant statistically with a P value of <0.0001 .

The sensitivity and specificity of FNAC was seen to be 83.33% and 97.73%. The PPV and NPV for FNAC was 83.33% and 97.73%. The overall accuracy of FNAC was 96%.

The study was able to conclude that FNAC has a very high accuracy and diagnostic parameters for the thyroid swellings. This was positively correlated with the histopathological findings. The findings were in line with the major published literature in this domain

Conclusion

The study was able to conclude that FNAC was a very useful modality for the diagnosis and management of the thyroid swelling. FNAC was seen to have very high accuracy in terms of characterisation of the thyroid swelling. The sensitivity and specificity of FNAC was seen to be 83.33% and 97.73%. The PPV and NPV for FNAC was 83.33% and 97.73%. The overall accuracy of FNAC was 96%. There was a high degree of correlation (90% concordance) between the findings of FNAC and the histopathology. The findings of this study were in line with the major published literature in this domain both nationally and internationally. Larger studies with multicentric study designs would be needed to further validate the findings of this study.

References

1. Allen E, Fingeret A. Anatomy, Head and Neck, Thyroid. [Updated 2023 Jul 24]. In: StatPearls [Internet]. Treasure Island (FL): StatPearls. Publishing; 2024 Jan-.
2. Fitzpatrick TH, Siccardi MA. StatPearls [Internet]. StatPearls Publishing; Treasure Island (FL): Apr 8, 2023. Anatomy, Head and Neck: Adam's Apple.

3. Can AS, Rehman A. Goiter. [Updated 2023 Aug 14]. In: StatPearls [Internet]. Treasure Island (FL): StatPearls Publishing; 2024 Jan-.
4. Knobel M. Etiopathology, clinical features, and treatment of diffuse and multinodular nontoxic goiters. *J Endocrinol Invest.* 2016 Apr;39(4):357-73
5. Gaitan E, Nelson NC, Poole GV. Endemic goiter and endemic thyroid disorders. *World J Surg.* 1991 Mar-Apr;15(2):205-15.
6. Yildirim Simsir I, Cetinkalp S, Kabalak T. Review of Factors Contributing to Nodular Goiter and Thyroid Carcinoma. *Med Princ Pract.* 2020;29(1):1-5.
7. Zheng R, Rios-Diaz AJ, Thibault DP, Crispo JAG, Willis AW, Willis AI. A contemporary analysis of goiters undergoing surgery in the United States. *Am J Surg.* 2020 Aug;220(2):341-348
8. Ullah I, Asif M, Alam N, Ali S, Haq IU, Khan I. Study on the Prevalence of Goiter and Associated Factors Among Hospitalized Patients of District Timergara, Dir Lower Pakistan. *Biomedical Journal of Scientific & Technical Research.* 2022;41(2):32458-63.
9. Cibas ES, Baloch ZW, Fellegara G, LiVolsi VA, Raab SS, Rosai J, et al. A prospective assessment defining the limitations of thyroid nodule pathologic evaluation. *Ann Intern Med.* 2013;159:325–332.
10. Tysome JR, Chandra A, Chang F, Puwanarajah P, Elliott M, Carroll P, et al. Improving prediction of malignancy of cytologically indeterminate thyroid nodules. *Br J Surg.* 2009;96:1400–1405.