


# COMPARISON OF DYNAMIC CONTRAST- ENHANCED MAGNETIC RESONANCE IMAGING, MAMMOGRAM, AND ULTRASOUND IN THE ESTIMATION OF TUMOR SIZE IN BREAST CANCER PATIENTS UNDERGOING NEOADJUVANT.



Bassam Alshammari, MSc<sup>1</sup>✉, Paul Ganguly, MBBS, MD, FACA<sup>2</sup>, Abeer Almousa, MD<sup>3</sup>, Fahad Mhahreeth, MD<sup>4</sup>, Majed Alshammari<sup>5</sup> and Kholoud Alsulaimani.<sup>6</sup>

<sup>1</sup>Chairman of hospitals accreditation unit, Ministry of Health, Al Faisal University, Riyadh, Saudi Arabia.

<sup>2</sup>Professor and Chairman College of Medicine Al Faisal University, Riyadh, Saudi Arabia.

<sup>3</sup>Consultant breast imaging and the chairman of radiology department King Fahad Medical City (KFMC), Riyadh, Saudi Arabia.

<sup>4</sup>Medical Director at Royal Medical Complex, Dammam, Saudi Arabia.

<sup>5</sup>Radiology Specialist, Radiology Department, King Khalid University Hospital, Riyadh, Saudi Arabia.

<sup>6</sup>Radiology Specialist, Radiology Department, King Fahad Medical City (KFMC), Riyadh, Saudi Arabia.

## ABSTRACT

### Objective

To specifically compare how DCE-MRI, MG, and U/S To find out which of the machines determine the accurate size of the tumor for patients receiving neoadjuvant treatment for breast cancer.

### Methods

This study used retrospective reports Forty-four Patient women diagnosed breast cancer from King Fahad Medical City in Radiology Department at Riyadh from October to December 2021 to assess the use of an advanced Dynamic contrast-enhanced magnetic resonance imaging system (DCE-MRI system), mammogram (MG), and ultrasound (US), and to confirm whether they accuracy and integration one another in breast cancer size analysis.

### Results

The results showed no significant difference in the tumor size according to the radiographic system of each case pre-chemotherapy, where the mean size of the tumor was 9.95, 8.64, and 11.17 cm<sup>2</sup> through the MG, US, and MRI techniques, respectively. Also, the statistical treatment of data showed the P-value associated with the f-test was Greater than 0.05. In addition, the results showed there is no significant difference in the tumor size according to the radiographic system of each case post-chemotherapy.

### Conclusion

Received 25 June 2022

Revised 3 July 2022

Accepted 20 July 2022

Published 23 July 2022

#### Corresponding Author

Bassam Alshammari, MSc, Email: B.assamaljassar17@gmail.com

Copyright: © 2022 The Author(s).

This is an open access article distributed under the terms of the Creative Commons Attribution License, which permits unrestricted use, distribution, and reproduction in any medium, provided the original author and source are credited.

eISSN: 1658-8959



After analysis 44 reports of different women diagnosed with breast cancer and scanned using DCE-MRI, MG, and U/S. DCE-MRI's predictive response evaluation can be used to determine the efficacy of chemotherapy in the early assessment stage.

#### الملخص

#### الهدف

الهدف من هذه الدراسة تحديداً هو مقارنة كلاً من الرنين المغناطيسي وتصوير الأشعة بالماموغرام, وتصوير الموجات الصوتية لمعرفة أي من أجهزة الأشعة التي تحدد حجم الورم بشكل دقيق للمرضى الذين يتلقون العلاج الكيميائي لسرطان الثدي.

#### المنهجية

تم الاستخدام بهذه الدراسة تقارير بأثر رجعي لـ أربعة وأربعون امرأة مشخصه بسرطان الثدي بمدينة الملك فهد الطبية بالرياض بقسم الأشعة من أكتوبر حتى ديسمبر 2021 وذلك لتقييم استخدام كلاً من التصوير الديناميكي بالرنين المغناطيسي لتصوير الثدي (DCE\_MRI) وتصوير الماموغرام وكذلك التصوير بالموجات الصوتية وذلك للتأكد من دقة وتكامل هذه الفحوصات لبعضها البعض في تحليل حجم الورم.

#### النتائج

أظهرت النتائج عدم وجود فرق في حجم الورم حسب نظام التصوير الإشعاعي لكل حالة قبل العلاج الكيميائي حيث كان متوسط حجم الورم 9.95 و 8.64 و 11.17 سم 2 من خلال اجهزه الماموغرام والرنين المغناطيسي وكذلك التصوير بالموجات الصوتي على التوالي كما أظهرت المعالجة الإحصائية للبيانات أن قيمة P المرتبطة باختبار f كانت أكبر من 0.05 كما أظهرت النتائج عدم وجود فرق في حجم الورم حسب نظام التصوير الإشعاعي لكل حالة بعد العلاج الكيميائي.

#### الخلاصة

بعد تحليل عينة 44 من الإناث تم تشخيصها بالإصابة بسرطان الثدي وتم الفحص بكلاً من التصوير الديناميكي بالرنين المغناطيسي وتصوير أشعة الماموغرام وتصوير الموجات الصوتية, يمكن ان يساعد التصوير بجهاز الرنين المغناطيسي استخدام تقييم الاستجابة التنبئية للتصوير الديناميكي بالرنين المغناطيسي للثدي لتحديد كفاءة العلاج الكيميائي في مرحلة التقييم المبكر.

**Keywords:** Magnetic Resonance Imaging, DCE-MRI, Mammogram, MG Ultrasound US, Breast Cancer, Tumor Biopsy, Chemotherapy, Radiology Diagnostics

## 1. INTRODUCTION

Dynamic enhanced contrast magnetic resonance imaging (DCE-MRI), mammogram (MG), and ultrasound (US) are some of the common high-power imaging systems available in Radiology departments for various clinical diagnoses and patient assessments. Magnetic resonance imaging (MRI) has high-resolution power to identify physiological and metabolic processes, provide information about the pathophysiological state, and detect the severity of diseases and disorders [1, 2].

Accurate measurement of breast cancer tumors is paramount to its staging and determination of patient management strategies. Tumor size evaluation provides an avenue for the proper evaluation of breast cancer, thereby ensuring the correct detection and control

of the disease. Many of the pathological analyses conducted as part of breast cancer evaluation involve the use of MG and US. These techniques assist in the reliable screening of different stages of cancer development, including high-risk cancer groups. MRI has been proven reliable in breast cancer size assessment over the years. [1] It is considered to be sensitive and has shown potential in detecting and examining mammographically occult and mysterious lesions in dense breasts, suspected multifocal disease, size discrepancy, integrity evaluation, lobular carcinomas, and constant treatment responses [2].

MRI has a high sensitivity, which makes it useful for assessing lobular carcinomas or carcinomas less than 10mm [3]. It can also detect the state of triple-negative breast cancers (TNBC), which is particularly difficult to detect and analyze due to the lack of human epidermal growth factor receptor 2 (HER2) and amplification in progesterone or estrogen receptors' expression [4]. MRI displays a very strong predictive ability, even with the tumor size from changing previous tumor characterization with the topoisomerase I inhibitors used.

The tumor size evaluation using MRI in patients undergoing neoadjuvant chemotherapy showed 100% sensitivity, 56% specificity, 38% positive predictive value, and 100% negative predictive value [5]. The MRI system can help determine the tumor category, that is, whether it is a benign tumor or if it has metastasized. It can also determine the best management procedure, including surgery or chemotherapy [6]. MRI biomarkers can predict breast cancer severity and aggressiveness, presented as a constant rate of extracellular-extravascular space ( $K_{ep}$ ) and volume transfer constant ( $K_{trans}$ ) [7].

Many medical establishments extract breast tumors manually on a parametric map, showing the maximum slope increase (MSI) of tumor-initiating cells (TIC). This operator-dependent technique has demonstrated a high sensitivity, with a moderate specificity level for benign tumors compared to malicious tumors. Many Studies have developed modern methods for analyzing TIC to improve specific lesion detection processes.

TIC, signal form, and morphological and dynamic characteristics are all considered part of an efficient technique for evaluating the malignancy of a potential lesion connected with the angiogenesis range. An upslope with a rapid washout pattern for TIC is a malignancy anticipation marker [8]. Multiple classifier systems (MCS) use morphological and dynamic characteristics for breast cancer classification, but they are yet to be used with DCE-MRI, despite the age-long concept that integrates several classifier [9]. The performance tends to be lower when the analyzed data include textural kinetic and morphological characteristics.

## **2. OBJECTIVES**

This study focused on comparing how DCE-MRI, MG, and U/S estimate tumor size in breast cancer patients undergoing neoadjuvant chemotherapy. The study also focused on the relative accuracy of the various detection methods while comparing each method with the gold standard of surgical pathology to estimate the correlation between the results for each group and determine the statistically significant differences between the radiological imaging reports based on DCE-MRI, MG, and US. A comparison between histological biopsy results of cancer tissues and radiological imaging reports from DCE-MRI, MG, and US was also performed.

## **3. METHODOLOGY**

### **3.1 Study Design**

This research is a retrospective, cross-sectional study that focuses on identifying the quality and efficacy of DCE-MRI, MG, and US in breast cancer staging.

### **3.2 Radiological Procedure**

The radiological procedure to scan the breast tumor was performed on 44 different women (n = 44) using MG, US and DCE-MRI 1.5T Magnetom (Siemens, Erlangen, Germany) coil 18-channel bilateral breast was used for imaging and standard software was used to analyze the results. The patients were examined in the prone position at the iso-center of the magnet, with the breasts hanging into the breast coil. The contrast agent was injected via a previously inserted long line into the cubital vein. Once the patient was in position in the magnetic field, 0.1 mmol/kg of contrast agent was injected at a rate of 2–3 ml/s, followed by 20 ml saline flush at the same flow rate.

### **3.3 Population and Study Sample**

This research was a retrospective study using archived radiology data from two years ago at King Fahad Medical City in the Kingdom of Saudi Arabia.

Forty-four female patients, with a mean age of 46 years, were diagnosed as possibly suffering from breast cancer at different stages. We assessed the type and metastatic case of breast cancer and evaluated the effect of tumor response to neoadjuvant chemotherapy using DCE-MRI, MG, and US.

All 44 patients also used the laboratory analysis of histological biopsy of breast cancer tissue and DCE-MRI, MG and U/S.

### 3.4 Study sample, data sources and management

The present study depended on physicians' radiological reports of DCE-MRI system Mammogram and Ultrasound scanning results (n=44). All these DCE-MRI system Mammogram and Ultrasound results of radiological scanning reports were found in the archive department of King Fahad Medical City 2 years ago.

In addition, the present study depended on the histology department's reports of cancer tissue analysis after biopsy methods to collect the tumor tissues or the possibility of tumor tissues. All the histology biopsies results arrived from the archive department of King Fahad Medical City 2 years ago (from October to December 2021).

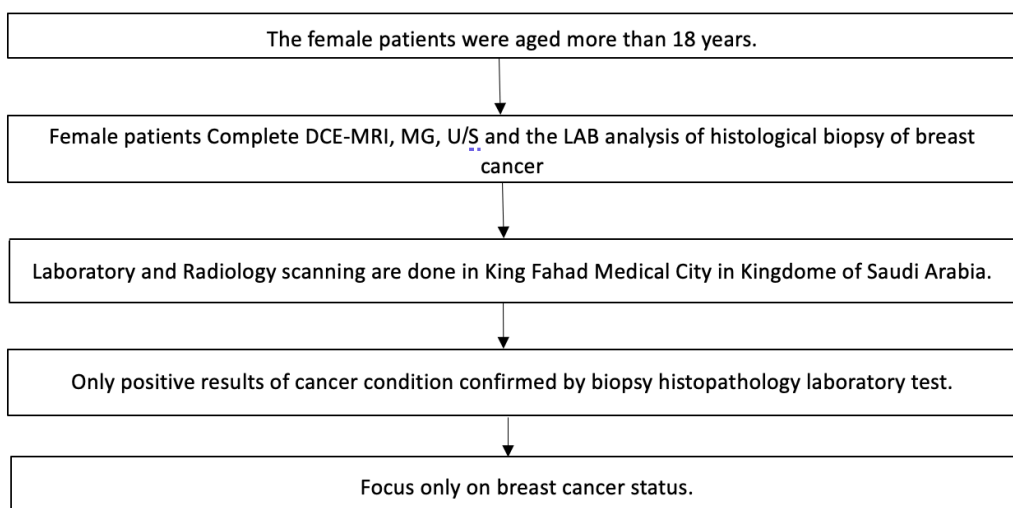


Figure 1 Flowchart of patients' inclusion criteria.

#### 3.4.1 Exclusion

Females aged less than 18 years old and the radiological analysis is not used in the DCE-MRI system, even if it is used MRI system Mammogram and Ultrasound. In addition, the patients with cancers other than breast cancer, Negative results of biopsy test for breast, all laboratory and radiology scanning are not done in a King Fahad Medical City in Kingdom of Saudi Arabia.

The present study depended on physicians' radiology reports of DCE-MRI system Mammogram and Ultrasound scanning results (n=44). All these DCE-MRI system MG and U/S results of radiological scanning reports were found in the archive department of King Fahad Medical City 2 years ago.

In addition, the present study depended on the histology department's reports of cancer tissue analysis after biopsy methods to collect the tumor tissues or the possibility of tumor tissues. All the histology biopsies results arrived from the archive department of King Fahad Medical City 2 years ago (from October to December 2021).

All the magnetic resonance imaging reports from the radiological department on diagnosis of breast cancer assessment, spanning three months, were collected from the King Fahad Medical City archived. In addition, all biopsy reports in the diagnosis or assessment of breast cancer tissues are collected by doctors or physicians in laboratory departments.

The collected data were separated according to top the departments (laboratory and Radiology departments), same as Radiology imaging reports of the DCE-MRI system MG and U/S (n=44) from each data collection group as described above .

### **3.5 Data Analysis Strategies**

Data were analyzed by using the statistical package of social science (SPSS) version 25 and the radiographic and specialist assessment, as Data coding and

#### **3.5.1 Statistical analysis**

we used the statistical analysis methods ,statistical package of social science SPSS (IBM Statistics Desktop 5725-A54 version 25) to compare histology biopsy reports results and Radiology reports of DCE-MRI system Mammogram and Ultrasound scanning results such as the Bonferroni test and one-way analysis of variance (ANOVA) test between and within groups.

#### **3.5.2 Ethics and Human Subjects' Issues**

The study was obtained after approval from the Saudi Arabia health research ethics committee, which is part of the national institute for medical research and follows the Helsinki instructions.

As recommended by scientific forums, the researcher is committed to honesty and honestly presents the research data, methods, procedures, and results. The researchers were careful to avoid any falsifications of data misrepresentation. Ethical approval was retrieved from all patients before the start of experiments, where they were informed that all data were to be used for research purposes only.

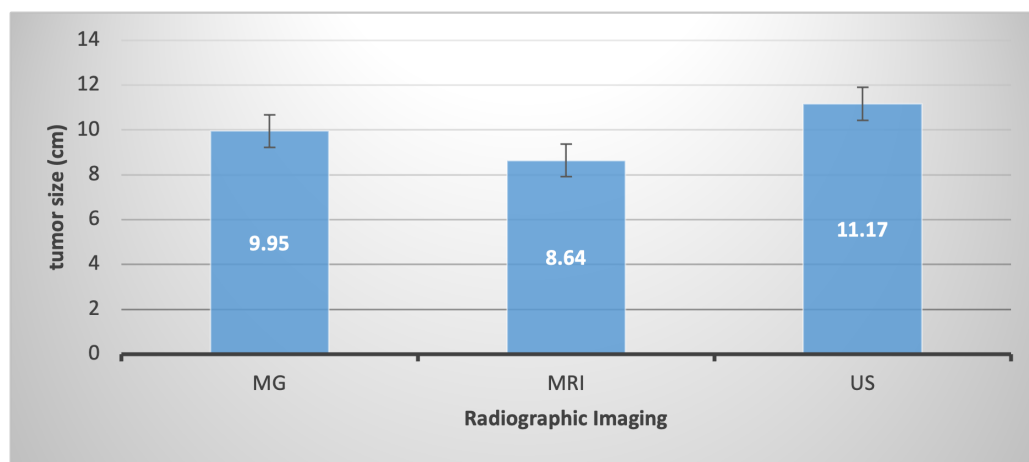
#### 4. RESULTS

The current study was conducted on 44 (n=44) female participants aged 46 (23±20 years) with breast cancer confirmed by laboratory analysis of biopsy samples. According to Saudi management protocol, each case underwent three main radiographic imaging: Mammography (MG), Magnetic resonance imaging (MRI), and Ultrasound (US) within 7 to 21 days. The patients were treated with anticancer drugs for six months and repeated the radiographic assessment for each breast cancer state. The clinical assessment showed that 86.9% of cases were diagnosed with invasive ductal carcinoma state of breast cancer.

The current study compared MG, MRI, and US at pre-and post-chemotherapy of each case (6 months). The results showed no significant difference in the tumor size according to the radiographic system of each case pre-chemotherapy, where the mean size of the tumor was 9.95, 8.64, and 11.17 cm<sup>2</sup> through the MG, US, and MRI techniques, respectively. Also, the statistical treatment of data showed the P-value associated with the f-test was Greater than 0.05 (Table 1; Figure 1).

**Table 1** Statistical treatment of tumor size results among breast cancer cases for various radiological techniques before chemotherapy

Radiographic system	N	Mean (cm <sup>2</sup> )	Std. D	F-test	P-value
Mammogram (MG)		9.95	7.74		
Ultrasound (US)		8.64	13.58		
Magnetic Resonance Imaging (MRI)		11.17	8.54		



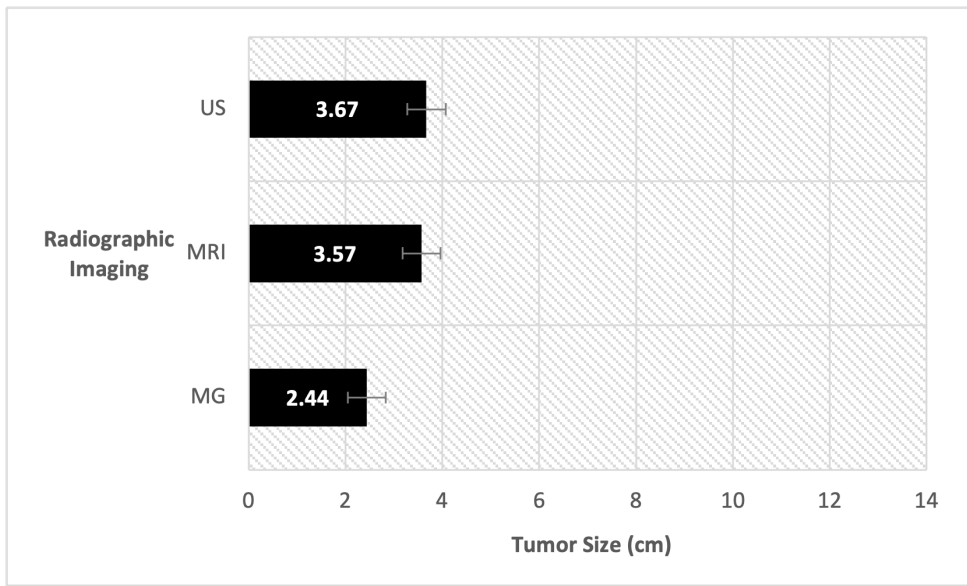
**Figure 2** Comparing MG, MRI, and US imaging results of tumor size among breast cancer cases before chemotherapy.

In addition, the results showed there is no significant difference in the tumor size according to the radiographic system of each case post-chemotherapy, where the mean

size of the tumor was 2.44, 3.67, and 3.57 cm<sup>2</sup> through the MG, US, and MRI techniques, respectively. Also, the statistical treatment of data showed the P-value associated with the f-test was more than 0.05 (Table 2; Figure 3).

**Table 2** Statistical treatment of tumor size results among breast cancer cases for various radiological techniques after chemotherapy for six months.

Radiographic system	N	Mean (cm <sup>2</sup> )	Std. D	F-test	P-value
Mammogram (MG)	46	2.44	4.667	0.591	0.555
Ultrasound (US)		3.67	8.811		
Magnetic Resonance Imaging (MRI)		3.57	3.194		



**Figure 3** Comparing MG, MRI, and US imaging results of tumor size among breast cancer cases after chemotherapy.

## 5. DISCUSSION

Cancer and lesion size measurement using Breast Imaging Reporting and Data System is a popular method for assessing the effectiveness of various investigation methods, like MRI, MG, breast US, and mammography. The procedure considers the morphological lesion and uses it as a ground for medical biopsy. While investigation via MRI and the like

has shown effectiveness for breast cancer size investigation, many professionals still prefer breast biopsies for making breast cancer diagnoses [10].

Breast cancer detection and control can only be done effectively if there is a proper disease evaluation. The standard pathological assessment reliable for high-risk cancer groups screening today is imaging, which can be done via mammography and Ultrasound (US). Upon using the MRI system for breast cancer diagnosis, we obtained a 100% sensitivity and 56% specificity from MRI. This is close to the expected specificity value, showing that MRI is the best investigative technique for deciding if patients with benign and metastatic tumors will or will not need surgical intervention [6]. We can predict the severity and aggressiveness of breast cancer tumors using MRI biomarkers as constant rate of extracellular-intravascular space ( $K_{ep}$ ) and Volume transfer constant ( $K_{trans}$ ) via the information obtained on breast cancer proliferation and tumor angiogenesis [7].

The use of neoadjuvant chemotherapies is increasing for treating locally advanced breast cancer. It, therefore, makes it possible for surgeons to carry out more breast-conserving surgical procedures since it shrinks the larger tumors. A specific and sensitive identification method for neoadjuvant chemotherapy tumor responses is required since there is an earlier chance of a highly effective regimen consequent of the early recognition of non-responders. This helps to reduce the drugs' toxicity and optimize surgery timing. The absence of response to a given regime in-vivo can guide the use of additional chemotherapy following a surgical procedure. The gold standard in this work is physical or clinical examination. It assisted in the assessment of clinical response to chemotherapy. The study above discovered that the reliability and value of clinical examination in predicting the size of residual tumors following the administration of neoadjuvant chemotherapy is limited [11].

In inflammatory or locally advanced breast cancer, the examination will have to consider the infiltrating action of the tumor growth and the density of the breast tissue; both factors prevent the accurate evaluation of tumor size and rate of response following neoadjuvant chemotherapy. The tumor imaging can be obscured by the dense breast tissue on mammography, preventing the convenient study of the tumor size.

The correlation of our predictions made on an MRI basis is better with pathological residual size and pathological response following neoadjuvant chemotherapy compared to the estimation based on clinical examination, sonography, or mammography. It is not easy to interpret the results published in studies on neoadjuvant chemotherapy for assessment. [12] MRI underestimated more frequently than overestimated residual disease. MRI also underestimated residual disease in about 23% of the patients involved in the study.

Neoadjuvant chemotherapy has several advantages, and its use has been popular in breast cancer management in recent times [12]. The drug has the primary role of shrinking

the tumor and permitting surgeons to carry out surgery for conserving the breast, especially in patients diagnosed with advanced breast cancer [13]. Healthcare professionals can trust neoadjuvant chemotherapy for the micro metastatic disease early treatment, including the biological markers study towards predicting tumor response. Chemotherapeutic agents' effectiveness in treating potential metastatic disease and primary breast cancer may be enhanced due to tumor neovascularity.

If the patient receives chemotherapy before surgery with tumor vascularity remaining intact, it will be easier for the chemotherapeutic agents to reach the tumor and enact more effectiveness.

Locally advanced breast cancer (LABC) neoadjuvant chemotherapy can improve the tumor's resectability rate, increasing the patient's survival rate compared to the survival rate of patients who undergo only surgery [14]. Pathological complete response is significant clinically because of its association with decreased recurrence risk and improved long-term prognosis. Decisions regarding the right type of surgery, current regimens continuation, and surgery timing depend on the clinical and radiological assessment of the residual tumor size while the neoadjuvant chemotherapy is underway [15].

Many studies conclude that sonography, mammography, and physical examination offer suboptimal lesion extent evaluation, not permitting the residual tumor size or pathological response accurate assessment [16]. Sonography, mammography, and physical examination may be suitable for larger lesion detection of non-responders in LABC. However, their sensitivity is limited in responders having smaller residual lesions [17]. Patients that respond to neoadjuvant chemotherapy can record persistent calcification for mammography.

Several studies have been conducted on this subject matter, and they all concluded that MRI remains the most reliable residual disease evaluation technique once neoadjuvant chemotherapy is underway. Nevertheless, certain initial reports maintained that false-negative results were recorded frequently in breast cancer having a smaller volume [18]. Recent studies have increased MRI sensitivity tremendously, including lower enhancement thresholds, increased resolution, and reduced slice thickness used for minimizing residual disease underestimating. However, distinguishing between viable residual malignancy and fibrosis, necrosis & scarring is still difficult. Predicting accurate response following the commencement of neoadjuvant chemotherapy is also not easy, especially when it concerns responders.

The incidence of inflammatory breast cancer in patients on neoadjuvant chemotherapy is low, hence the limited number of studies conducted on it [19, 20]. Our study is focused on determining the relative accuracy of magnetic resonance imaging, mammography, and Ultrasound in tumor size prediction and the response of breast cancer to neoad-

juvant chemotherapy. We also compared our results with surgical pathology and the gold standard.

The study used retrospective reports to assess the use of an advanced magnetic resonance imaging system (DCE-MRI system) Mammogram, Ultrasound and target King Fahad Medical City, which has highly experienced radiologists and doctors, giving easy access to reliable data reports that make the outcome of the study trustworthy. The study compared the result from DCE-MRI, MG and U/S using histological biopsy laboratory methods with 100% accuracy.

The study confirms that MG, MRI, and U/S complement one another in breast cancer size analysis. It also compares the diagnostic capacity of the various techniques in assessing tumor size in patients with confirmed breast cancer who are currently undergoing neoadjuvant chemotherapy. The study showcased the contribution of several recent research studies to tumor size detection at the various stages of breast cancer management, spanning the various periods of neoadjuvant chemotherapy.

The study is the first to assess MRI-DCE efficacy at the King Fahad Medical City in Saudi Arabia and also the first to compare cancer histological biopsy to MRI-DCE analysis.

Nevertheless, we could not access up to two years' archived at King Fahad Medical City. We also could not collect all the results generated from magnetic resonance imaging for all breast cancer cases at the hospital. Also, not all breast cancer cases could undergo histological biopsy analysis and MRI-DCE. The doctors might recommend only positron emission tomography (PET) scanning or an analytical biopsy.

The advanced magnetic resonance imaging system is not present in all the radiological departments at the hospital.

Our study showed that neoadjuvant chemotherapy administration could reduce tumor size in breast cancer patients according to the analysis outcome using various techniques like MRI-DCE, mammography, and Ultrasound. Therefore, we recommend using these techniques to investigate, assess, and manage breast cancer lesions. We equally recommend the importance of a follow-up investigation using the various techniques before, during, and after chemotherapy to help determine if or not the patient can benefit from surgical intervention and when the surgical intervention can safely be implemented.

## 5.1 Future directions

We recommend further studies on why there is variability in the specific values obtained from the US system, MG, and MRI. We also recommend that further studies be conducted using modern computerized analysis methods to develop a more potent breast cancer management program for better outcome data. We also recommend that further studies focus

on investigating the US, MG, and MRI techniques that should be used in the medical and oncology fields for a better breast cancer analysis and how breast cancer relates to other diseases, like dermatology disorders and cardiovascular system disease.

## **6. CONCLUSION**

Prediction of residual tumor size and response made on MRI correlated better with the assessment of residual tumor size and response made upon disease detection than those made based on sonography, mammography, or clinical examination due to its sensitivity. Consequently, MRI's predicted response evaluation could bring up a relatively sensitive chemotherapy efficacy in early assessment.

## **CONFLICT OF INTEREST**

The authors declare that the research was conducted without any commercial or financial relationships that could be construed as a potential conflict of interest.

## **ACKNOWLEDGEMENTS**

N/A

## **REFERENCES**

- [1] Jethava A, Ali S, Wakefield D, Crowell R, Sporn J, Vrendenburgh J. Diagnostic accuracy of MRI in predicting breast tumor size: Comparative analysis of MRI vs histopathological assessed breast tumor size. *Conn Med.* 2015;79(5):261–268.
- [2] Therasse P, Arbuck SG, Eisenhauer EA, Wanders J, Kaplan RS, Rubinstein L et al. New guidelines to evaluate the response to treatment in solid tumors. European Organization for Research and Treatment of Cancer, National Cancer Institute of the United States, National Cancer Institute of Canada. *J Natl Cancer Inst.* 2000;92(3):205–221.
- [3] Khalil R, Osman NM, Chalabi N, Ghany A, E. Unenhanced breast MRI: could it replace dynamic breast MRI in detecting and characterizing breast lesions? *Egyptian Journal of Radiology and Nuclear Medicine.* 2020;51(1).
- [4] Heinisch M, Gallowitsch HJ, Mikosch P, Kresnik E, Kumnig G, Gomez I ; 2003,.

- [5] Youk JH, Son EJ, Chung J, Kim JA, Kim E. Triple-negative invasive breast cancer on dynamic contrast-enhanced and diffusion-weighted MR imaging: comparison with other breast cancer subtypes. *European Radiology*. 2012;22(8):1724–1758.
- [6] Fangberget A, Nilsen LB, Hole KH, Holmen MM, Engebraaten O, Naume B. Neoadjuvant chemotherapy in breast cancer-response evaluation and prediction of response to treatment using dynamic contrast-enhanced and diffusion-weighted MR imaging. *European Radiology*. 2010;21(6):1188–99.
- [7] Murray AD, Staff RT, Gilbert FJ, Miller ID, Payne S, Redpath TW. Dynamic contrast enhanced MRI of the axilla in women with breast cancer: comparison with pathology of excised nodes. *British Journal of Radiology*. 2002;75(891):220–228.
- [8] Li L, Wang K, Sun X, Wang K, Sun Y, Zhang G et al. Parameters of dynamic contrast-enhanced MRI as imaging markers for angiogenesis and proliferation in human breast cancer. *Med Sci Monit*. 2015;21:4324575–4324575.
- [9] Chang YC, Huang YH, Huang CS, Chang PK, Chen JH, Chang RF ; 2012,. Available from: <https://europepmc.org/article/MED/22245697>.
- [10] Zheng Y, Englander S, Baloch S, Zacharaki EI, Fan Y, Schnall MD ; 2009,.
- [11] Menezes G, Knuttel M, Stehouwer L, Pijnappel M, Bosch J. Magnetic resonance imaging in breast cancer: a literature review and future perspectives. *World J Clin Oncol*. 2014;5(2):61–70.
- [12] Helvie MA, Joynt LK, Cody RL, Pierce LJ, Adler DD, Merajver SD ; 1996,. Available from: <https://pubmed.ncbi.nlm.nih.gov/8596826/>.
- [13] Bonadonna G, Valagussa P, Brambilla C, Ferrari L, Moliterni A, Terenziani M. Primary chemotherapy in operable breast cancer: eight-year experience at the Milan Cancer Institute. *Journal of Clinical Oncology: Official Journal of the American Society of Clinical Oncology*. 1998;16(1):93–100.
- [14] Newman LA, Buzdar AU, Singletary SE, Kuerer HM, Buchholz T, Ames FC ; 2002,. Available from: <https://mdanderson.elsevierpure.com/en/publications/a-prospective-trial-of-preoperative-chemotherapy-in-resectable-br>.
- [15] Fisher B, Bryant J, Wolmark N, Mamounas E, Brown A, Fisher E. Effect of preoperative chemotherapy on the outcome of women with operable breast cancer. *J Clinical Oncology*. 1998;16:2672–85.
- [16] Peintinger F, Kuerer HM, Anderson K, Boughey JC, Meric-Bernstam F, Singletary SE. Accuracy of the combination of mammography and sonography in predicting

tumor response in breast cancer patients after neoadjuvant chemotherapy. *Annals of Surgical Oncology*. 2006;13(11):1443–1452.

- [17] Swain S, Sorace R, Bagley C, Danforth DJ, Bader J, Wesley M. Neoadjuvant chemotherapy in the combined modality approach of locally advanced nonmetastatic breast cancer. *Cancer Res*. 1987;47:3889–94.
- [18] Herrada J, Iyer R, Atkinson E, Sneige N, Buzdar A, Hortobagyi G. Relative value of physical examination, mammography, and breast sonography in evaluating the size of the primary tumor and regional lymph node metastases in women receiving neoadjuvant chemotherapy for locally advanced breast carcinoma. *Clin Cancer Res*. 1997;3:1565–1574.
- [19] Gilles R, Guinebretiere J, Toussaint C, Spielman M, Rietjens M, Petit J. Locally advanced breast cancer: contrast-enhanced subtraction MR imaging of response to preoperative chemotherapy. *Radiology*. 1994;191:633–641.
- [20] Chen JH, Mehta RS, Nalcioglu O, Su MY. Inflammatory breast cancer after neoadjuvant chemotherapy: can magnetic resonance imaging precisely diagnose the final pathological response? *Ann Surgical Oncology*. 2008;15:3609–3622.