

Surgical treatment of nutcracker syndrome

Nunzio Montelione,¹ Alessandra Scotto di Uccio,² Vincenzo Catanese,¹ Francesco Alberto Codispoti,¹ Alessandro Ciolli,^{1,3} Julia Paolini,^{1,3} Alessandra Panichelli,^{1,4} Francesco Spinelli,¹ Francesco Stilo¹

¹Research Unit of Vascular Surgery, Department of Medicine and Surgery, Università Campus Bio-Medico, Fondazione Policlinico Universitario Campus Bio-Medico, Rome; ²General Surgery and Organ Transplantation Unit, Azienda Ospedaliero-Universitaria Policlinico Umberto I, School of General Surgery, Sapienza University of Rome; ³Vascular Surgery Unit, Fondazione Policlinico Universitario A. Gemelli IRCCS, Università Cattolica del Sacro Cuore, Rome; ⁴Research Unit of General Surgery, Department of Medicine and Surgery, Università Campus Bio-Medico, Fondazione Policlinico Universitario Campus Bio-Medico, Rome, Italy

Correspondence: Nunzio Montelione, Research Unit of Vascular Surgery, Department of Medicine and Surgery, Università Campus Bio-Medico Roma, Fondazione Policlinico Universitario Campus Bio-Medico, via Alvaro del Portillo 200, 00128 Rome, Italy.
Tel: +39 3479598785.
E-mail: n.montelione@policlinicocampus.it

Key words: Nutcracker Syndrome, Left Renal Vein, hematuria, vascular compression.

Contributions: NM, FSt, conceptualization and design of the work; ASU, VC, NM, writing - original draft preparation, software, and formal analysis; FSp, NM, writing - review and editing; NM, VC, FSt, acquisition and interpretation of data. All the authors have read and approved the final version of the manuscript and agreed to be held accountable for all aspects of the work.

Conflict of interest: the authors declare no potential conflict of interest.

Funding: none.

Ethics approval and consent to participate: all procedures performed in studies involving human participants were in accordance with the ethical standards of the Institutional Research Committee and with the 1964 Helsinki Declaration and its latest amendment.

Informed consent: all subjects involved in the study gave written informed consent for the procedure.

Availability of data and materials: all data generated or analyzed during this study are included in this published article.

Received: 5 January 2024.

Accepted: 9 May 2024.

Early view: 13 May 2024.

©Copyright: the Author(s), 2024

Licensee PAGEPress, Italy

Veins and Lymphatics 2024; 13:12259

doi:10.4081/vl.2024.12259

This work is licensed under a Creative Commons Attribution-NonCommercial 4.0 International License (CC BY-NC 4.0).

Publisher's note: all claims expressed in this article are solely those of the authors and do not necessarily represent those of their affiliated organizations, or those of the publisher, the editors and the reviewers. Any product that may be evaluated in this article or claim that may be made by its manufacturer is not guaranteed or endorsed by the publisher.

Abstract

The objective of this paper is to report early and mid-term outcomes of the surgical treatment of Nutcracker Syndrome (NCS) in a single-center prospective study. Between January 2019 and September 2023, five patients with symptomatic NCS were treated at our center using left renal vein caudal transposition on the inferior vena cava, conducted through a midline incision of approximately 12 cm and a transperitoneal technique. Patient characteristics, presentation, length of hospital stay, and complications were analyzed. All diagnoses were established after clinical evaluation, ultrasound scanning, and radiological investigations, which confirmed left renal vein compression between the aorta and the Superior Mesenteric Artery (SMA). The average operating time was 159 minutes, with an average blood loss of 205 mL. There was no need for blood transfusions. Intensive care stay was not required, and there were no early complications. The mean length of stay was 3.5 days. At a mean follow-up of 18.8 months, one patient reported persistent hematuria, and, therefore, underwent a secondary procedure, which incorporated patch venoplasty using the great saphenous vein. In our experience, left renal vein transposition appears to be a safe and effective procedure for the surgical management of severe NCS.

Introduction

Nutcracker Syndrome (NCS), also known as left renal vein entrapment syndrome, is a rare vascular disorder characterized by the compression of the Left Renal Vein (LRV) between the abdominal aorta and the Superior Mesenteric Artery (SMA).¹ This compression results in impaired blood flow from the left kidney to the Inferior Vena Cava (IVC), often leading to a constellation of symptoms and potential complications.

Due to the nutcracker effect, in which the LRV experiences extrinsic compression as it traverses this anatomically constrained region, there is increased pressure within the LRV which can result in hematuria, flank pain, proteinuria, and left gonadal vein congestion, among other clinical manifestations.² Furthermore, the syndrome's presentation can vary widely among affected individuals, making diagnosis and management a complex challenge for clinicians. Over the years, advances in imaging modalities such as Computed Tomography Angiography (CTA) and Magnetic Resonance Imaging (MRI) have facilitated the accurate diagnosis of NCS.^{3,4} Nevertheless, many aspects of NCS, including its etiology, natural history, and optimal treatment approaches, remain subjects of ongoing research and debate.

Due to the syndrome's rarity, there remains a need for more

comprehensive studies, especially in clinical settings, to provide insights into the management and outcomes of affected patients. This article seeks to address this need by presenting a case series of patients who underwent left renal vein transposition at our institution. Through a detailed analysis of these cases, we aim to shed light on the characteristics of NCS patients who required surgical intervention and report the outcomes of such procedures. By focusing on our institution's experience with this complex vascular disorder, we intend to contribute valuable clinical data that can inform the management of NCS.

Materials and Methods

The study was conducted in accordance with the Declaration of Helsinki. All subjects involved in the study gave written informed consent for the procedure.

All patients who presented to the Fondazione Policlinico Campus Bio-Medico (Rome, Italy) between January 2018 and September 2023 with NCS and who subsequently underwent LRV transposition were retrospectively reviewed. All diagnoses were established after clinical evaluation, ultrasound scanning, and CTA (Figure 1), which confirmed LRV compression between the aorta and the SMA. Patient characteristics, presentation, length of hospital stay, and complications were analyzed.

During the study period, five patients (4 males and 1 female), with an average age of 24 years (range 16–46 years), were diagnosed with severe NCS and were identified as candidates for surgical treatment. All patients presented with hematuria, with two of them also reporting left flank pain. Notably, none of the patients exhibited varicocele. One patient had previously undergone abdominal surgery (*Roux-en-Y* jejunostomy) for superior duodenal compression secondary to mesenteric artery syndrome. All patients had performed a CT scan before surgery which demonstrated an aorto-SMA angle of less than 35° .⁵ Due to the presence of symptoms and typical radiographic characteristics, further invasive tests were deemed unnecessary to diagnose NCS. After the initial diagnosis, all patients were treated conservatively with ACE inhibitors

and aspirin for at least 6 months but did not experience symptom resolution. Consequently, transposition of the LRV was performed.

Operation technique

All the operations were performed by the same experienced vascular surgeon. Our preferred approach has been the caudal transposition of the LRV on the IVC, conducted through a midline incision of approximately 12 cm and a transperitoneal technique (Figure 2). Following preparation of the inferior vena cava and of the LRV and artery, the gonadal and adrenal veins could be ligated and sectioned to favor LRV mobilization. Systemic heparinization was initiated, and a side-biting clamp was applied to the IVC around the origin of the LRV, which was also clamped along with the left renal artery. The LRV was sectioned at its confluence with the IVC, and the resulting defect was oversewn with a continuous nonabsorbable monofilament suture. Subsequently, the side clamp was repositioned three to four centimeters caudally along the IVC, where a venotomy was executed, and the end-to-side anastomosis between the LRV and the IVC was performed with a running nonabsorbable five-0 monofilament suture (Figure 3). After clamp removal, a Doppler ultrasound scan was performed to verify the patency of the transposed LRV and the presence of phasic blood flow within the vessel. In one case presenting with circumferential fibrosis and vein stricture, we added a secondary procedure with vein patch venoplasty using the great saphenous vein to widen the confluence of the transposed LRV and the IVC (Figure 4).

Outcome measures and follow-up protocol

The primary outcome measures were technical success, 30-day major adverse events, and reintervention during follow-up. The secondary outcomes were operating time, average blood loss, need for blood transfusions, Intensive Care Unit (ICU) stay, and mean duration of hospitalization.

Postoperative follow-up appointments were scheduled at the outpatient clinic at 1, 3, 6, and 12 months after surgery, followed by annual visits thereafter. Ultrasounds were conducted during each visit, with a CT scan scheduled at the 3-month mark for comprehensive evaluation.

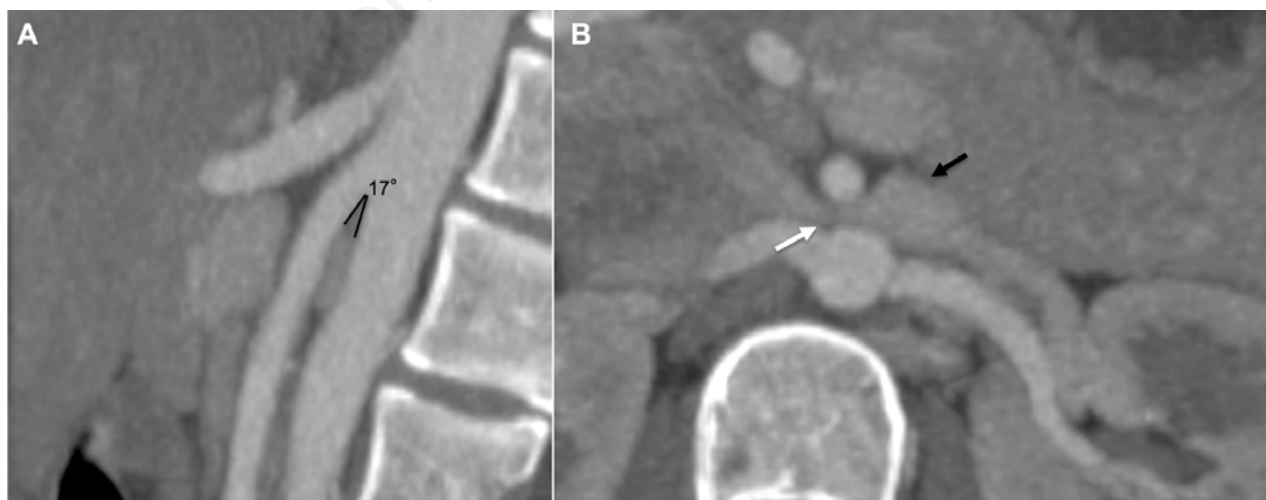

Figure 1. Preoperative computed tomographic angiography showing **A**) the small aorto-mesenteric angle (17°) between Superior Mesenteric Artery (SMA) and abdominal aorta **B**) that compress the left renal vein (white arrow) with a consequent pre-stenotic dilatation (black arrow).

Results

There were no early (<30 days) complications nor reinterventions reported. The average operating time was 159 minutes (range 138-180 minutes) with an average blood loss of 205 mL (range 100-400 mL). There was no need for blood transfusions.

None of the patients required postoperative ICU admission, and the mean length of hospitalization was 3.5 days (range 3-5 days). At an average follow-up of 18.8 months (range 3-83) one patient reported persistent hematuria 3 months postoperatively and, therefore, underwent a secondary transposition procedure which incorporated patch venoplasty using the great saphenous vein. This ultimately leads to symptom resolution. In the remaining patients, symptoms resolved after the index operation. Postoperative CTA performed by all the patients confirmed patent LRV without signs of new compression.

Discussion

The management of NCS remains a challenging clinical scenario, and the selection of an appropriate therapeutic approach necessitates careful consideration of the patient's clinical presentation and the severity of the syndrome. Several treatment options are available, including conservative management, endovascular interventions, and surgical correction. Conservative management is usually proposed in mild cases or when the symptoms are manageable by pain control and close monitoring,^{6,7} especially in the

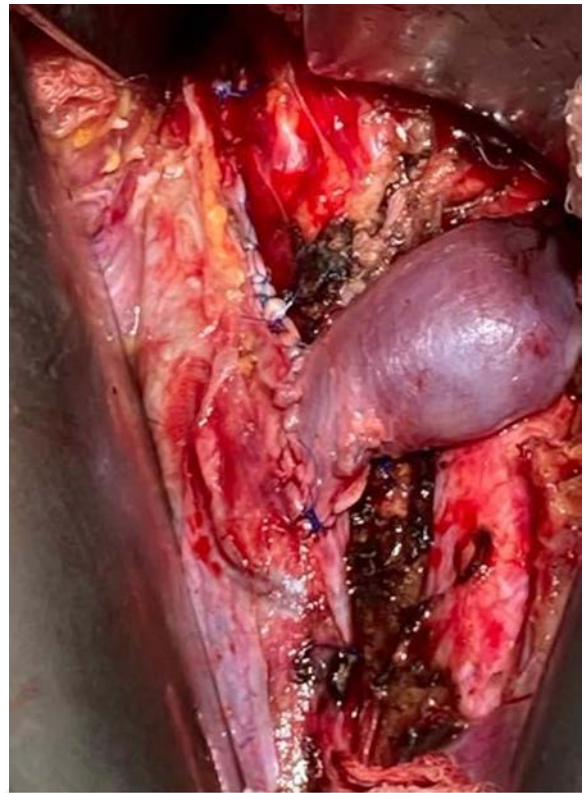

Figure 3. Intraoperative photograph showing the completed renal transposition.

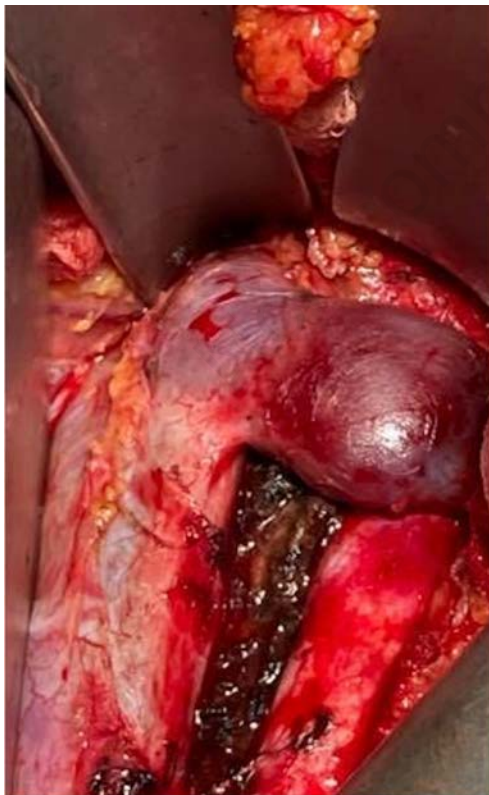


Figure 2. Intraoperative photograph of a dilated Left Renal Vein (LRV) with the impression of the Superior Mesenteric Artery (SMA) due to prolonged compression.

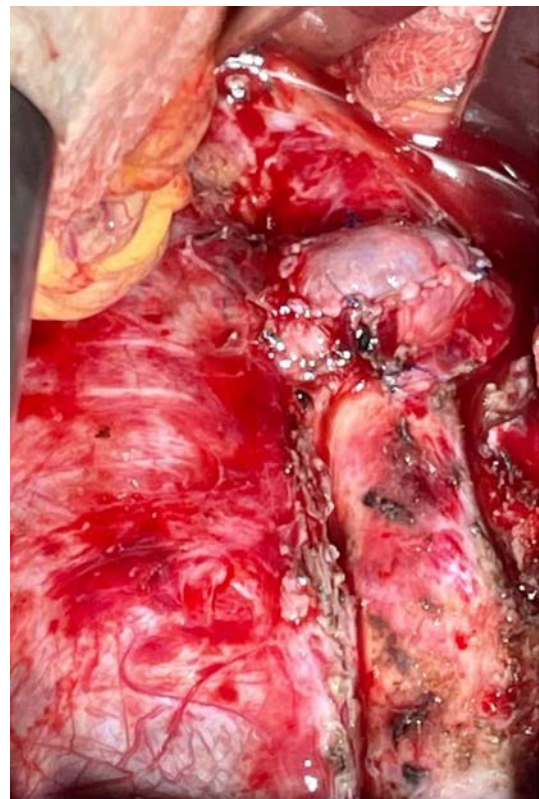

Figure 4. Intraoperative photograph of the completed procedure comprising saphenous vein patch venoplasty.

pediatric population.⁸ Patients are often advised to maintain adequate hydration and avoid activities that exacerbate symptoms. Pharmacological interventions, including Non-Steroidal Anti-Inflammatory Drugs (NSAIDs), angiotensin converting enzyme inhibitors,⁹ and anticoagulants, have been used to alleviate symptoms such as pain and hematuria. These treatments aim to reduce inflammation, orthostatic proteinuria and minimize clot formation within the renal vein.

Endovascular interventions, such as renal vein stenting and angioplasty, have gained prominence in recent years.¹⁰ These techniques aim to relieve the compression of the LRV and improve blood flow. However, their long-term efficacy and safety profile require further investigation.^{4,11} A recent review by Fuentes-Perez *et al.* instead analyzes the rate of complications and recurrences in endovascular and laparoscopic extravascular stent placement. After endovascular stenting, symptoms resolved in 76% of cases, while extravascular stenting resulted in symptom resolution in 83% of cases. Out of 185 patients, 9 necessitated reintervention following endovascular stenting, while none required reintervention after extravascular stenting.¹²

Surgical correction, such as nephropexy, venous bypass, renal vein transposition, or renal autotransplantation, may be considered in severe and refractory cases.¹³⁻¹⁵ These procedures are typically reserved for patients with severe symptoms or complications. A recent minimally invasive surgical treatment consists of laparoscopic extravascular stenting.

In our retrospective study, we focused on a cohort of four patients diagnosed with severe NCS who were candidates for surgical treatment. Our findings shed light on both the outcomes of the surgical intervention and the long-term follow-up of these patients.

Hematuria and left flank pain are frequently encountered symptoms in NCS, stemming from the compression of the left renal vein between the aorta and the SMA. Interestingly, none of the patients in our cohort exhibited varicocele, which is another commonly reported symptom of NCS.

Surgical intervention is often considered in patients with severe NCS who fail to respond to conservative management. In our study, all patients underwent left renal vein transposition, a well-established surgical technique for NCS, after the failure of a well-conducted conservative approach. The procedure was performed with meticulous care by an experienced surgeon, and the outcomes were generally favorable. Notably, none of the patients required postoperative ICU admission, indicating the safety and feasibility of the surgical approach in our setting.

The relatively short average hospital stay of 3.5 days in our study further supports the notion that left renal vein transposition can be performed with minimal postoperative morbidity, allowing for a swift recovery and hospital discharge.

Our study also provides valuable insights into the long-term outcomes of surgical intervention for NCS. The average follow-up period of 18 months allowed us to monitor patients for potential early and mid-term postoperative complications and symptom recurrence. One patient reported persistent hematuria three months after the initial surgery, needing a secondary procedure with the application of a great saphenous vein patch.

Our case of early recurrence needing a reintervention deserves some technical remarks. First, patients reporting symptoms for several years, which is often the case for this under-diagnosed condition, may develop intense fibrosis around the distal portion of the LRV as it crosses the anterior aspect of the aorta. This was the case for our short-term failure in the 23-years female patient complaining of hematuria and left flank pain for over five years, with a trend

toward progression in the last two. At the first intervention, we faced intense fibrosis surrounding the vein and a stricture due to scar tissue. This was not evident both at echography and at contrast-enhanced CT scan as both exams evidenced a tight compression of the vein but could not make a clear distinction between a functional stricture, leaving an intact vessel wall when decompressed, and an anatomical stricture due to scar tissue making the distal part of the LRV unusable for caudal transposition. Once freed by careful sharp dissection from the surrounding fibrosis, the distal 8 to 10 millimeters of the vein presented an intrinsic tight stricture, and we decided to discard this segment to obtain a large vein wall suitable for caudal re-implantation on the IVC. Despite adequate mobilization of the entire LRV by cutting the left ovarian and the supra renal veins, the suture was eventually somewhat in tension, leading to early recurrence of symptoms.

The reintervention was carried out three months after, and we faced an even more intense fibrosis and stricture at the level of the anastomosis. To treat this, we could either completely replace the diseased segment of the LRV or attempt to patch it to correct the stricture.

For the first solution, the greater saphenous vein, previously measured at echo, was 3.2 millimeters large and had been judged insufficient for replacement, even if it could have been fit for a collar or a short spiral graft. An alternative solution could be an internal jugular free vein graft, with the inconvenience of an additional scar on the neck of this young lady. We, therefore, decided to use the greater saphenous vein to make a roof patch on the suture encompassing the distal LRV and the anterior aspect of the IVC to correct the stricture.

This experience outlines the need to be aware of the fibrosis of the distal LRV as a possible cause of recurrence in patients with long-standing disease and to be ready to face and treat this situation with a more demanding and time-consuming technical solution. Also, the patient should be previously informed about the possibility of a longer operation and an additional scar in the upper thigh or in the neck for vein harvesting, as in such a delicate situation, a synthetic patch would not be advisable.

In Erben *et al.*'s 2015 article on 36 cases of NCS treated surgically at the Mayo Clinic between 1994 and 2014, 11 cases of reintervention were reported (30.5%).¹⁶ This underscores the importance of continued postoperative follow-up and the need for potential re-intervention in select cases to achieve symptom resolution.

While our study offers insights into the surgical management of severe NCS, it is important to acknowledge its limitations, including the small sample size and the absence of a control group. Moreover, the long-term effectiveness of left renal vein transposition in preventing symptom recurrence warrants further investigation in larger cohorts and through comparative studies with other surgical or endovascular approaches.

Conclusions

In conclusion, our study highlights the safety and efficacy of left renal vein transposition in the surgical management of severe NCS. While the initial outcomes were generally favorable, persistent symptoms in one patient underscore the need for continued postoperative monitoring. As the understanding of NCS and its management evolves, further research is essential to refine surgical techniques and optimize long-term outcomes for affected patients.

References

1. El-Sadr AR, Mina E. Anatomical and surgical aspects in the operative management of varicocele. *Urol Cutaneous Rev* 1950;54:257-62.
2. Kurklinsky AK, Rooke TW. Nutcracker phenomenon and Nutcracker Syndrome. *Mayo Clin Proc* 2010;85:552-9.
3. Dieleman F, Hamming JF, Erben Y, van der Vorst JR. Nutcracker Syndrome: challenges in diagnosis and surgical treatment. *Ann Vasc Surg* 2023;94:178-85.
4. Kolber MK, Cui Z, Chen CK, et al. Nutcracker syndrome: diagnosis and therapy. *Cardiovasc Diagn Ther* 2021;11:1140-9.
5. Merrett ND, Wilson RB, Cosman P, Biankin AV. Superior Mesenteric Artery Syndrome: diagnosis and treatment strategies. *J Gastrointest Surg* 2008;13:287-92.
6. Ananthan K, Onida S, Davies AH. Nutcracker Syndrome: an update on current diagnostic criteria and management guidelines. *Eur J Vasc Endovasc Surg* 2017;53:886-94.
7. Menard MT. Nutcracker Syndrome: when should it be treated and how? *Perspect Vasc Surg Endovasc Ther* 2009;21:117-24.
8. Miró I, Serrano A, Pérez-Ardavín J, et al. Eighteen years of experience with pediatric nutcracker syndrome: the importance of the conservative approach. *J Pediatr Urol* 2020;16:218.e1-218.e6.
9. Hosotani Y, Kiyomoto H, Fujioka H, et al. The nutcracker phenomenon accompanied by renin-dependent hypertension. *Am J Med* 2003;114:617-8.
10. Chen S, Zhang H, Shi H, et al. Endovascular stenting for treatment of Nutcracker Syndrome: report of 61 cases with long-term follow-up. *J Urol* 2011;186:570-5.
11. Wu Z, Zheng X, He Y, et al. Stent migration after endovascular stenting in patients with Nutcracker Syndrome. *J Vasc Surg Venous Lymphat Disord* 2016;4:193-9.
12. Fuentes-Perez A, Bush RL, Kalra M, et al. Systematic review of endovascular versus laparoscopic extravascular stenting for treatment of Nutcracker Syndrome. *J Vasc Surg Venous Lymphat Disord* 2023;11:433-41.
13. Velasquez CA, Saeyeldin A, Zafar MA, et al. A systematic review on management of Nutcracker Syndrome. *J Vasc Surg Venous Lymphat Disord* 2018;6:271-8.
14. Avgerinos ED, McEnaney R, Chaer RA. Surgical and endovascular interventions for Nutcracker Syndrome. *Semin Vasc Surg* 2013;26:170-7.
15. Said SM, Gloviczki P, Kalra M, et al. Renal Nutcracker Syndrome: surgical options. *Semin Vasc Surg* 2013;26:35-42.
16. Erben Y, Gloviczki P, Kalra M, et al. Treatment of Nutcracker Syndrome with open and endovascular interventions. *J Vasc Surg Venous Lymphat Disord* 2015;3:389-96.