

# An original technique for the treatment of axillary web syndrome: the Onorato-Ausbergher method

Alberto Onorato,<sup>1</sup> Stefania Ausbergher,<sup>2</sup> Elisa Dorigo<sup>2</sup>

<sup>1</sup>MD, PhD, Linfamed Srl., Udine; <sup>2</sup>Physiotherapist, Linfamed Srl., Udine, Italy;

## Abstract

Axillary Web Syndrome (AWS) is a common complication in patients who have undergone an axillary lymph node biopsy or dissection for breast cancer. This work aims to explore in a preliminary way the effectiveness of a therapeutic approach with Neuromuscular Taping (NMT) for the aforementioned condition. Specifically, five patients have been treated and have undergone specific evaluation of typical AWS signs and symptoms, with a particular focus on the impact on Quality of Life (QoL) and Activities of Daily Life (ADLs). The final aim is to evaluate the efficacy of an innovative approach to AWS, allowing easy application, good tolerability, and few collateral effects.

Correspondence: Alberto Onorato, Linfamed Srl., via Pietro di Brazzà 7, Udine, Italy.  
Tel. +39.0432522772.  
E-mail: a.onorato@linfamed.it

Key words: neuromuscular tape, axillary web syndrome, breast cancer.

Contributions: AO, SA, research design and participation; ED, research participation. All the authors have read and approved the final version of the manuscript and agreed to be held accountable for all aspects of the work.

Conflict of interest: the authors declare no potential conflict of interest.

Funding: none.

Ethics approval and consent to participate: not applicable.

Informed consent: not applicable.

Availability of data and materials: all data generated or analyzed during this study are included in this published article.

Received: 25 March 2024.

Accepted: 2 June 2025.

©Copyright: the Author(s), 2024  
Licensee PAGEPress, Italy  
Veins and Lymphatics 2024; 13:12501  
doi:10.4081/vl.2024.12501

This work is licensed under a Creative Commons Attribution-NonCommercial 4.0 International License (CC BY-NC 4.0).

*Publisher's note: all claims expressed in this article are solely those of the authors and do not necessarily represent those of their affiliated organizations, or those of the publisher, the editors and the reviewers. Any product that may be evaluated in this article or claim that may be made by its manufacturer is not guaranteed or endorsed by the publisher.*

## Introduction

The surgical therapy of breast cancer can be responsible for complications in the post-operative period, even though of minor entity in case of conservative surgery if compared to demolitive surgery.<sup>1</sup> Sentinel lymph node biopsy, eventually followed by axillary dissection, represents the current “gold standard” for cancer stadiation in breast carcinoma<sup>2</sup> and can be associated with several complications, such as lymphedema or Axillary Web Syndrome (AWS). AWS is a condition that follows the removal of axillary lymph nodes; it is frequently recognized in the surgical treatment of breast cancer.<sup>3-6</sup> AWS is defined by the presence, in the axilla and upper limb, of visible and/or palpable cordings, often with pain during movement and reduction of shoulder Range of Motion (ROM).<sup>3,4</sup> Cordings might be single or multiple, and might extend from the axilla to the medial portion of the arm, to the cubital fossa and volar portion of the forearm, rarely up to the thumb.<sup>6</sup> According to the literature, this condition will spontaneously resolve in a time range that varies from 8-10 weeks up to 3 months post-op.<sup>3,6</sup> Some of the most recent research regarding the available treatments for this condition refers to the efficacy of long sessions (60 minutes) of complex combined physical therapies that require different types of treatment during the same therapy session, lasting for several weeks and often painful.<sup>7</sup> A recent study has underlined the lack of significance in the increase of the ROM of the shoulder of a frequently used technique, the manual snapping maneuver, associated with passive stretching, in comparison with just passive stretching.<sup>8</sup>

The aim of this work is to check the efficacy of the Onorato-Ausbergher method on signs and symptoms of AWS, which are: i) reduction of active ROM in one or more directions of movement; ii) presence of cordings in one or more locations of the upper limb; iii) presence of pain during movement.

We have chosen to retrieve past medical records of patients treated in Linfamed Srl. for AWS with an original Neuromuscular Tape (NMT) protocol. Patients were chosen with the following criteria: i) female patients who underwent breast cancer surgery and sentinel lymph node biopsy or axillary dissection; ii) patients who developed AWS signs and symptoms in the first weeks after surgery; iii) patients who have been treated with our original NMT protocol, subsequently patented as the Onorato-Ausbergher method; iv) patients who have been treated until resolution (no drop-outs).

Five female patients' medical records have been considered for this retrospective study. All of them underwent breast cancer surgery and a sentinel lymph node biopsy. All patients have been treated within one month of the surgery. The clinical diagnosis was confirmed by the medical doctor on occasion of the first post-surgical medication.

The main concerns and symptoms of our patients were tension during movement, restriction of active and passive ROM, pain during movement, and the presence of cord-like structures in the axilla and along the upper limb.

The Onorato-Ausbergher method suggests the use of taping according to the NMT technique; the number of treatment sessions varied from 4 to 6 according to the clinical response. Each session lasted 30 minutes, and sessions took place every 2-3 days. The treatment developed through the following phases: i) physiotherapeutic evaluation a few days after the medical diagnosis (T0); ii) treatment phase (2-3 weeks); iii) final physiotherapeutic evaluation (T1); iv) one-month follow-up (T2).

The technique consisted of the application of 2-3 tape strips.

The first tape strip application is a Kinesio tape five tails fan cut (Figure 1A) with the patient sitting, upper limb in a 90° abduction, slightly extra-rotated and extended, and placed on a support surface (this position might be difficult to maintain for a sufficient time). The patient is asked to turn their head in the opposite direction from the affected limb, granting the maximum skin stretch. This application starts from the medial third of the clavicle and ends in the upper half of the arm (Figure 1B, Figure 2, Figure 3).

The second application consists of a variable number (from 3 to 5) of “I” shaped tape strips (Figure 1C). The number of strips varies according to the anatomic dimensions of the treated area. The patient is lying down in a supine position, and the upper limb is in maximal flexion and external rotation (the ideal position is with the hand positioned under the back of the head), with the fully extended torso and lower limbs. The application starts from the axillary fossa and follows the cording pathways down the arm, towards the cubital fossa (Figure 1D, Figure 2).

If cordings are present in the cubital fossa as well, the third application consists in more “I” shaped tape strips positioned along the cubital fossa, following the cording pathways for their full length (Figure 3).

All applications are performed with tape tension of 0% (according to David Blow’s decompressive technique).

The hypothesis is that a decompressive application following the NMT technique, positioned immediately upon the cording, allows its detachment from the surrounding tissues by augmenting the subcutaneous space and, therefore, reducing the ROM limita-

tions and pain. In addition, this application brings better local lymphatic and haematic circulation, a quickening of the healing processes, and the elimination of the fibrotic tissues (the “cordings”). All these effects would allow a quick reduction of the ROM restrictions and the painful symptoms.

### Timing of reduction

Based on the clinical answers of the patients, the Onorato-Ausbergher method is thought to be interrupted as soon as the signs and symptoms are solved. All patients obtained a satisfying resolution of the symptoms with 6 or fewer treatment sessions (2-3 weeks). According to the literature, these data show that the treatment has significantly shortened the spontaneous resolution time frame (from 8-10 weeks to 3 months).<sup>3,4</sup>

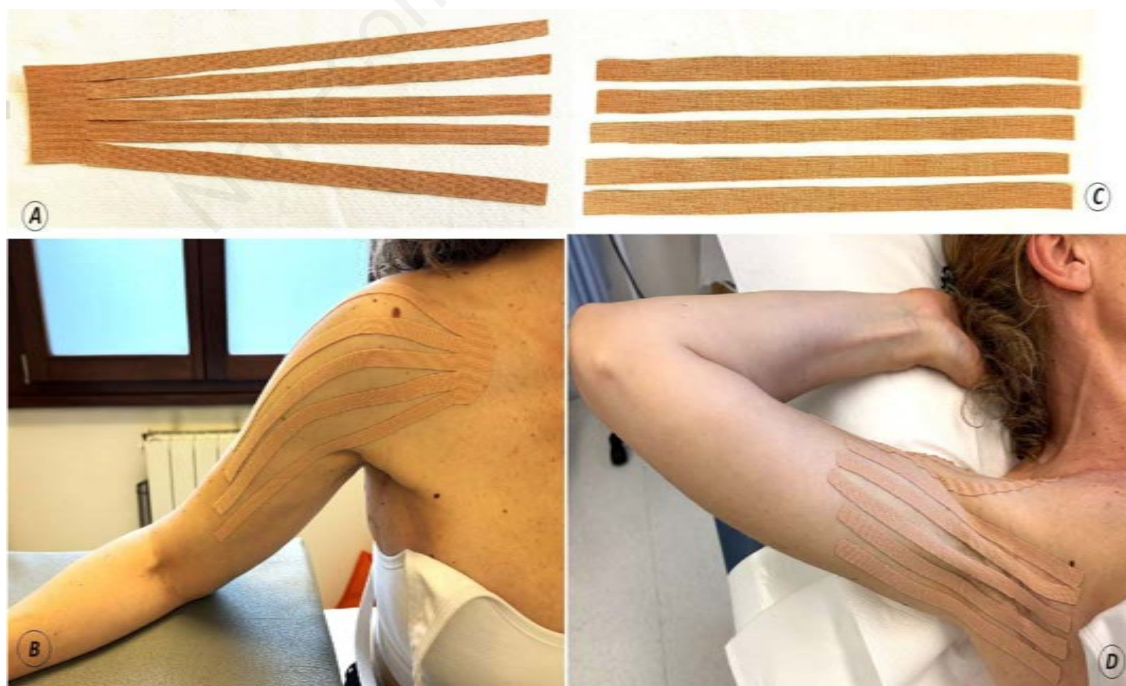
### Reduction of Range of Motion

We decided to report the difference in the degrees of movement between T0 and T1 (Table 1). The difference between ROM at T0 and T1 is noticeable in all patients; they have reached mobility comparable with the healthy limb, with the result of regaining a better or normal practice of ADLs. The recovery of active ROM has led to a recovery from a functional point of view.

There hasn’t been observed any reduction of ROM in any patient from T0 to T1, not in the previously affected movements, nor in any other movement of the affected limb; this might suggest that there’s no progressive worsening of signs and symptoms of AWS, when treated. This also highlights the importance of an early diagnosis and access to therapies.

### Pain

The most frequent symptom in AWS is pain. We used a subjective scale called the Numerical Rating Scale (NRS) to evaluate pain at three moments: at rest, during movement, and at the end of the movement. Literature suggests that pain at rest is not a usual finding in AWS, while pain is present during movement and most-



**Figure 1.** Tape strip application.

ly at the end of it.<sup>6,11-13</sup> Pain at T0 ranges from NRS 1 to NRS 6: the high pain level represents a limit for the ADLs. Only one patient reports pain at rest (NRS 1); all patients report pain during and at the end of the movement, up to high intensity. At T1 evaluation, we can observe an important pain reduction in all patients. This data is probably also important in the recovery of a full ROM, since the presence of pain often causes a restriction of movement due to the natural tendency to avoid the painful symptoms. This might also potentially diminish the emotional and psychological stress linked to this condition, leading to a better QoL.

### Number and classification of cordings

The reduction of cordings between T0 and T1 is clear, referring to their number, length, and Springer classification.<sup>12</sup> The cordings have not completely disappeared by the end of the treatment: we can infer that the Onorato-Ausberghe method does not lead to a complete disappearance of the cordings, but ensures an asymptomatic condition.

Patients report that the improvements have been constant and gradual throughout the sessions, sometimes partially relapsing after the removal of tape, sometimes permanent; the application of tape has, in all cases, given an immediate improvement of ROM in shoulder flexion and shoulder abduction, together with the perception of a feeling of “lightness” and “freedom of movement of the limb”.

### Activities of Daily Life and Quality of Life

According to the literature, the reduction of upper limb movements frequently causes limitations in functional activities, quantified through the Disability of Arm, Shoulder, and Hand (DASH) questionnaire.<sup>6</sup> The data we will refer to is gathered through two questionnaires given to patients at T1, specifically structured to analyze ADLs (first questionnaire) and QOL (second questionnaire).

The first questionnaire results suggest a positive insight: patients at the end of the treatment have declared to be fully self-sufficient in personal care, feeding, and getting dressed. The second questionnaire also suggests encouraging insights from a quality-of-life point of view: all patients report a noticeable improvement in their daily life, a release from stiffness in the movements of the upper limb, and the recovery of daily functions (such as wearing a sweater or practicing their hobbies). Patients have explained their positive attitude towards the received treatment according to their expectations and aims at the beginning of the sessions.

All these findings are even more interesting if we consider that we have observed that the situation at T2 does not present any variation in comparison to T1.

The treatment has not caused any side effects or complications

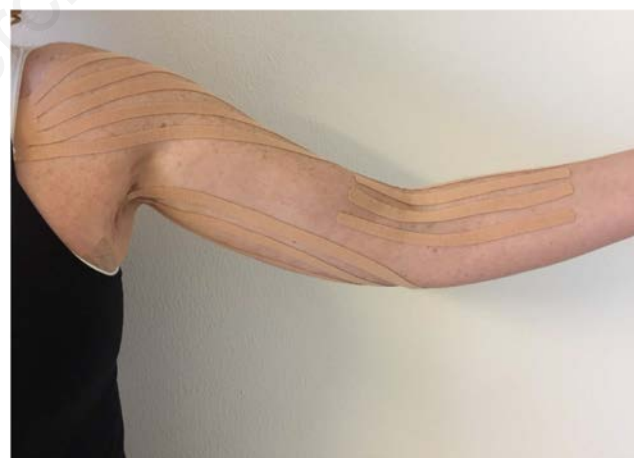in any of the patients. This suggests good treatment tolerability, with good adherence to simple instructions that the patients have received relative to the care and the timings of tape removal.

Patients have demonstrated very good compliance with the treatment, and none of them has felt the need to remove it before the expected time: the method has proven to be both simple and safe. No side effects have been reported.

Our observation has led to promising results, both from the anatomical/physiological and subjective/functional point of view, while reducing spontaneous recovery time and in the absence of significant symptoms left at T1. These results suggest the necessity to expand the group of patients, in order to obtain data that can be used for statistical scopes.



**Figure 2.** Picture of the application of the Onorato-Ausberghe method on one of the patients with symptoms in the axillary and brachial area.



**Figure 3.** Image of another patient with symptoms in the axillar, brachial and cubital area.

**Table 1.** Range of Motion (ROM).

	Shoulder flexion			Shoulder abduction			Shoulder external rotation			Shoulder internal rotation		
	T0	T1	Δ T0-T1	T0	T1	Δ T0-T1	T0	T1	Δ T0-T1	T0	T1	Δ T0-T1
L.C.1	150°	150°	0°	110°	160°	50°	90°	90°	0°	50°	50°	0°
S.D.Z.	100°	160°	60°	90°	160°	70°	90°	90°	0°	50°	50°	0°
A.V.	80°	130°	50°	90°	140°	50°	70°	90°	20°	50°	50°	0°
L.C.2	120°	150°	30°	130°	150°	20°	90°	90°	0°	50°	50°	0°
C.B.	140°	160°	20°	140°	160°	20°	90°	90°	0°	50°	50°	0°
M.B.	120°	-	-	130°	-	-	70°	-	-	50°	-	-

All patients have undergone an axillary lymph node biopsy but not axillary dissection. The homogeneity of surgical treatment in the axillary site is a crucial factor in the data observation; this highlights the importance of selecting another group of patients who have undergone axillary dissection to compare the results.

The main limit of our work is the low number of patients, which is also due to the lack of a standardized protocol for early diagnosis of AWS. Due to the low number of patients, it is impossible to obtain statistically significant data.

Our observation has laid the foundation to define a new study protocol: the validation of the technique might only be obtained through a randomized controlled trial with a sufficient case number to reach statistical significance, also considering a longer follow-up to verify the outcomes on a longer term.

---

## References

1. Giardina G, Richiardi G, Cortese P. Chirurgia della mammella in funzione del trattamento rieducativo. In: *Trattato di Medicina Fisica e Riabilitazione*. Utet; Turin, Italy; 2001.
2. Morrow M. Role of axillary dissection in breast cancer management. *Ann Surg Oncol* 1996;3:233-4.
3. Moskovitz AH, Anderson B, Yeung R, et al. Axillary Web Syndrome after axillary dissection. *Am J Surg* 2001;181:434-9.
4. Yeung WM, McPhail SM, Kuys SS. A systematic review of Axillary Web Syndrome (AWS). *J Cancer Surviv* 2015;9:576-98.
5. Torres Lacomba M, del Moral OM, Coperias Zazo JL, et al. Axillary web syndrome after axillary dissection in breast cancer: a prospective study. *Breast Cancer Res Treat* 2009;117:625-30.
6. Associazione Italiana Oncologia Medica (AIOM). Linee guida per la neoplasia della mammella. 2017. Available from: <https://www.aiom.it/linee-guida-aiom-2021-neoplasie-della-mammella/>
7. Borg MB, Mittino L, Battaglia M, et al. Tolerability, safety and efficacy of a specific rehabilitation treatment protocol for Axillary Web Syndrome: an observational retrospective study. *Cancers* 2023;15:426.
8. Sandrin F, Nevola Teixeira LF, Garavaglia M, et al. The efficacy in shoulder range of motion of a snapping manual maneuver added to a standardized exercise protocol in axillary web syndrome: a randomized controlled trial. *Acta Oncologica* 2023;62:969-76.
9. Ahmed RL, Prizment A, Lazovich D, et al. Lymphedema and quality of life in breast cancer survivors: the Iowa Women's Health Study. *J Clin Oncol* 2008;26:5689-96.
10. Blow D. *Taping Neuromuscolare – trattamento di edemi, ematomi e cicatrici*. Edi. Ermes; Milan, Italy; 2013.
11. Bergmann A, Mendes VV, de Almeida Dias R, et al. Incidence and risk factors for Axillary Web Syndrome after breast cancer surgery. *Breast Cancer Res Treat* 2012;987-92.
12. Springer BA, Levy E, McGarvey C, et al. Pre-operative assessment enables early diagnosis and recovery of shoulder function in patients with breast cancer. *Breast Cancer Res Treat* 2010;135-47.
13. Eretta C, Tridoni E, Isaia S, et al. Complex decongestive therapy in lymphedema: report from an interdisciplinary center. *Veins and Lymphatics* 2023;12:11551.