Early Access
Case Report

Veins and Lymphatics

eISSN 2279-7483
https://www.pagepressjournals.org/index.php/vl/index

Publisher's disclaimer. E-publishing ahead of print is increasingly important for the rapid dissemination of science. The **Early Access** service lets users access peer-reviewed articles well before print / regular issue publication, significantly reducing the time it takes for critical findings to reach the research community. These articles are searchable and citable by their DOI (Digital Object Identifier).

Veins and Lymphatics is, therefore, e-publishing PDF files of an early version of manuscripts that have undergone a regular peer review and have been accepted for publication, but have not been through the typesetting, pagination and proofreading processes, which may lead to differences between this version and the final one. The final version of the manuscript will then appear in a regular issue of the journal.

E-publishing of this PDF file has been approved by the authors.

All legal disclaimers applicable to the journal apply to this production process as well.

Veins and Lymphatics 2025 [online ahead of print]

To cite this article:
Domenico Mirabella, Manfredi Agostino La Marca, Ettore Dinoto, et al. Simultaneous great saphenous vein arterialization and drug-eluting balloon venous angioplasty in no-option chronic limb-threatening ischemia: a case report. Veins and Lymphatics. 2025;14:13131. doi:10.4081/vl.2025.13131

©The Author(s), 2025
Licensee PAGEPress, Italy

The publisher is not responsible for the content or functionality of any supporting information supplied by the authors. Any queries should be directed to the corresponding author for the article.
All claims expressed in this article are solely those of the authors and do not necessarily represent those of their affiliated organizations, or those of the publisher, the editors and the reviewers.
Any product that may be evaluated in this article or claim that may be made by its manufacturer is not guaranteed or endorsed by the publisher.

Simultaneous great saphenous vein arterialization and drug-eluting balloon venous angioplasty in no-option chronic limb-threatening ischemia: a case report

Domenico Mirabella,[1] Manfredi Agostino La Marca,[1] Ettore Dinoto,[1] Rosa Federico,[1] Miriam Altamonte,[1] Felice Pecoraro,[1,2] Salvatore Bruno[1]

[1]Vascular Surgery Unit, AOUP Policlinico P. Giaccone, Palermo;

[2]Department of Surgical, Oncological and Oral Sciences, University of Palermo, Italy;

Correspondence: Ettore Dinoto, Vascular Surgery Unit, Azienda Ospedaliera Universitaria Policlinico P. Giaccone, via Liborio Giuffrè 5, 90128 Palermo, Italy.

E-mail: ettoredinoto@gmail.com

Key words: chronic limb ischemia; endovascular; venous arterialization technique; drug eluting balloon.

Contributions: MALM, study concept, design, data collection, analysis, and interpretation; DM, ED study concept, design, data collection, analysis, and interpretation, writing the paper; MA data collection, and analysis; RF, FP, SB, study concept, design, data collection, analysis, and interpretation. All the authors have read and approved the final version of the manuscript, and agreed to be held accountable for all aspects of the work.

The publisher is not responsible for the content or functionality of any supporting information supplied by the authors. Any queries should be directed to the corresponding author for the article.
All claims expressed in this article are solely those of the authors and do not necessarily represent those of their affiliated organizations, or those of the publisher, the editors and the reviewers.
Any product that may be evaluated in this article or claim that may be made by its manufacturer is not guaranteed or endorsed by the publisher.

Conflict of interest: the authors declare no potential conflict of interest.

Funding: none.

Ethics approval and consent to participate: not applicable.

Informed consent: not applicable.

Patient's consent for publication: the patient consented to the publication of this case report and any accompanying images.

Availability of data and materials: data will be available from the corresponding author upon reasonable request.

The publisher is not responsible for the content or functionality of any supporting information supplied by the authors. Any queries should be directed to the corresponding author for the article.
All claims expressed in this article are solely those of the authors and do not necessarily represent those of their affiliated organizations, or those of the publisher, the editors and the reviewers.
Any product that may be evaluated in this article or claim that may be made by its manufacturer is not guaranteed or endorsed by the publisher.

Abstract

In young patients with Chronic Limb-Threatening Ischemia (CLTI) with inadequate arterial networks for revascularization, unconventional approaches can be justified before a major amputation.

We report a case of a young man, with critical ischemia unsuitable for conventional revascularization interventions. Subjected to Common Femoral Artery (CFA) and Deep Femoral Artery (DFA) endarterectomy and Dacron patch and hybrid venous arterialization technique with anastomosis of the great saphenous vein to the Dacron patch and paclitaxel-coated Percutaneous Transluminal Angioplasty (PTA) balloon catheter angioplasty of the great saphenous vein. The success of the procedure is confirmed by the healing of the trophic lesion. Arterialization of the venous system is an option in salvage treatments and can be performed in both the deep and superficial systems by connecting the arterial and venous systems. Several hybrid techniques are available with comparable results.

There is no consensus on the best treatment strategy for venous arterialization for limb salvage.

The publisher is not responsible for the content or functionality of any supporting information supplied by the authors. Any queries should be directed to the corresponding author for the article.
All claims expressed in this article are solely those of the authors and do not necessarily represent those of their affiliated organizations, or those of the publisher, the editors and the reviewers.
Any product that may be evaluated in this article or claim that may be made by its manufacturer is not guaranteed or endorsed by the publisher.

Introduction

Patients with Chronic Limb-Threatening Ischemia (CLTI) who have inadequate arterial networks for revascularization face the highest risk of major limb amputation.[1,2] Up to 20% of CLTI patients find that arterial revascularizations are either anatomically unfeasible or ineffective.[3] One specific form of CLTI is *thromboangiitis obliterans*, commonly referred to as Buerger's disease, in which an inflammatory condition leads to rapid and progressive vascular damage in both arteries and veins.[4] Young smokers are increasingly being admitted with CLTI, and in these cases, unconventional approaches may be warranted before resorting to a major amputation. While endovascular management of Buerger's disease has been reported to yield favorable outcomes for patients with CLTI and inadequate arterial networks for revascularization, alternative strategies, such as arterialization of the Great Saphenous Vein (GSV), should be considered to prevent major limb amputation.[5] By employing innovative techniques and hybrid treatment strategies, clinicians can provide renewed hope for patients suffering from Buerger's Disease and other forms of CLTI, ultimately enhancing outcomes and quality of life for these high-risk individuals. In this case, a patient with no anatomical options for arterial was successfully treated using a simultaneous hybrid approach that included endarterectomy of the Common Femoral Artery (CFA) and Deep Femoral Artery (DFA), accompanied by femoral patch, arterialization of the GSV, and GSV Drug-Eluting Balloon (DEB) angioplasty. The Arterialization of the GSV has proven to be a viable and effective treatment option for patients with CLTI, particularly in cases where conventional revascularization techniques are not feasible. By utilizing the GSV as an arterial conduit,

The publisher is not responsible for the content or functionality of any supporting information supplied by the authors. Any queries should be directed to the corresponding author for the article.
All claims expressed in this article are solely those of the authors and do not necessarily represent those of their affiliated organizations, or those of the publisher, the editors and the reviewers.
Any product that may be evaluated in this article or claim that may be made by its manufacturer is not guaranteed or endorsed by the publisher.

patients can experience improved blood flow and reduced ischemic symptoms, ultimately leading to an enhanced quality of life and decreased risk of major amputation.

Case Report

A 39-year-old male, heavy smoker, with a history of Peripheral Artery Disease (PAD) for over 6 years and advanced Burger's disease, presented with left CLTI characterized by chronic ulceration in the middle leg and clinical signs of local infection. His clinical history reveals multiple surgeries on the right lower limb, followed by a below-the-knee amputation. Furthermore, he underwent several revascularization procedures, including Percutaneous Transluminal Angioplasty (PTA) and superficial femoral artery stenting, and DEB angioplasty, along with additional re-PTA procedures due to restenosis. Notably, there were no reports of coronary artery disease, cardiac arrhythmias, or coagulation disorders. However, over the years, a progressive deterioration of vascular health was observed, marked by a slow occlusion of main arterial pathways, despite numerous initial revascularizations that yielded positive results, followed by subsequent failures attributed to poor compliance.

At admission, the patient presented afebrile, with a systemic blood pressure of 120/70 mmHg, a heart rate of 78 bpm, oxygen saturation at 94%, and significant pain at rest (8/10), which was responsive only to morphine-like therapy.

The Ankle-Brachial index (ABI) was measured at 0.37, and Transcutaneous Oximetry ($TcPO_2$) indicated a value of 19 mmHg.

Arterial Duplex Ultrasound (DUS) revealed direct flow in the left external iliac artery, along with pre-occlusive stenosis in the CFA and at the origin of the DFA. Complete occlusion was

The publisher is not responsible for the content or functionality of any supporting information supplied by the authors. Any queries should be directed to the corresponding author for the article.
All claims expressed in this article are solely those of the authors and do not necessarily represent those of their affiliated organizations, or those of the publisher, the editors and the reviewers.
Any product that may be evaluated in this article or claim that may be made by its manufacturer is not guaranteed or endorsed by the publisher.

noted in the Superficial Femoral (SFA), Popliteal Artery (PA), anterior and posterior Tibial Arteries (TA), and interosseous artery.

The DUS of the GSV demonstrated a mean diameter of 3.5 mm with multiple areas of vein stenosis and competent valves.

As a compassionate limb-salvage measure, a hybrid approach was proposed to establish direct flow through the superficial venous pathway as an alternative to major amputation of the right leg.

Under general anesthesia and systemic heparinization (ACT target >180 seconds), the initial treatment step involved a CFA and DFA endarterectomy, followed by angioplasty using a Dacron patch (Vascutek, Terumo Company, Inchinnan, UK) angioplasty (Figure 1).

The origin of the GSV was isolated, ligated, and laterally mobilized.

The Dacron patch (Vascutek) was then utilized as an inflow source to the GSV through a terminal-lateral anastomosis (Figure 2).

Subsequently, a GSV collateral was utilized to place a 0.035 PTFE coated guidewire (Boston Scientific, Marlborough, MA, US) in antegrade fashion (Figure 3). Over the guidewire, an Avanti 6F sheath (Cordis, Santa Clara, CA, US) was then inserted (Figure 4).

The angiography confirmed multiple stenoses of the GSV and the presence of significant collaterals at the level of the thigh (Figure 5).

The GSV angioplasty was performed using a 5.0 x 250 mm paclitaxel-coated PTA Balloon Catheter (Admiral Xtreme, Medtronic, CA, US) (Figure 6).

The control angiography demonstrated the patency of GVS with no residual stenoses (Figure 7) and confirmed the patency of the GSV thigh collaterals (Figure 8).

The publisher is not responsible for the content or functionality of any supporting information supplied by the authors. Any queries should be directed to the corresponding author for the article.
All claims expressed in this article are solely those of the authors and do not necessarily represent those of their affiliated organizations, or those of the publisher, the editors and the reviewers.
Any product that may be evaluated in this article or claim that may be made by its manufacturer is not guaranteed or endorsed by the publisher.

During DUS, the collateral veins of GSV were identified and surgically ligated.

The postoperative course was uneventful. At 24 hours post-surgery, mild edema and hyperemia of the limb were noted, with DUS confirming the patency of the GSV and the presence of direct flow. $TcPO_2$ was measured at 26 mmHg. The patient reported a pain reduction of 6/10, prompting a request for a reduced dosage of pain medication for better control. Any changes in leg flow detected in the days following the procedure would be managed with ultrasound-guided percutaneous ligation if required.

At four weeks, the patient reports no resting pain and normal leg temperature with a $TcPO_2$ of 38 mmHg. By six weeks, significant healing of the trophic lesion in the leg was evident, accompanied by a $TcPO_2$ of 48 mmHg, although foot edema persisted.

Discussion

A significant proportion of patients with Critical Limb-Threatening Ischemia (CLTI), up to 20%, are not suitable candidates for arterial revascularization via open, endovascular, or hybrid techniques.[3] This ineligibility primarily arises from insufficient outflow in the foot, often due to Small Artery Disease (SAD) coupled with extensive arterial degeneration. This group typically includes high-risk patients suffering from diabetes, end-stage renal disease, and various forms of SAD. The Global Vascular Guidelines define "No-option" anatomy through clinical indicators, such as the absence of a target artery that crosses the ankle and a lack of suitable targets within the pedal or plantar arteries, as observed in the reviewed case.[6]

In cases of advanced arterial disease where revascularization options are limited, a primary major amputation is typically recommended to relieve pain and prevent gangrene. However,

The publisher is not responsible for the content or functionality of any supporting information supplied by the authors. Any queries should be directed to the corresponding author for the article.
All claims expressed in this article are solely those of the authors and do not necessarily represent those of their affiliated organizations, or those of the publisher, the editors and the reviewers.
Any product that may be evaluated in this article or claim that may be made by its manufacturer is not guaranteed or endorsed by the publisher.

there are documented cases of salvage procedures that aim to prevent major amputation while effectively managing pain and gangrene, with varying degrees of success.[7] The identification of patients in this category has led to the exploration of alternative treatment options, such as venous arterialization, a technique first described by Halstead and Vaughan in 1912. Despite initially low success rates, venous arterialization has recently seen a resurgence due to innovative techniques developed by Sheil, which have successfully facilitated the destruction of venous valves. Since then, the principle of arterialization has been adapted in various ways to enhance retrograde tissue oxygenation. The key to its effectiveness lies in the destruction of valves and proper perfusion of the forefoot.[8] Other treatment modalities, such as stem cell therapy, spinal cord stimulation, and prostanoid therapy, have been evaluated across multiple meta-analyses of placebo-controlled trials. However, these studies did not demonstrate significant improvements in primary outcome measures such as amputation rates, overall survival, or amputation-free survival among patients with critical limb ischemia, although spinal cord stimulation did reveal some protective effects against amputation.[9-11] Venous arterialization remains a viable option for salvage procedures, involving connection between the arterial and venous systems, either through deep or superficial networks. The underlying principle is that a disease-free venous bed can act as an alternative conduit, facilitating increased blood flow through existing collateral vessels to enhance tissue nutrition and stimulate angiogenesis. Various techniques for venous arterialization, including surgical, endovascular, or hybrid methods, have produced comparable results.[12] The success of these procedures is influenced by surgical techniques, the specific venous segments chosen for arterialization, the patient's clinical condition, and preoperative anatomical considerations. The

The publisher is not responsible for the content or functionality of any supporting information supplied by the authors. Any queries should be directed to the corresponding author for the article.
All claims expressed in this article are solely those of the authors and do not necessarily represent those of their affiliated organizations, or those of the publisher, the editors and the reviewers.
Any product that may be evaluated in this article or claim that may be made by its manufacturer is not guaranteed or endorsed by the publisher.

literature consistently reports improved clinical outcomes when arterialization is performed using deep venous vessels of the leg.[13,14] This approach proves to be particularly advantageous, as it not only enhances perfusion to compromised tissues but also leverages the larger network of outflow vessels associated with the deep venous system. By redirecting arterial blood flow into these veins, it is possible to significantly alleviate the ischemic conditions frequently experienced by patients suffering from critical limb ischemia.

The rationale behind this technique lies in the robust structure of the deep venous system, which can accommodate the increased blood flow necessary for delivering oxygen and nutrients to ischemic areas. Furthermore, arterializing the deep veins may reduce venous pressure, thereby enhancing venous return and mitigating complications associated with congestion and thrombosis.[15] The advantages of utilizing deep venous vessels also include promoting collateral circulation in surrounding tissues, which can further improve limb viability. However, the effectiveness of deep venous arterialization depends on the patency of the femoro-popliteal axis and pedal venous arch.[16] In a meta-analysis conducted by Lu *et al*., favorable outcomes were reported with venous arterialization, demonstrating over 70% foot preservation at one-year follow-up.[3] The outcomes of percutaneous Deep Vein Arterialization (DVA) have been documented in two key studies: the PROMISE I study, which focused on treating late-stage chronic limb-threatening ischemia, and the ALPS multicenter study which included sites in Alkmaar (Netherlands), Leipzig (Germany), Paris (France), and Singapore. Both studies aimed to assess amputation-free survival at 6 months as their primary outcome, with results showing 74% in the PROMISE I study and 84% in the ALPS study. Additionally, the ALPS study provided follow-up data extending to two years, revealing an amputation-free survival rate of

The publisher is not responsible for the content or functionality of any supporting information supplied by the authors. Any queries should be directed to the corresponding author for the article.
All claims expressed in this article are solely those of the authors and do not necessarily represent those of their affiliated organizations, or those of the publisher, the editors and the reviewers.
Any product that may be evaluated in this article or claim that may be made by its manufacturer is not guaranteed or endorsed by the publisher.

67% at that time. Impressively, the technical success rate achieved by the providers reached 97% across all cases.[17] Nonetheless, post-operative distal leg edema, a known complication, was still present in the reported case.

In the present case, the decision to utilize the GSV for arterialization was based on the necessity to revascularize the common femoral artery and the deep femoral artery through surgical intervention, allowing for arterialization of the GSV via the same surgical procedure. Valve destruction and dilation of venous stenosis were accomplished via drug-eluting balloon angioplasty. A 250 mm long balloon was selected to match the GSV segment that required dilation. DEB angioplasty was preferred to facilitate valve destruction and dilation of the GSV, as stenting was not feasible due to the vessel's size, which prevented the deployment of a stent. This strategy aims to minimize the risk of restenosis in the GSV, which may be characterized by both valves and focal stenosis. To our knowledge, this is the first reported case of concurrent dilation of arterialized GSV using DEB.

The literature outlines several strategies for foot revascularization through the superficial venous system. These include *In Situ* Reverse Arterialization (ISRA) of the venous bed, which preserves the distal saphenous side branches, and the creation of an anastomosis at the infragenicular level on the popliteal artery or the origin of the tibial artery. Additionally, devalvulation of the GSV can be performed using a valvulotome inserted from the distal end.[8,18] However, there have been no studies specifically focused on endovascular or hybrid revascularization that utilizes the saphenous vein. Migliara *et al*. reported a positive experience involving retrograded flow in the saphenous vein after bypassing the tibial artery with a stent to preserve the patency of the arteriovenous connection.[19,20] As research continues to advance,

The publisher is not responsible for the content or functionality of any supporting information supplied by the authors. Any queries should be directed to the corresponding author for the article.
All claims expressed in this article are solely those of the authors and do not necessarily represent those of their affiliated organizations, or those of the publisher, the editors and the reviewers.
Any product that may be evaluated in this article or claim that may be made by its manufacturer is not guaranteed or endorsed by the publisher.

the development of innovative techniques will be vital. Moreover, a multidisciplinary approach that incorporates the expertise of vascular specialists, interventional radiologists, and surgical teams will enhance patient care. The collective effort to explore effective pathways and methodologies for delivering treatment options to patients with CLTI is not only necessary but imperative. The overarching goal is to significantly improve patient outcomes by focusing on limb preservation, minimizing complications, and enhancing the quality of life for individuals affected by such debilitating conditions. Ultimately, the integration of advanced therapeutic strategies represents a paradigm shift in the management of this historically challenging condition. As we deepen our understanding of these complex treatments, the potential for transforming the landscape for CLTI patients becomes achievable.

Conclusions

In patients with critical ischemia, where traditional revascularization techniques may not be unfeasible or ineffective, the arterialization of the deep venous system presents a novel and promising alternative that merits further investigation and clinical consideration. Such innovations have the potential to significantly enhance treatment protocols and ultimately improve patient outcomes in this complex and challenging medical scenario. Currently, there is a lack of evidence regarding the efficacy of venous arterialization in patients with CLTI who have no other treatment options. Furthermore, there is no consensus on a standardized treatment strategy for venous arterialization, which remains largely a bailout procedure. This report presents the first available hybrid treatment approach, along with GSV arterialization and optimization via DEB angioplasty.

The publisher is not responsible for the content or functionality of any supporting information supplied by the authors. Any queries should be directed to the corresponding author for the article.
All claims expressed in this article are solely those of the authors and do not necessarily represent those of their affiliated organizations, or those of the publisher, the editors and the reviewers.
Any product that may be evaluated in this article or claim that may be made by its manufacturer is not guaranteed or endorsed by the publisher.

References

1. Pecoraro F, Pakeliani D, Bruno S, et al. Simultaneous hybrid treatment of multilevel peripheral arterial disease in patients with chronic limb-threatening ischemia. J Clin Med 2021;10:2865.
2. Radellini S, Vigneri E, Smeraldi L, et al. Evidence of greater severity of diabetic foot ulcers during COVID-19 pandemic: a real-life single-centre cohort study. Diabetes Metab Res Rev 2023;39:e3626.
3. Lu XW, Idu MM, Ubbink DT, Legemate DA. Meta-analysis of the clinical effectiveness of venous arterialization for salvage of critically ischaemic limbs. Eur J Vasc Endovasc Surg 2006;493-9.
4. Buerger L. Landmark publication from the American Journal of the Medical Sciences, “Thrombo-angiitis obliterans: a study of the vascular lesions leading to presenile spontaneous gangrene”. 1908. Am J Med Sci 2009;337:274-84.
5. Galyfos G, Liakopoulos D, Chamzin A, et al. A systematic review and meta-analysis of early and late outcomes after endovascular angioplasty among patients with thromboangiitis obliterans and chronic limb ischemia. J Vasc Surg 2023;77:1534-41.
6. Conte MS, Bradbury AW, Kolh P, White JV. Global vascular guidelines on the management of chronic limb-threatening ischemia. Eur J Vasc Endovasc Surg. 2019;69:36-125S-e.40.
7. Dinoto E, Ferlito F, Urso F, et al. Iliac-femoral stent-graft infection after hybrid procedure redo: case report. International Journal of Surgery Case Reports 2021;84:106096.
8. Schreve MA, Ünlü Ç, Kum S, Tan YK. Surgical and endovascular venous arterialization: ready to take the "desert" by storm? J Cardiovasc Surg (Torino). 2017;58:402-8.

The publisher is not responsible for the content or functionality of any supporting information supplied by the authors. Any queries should be directed to the corresponding author for the article.
All claims expressed in this article are solely those of the authors and do not necessarily represent those of their affiliated organizations, or those of the publisher, the editors and the reviewers.
Any product that may be evaluated in this article or claim that may be made by its manufacturer is not guaranteed or endorsed by the publisher.

9. Peeters Weem SM, Teraa M, de Borst GJ, et al. Bone marrow-derived cell therapy in critical limb ischemia: a meta-analysis of randomized placebo-controlled trials. Eur J Vasc Endovasc Surg 2015;50:775-83.
10. Abu Dabrh AM, Steffen MW, Asi N, et al. Nonrevascularization-based treatments in patients with severe or critical limb ischemia. J Vasc Surg. 2015;62:1330-9.
11. Ubbink DT, Vermeulen H. Spinal cord stimulation for non-reconstructable chronic critical leg ischaemia. Cochrane Database Syst Rev. 2013;2013:CD004001.
12. Ho V T, Gologorsky R, Kibrik P. Open, percutaneous, and hybrid deep venous arterialization technique for no-option foot salvage. Review. J Vasc Surg 2020;71:2152-60.
13. Clair DG, Mustapha JA, Shishehbor MH, et al. PROMISE I: early feasibility study of the LimFlow System for percutaneous deep vein arterialization in no-option chronic limb-threatening ischemia: 12-month results. J Vasc Surg 2021;74:1626-35.
14. Kum S, Tan YK, Schreve MA, et al. Midterm outcomes from a pilot study of percutaneous deep vein arterialization for the treatment of no-option critical limb ischemia. J Endovasc Ther 2017;24:619-26.
15. Choinski KN, Rao AG, Krishnan P, et al. Single center outcomes of percutaneous deep vein arterialization in patients with end-stage peripheral artery disease. Vasc Endovascular Surg 2024;58:548-53.
16. Smith JA, Kandala J, Turner JT, et al. Off-the-shelf percutaneous deep vein arterialization for no-option chronic limb-threatening ischemia related to Buerger disease. J Vasc Surg Cases Innov Tech 2023;9:101211.

The publisher is not responsible for the content or functionality of any supporting information supplied by the authors. Any queries should be directed to the corresponding author for the article.
All claims expressed in this article are solely those of the authors and do not necessarily represent those of their affiliated organizations, or those of the publisher, the editors and the reviewers.
Any product that may be evaluated in this article or claim that may be made by its manufacturer is not guaranteed or endorsed by the publisher.

17. Gupta A, Fadoul M, McMackin K, et al. Percutaneous deep vein arterialization using off-the-shelf devices for chronic limb threatening ischemia. J Vasc Surg Cases Innov Tech. 2023;9:101173.
18. Chayen D, Lorber J, Malic Z, et al. A new modified surgical technique of in situ reverse arterialization: leaving the distal saphenous side branches open of nonreconstructable ischemic leg leads to full recovery. Ann Vasc Surg 2019;61:472.e15-21.
19. Dinoto E, Pecoraro F, Ferlito F, et al. Multilevel diabetic foot revascularization in COVID 19 patient: case report. Int J Surg Case Rep. 2021;84:106132.
20. Migliara B, Cappellari TF, Mirandola M, et al. Percutaneous saphenous vein arterialization. J Endovasc Ther 2021;28:823-7.

The publisher is not responsible for the content or functionality of any supporting information supplied by the authors. Any queries should be directed to the corresponding author for the article.
All claims expressed in this article are solely those of the authors and do not necessarily represent those of their affiliated organizations, or those of the publisher, the editors and the reviewers.
Any product that may be evaluated in this article or claim that may be made by its manufacturer is not guaranteed or endorsed by the publisher.

Figure 1. Surgical preparation of the Dacron patch (Vascutek) before Great Saphenous Vein (GSV) anastomosis.

The publisher is not responsible for the content or functionality of any supporting information supplied by the authors. Any queries should be directed to the corresponding author for the article.
All claims expressed in this article are solely those of the authors and do not necessarily represent those of their affiliated organizations, or those of the publisher, the editors and the reviewers.
Any product that may be evaluated in this article or claim that may be made by its manufacturer is not guaranteed or endorsed by the publisher.

Figure 2. Termino-lateral anastomosis between the Great Saphenous Vein (GSV) and the Dacron patch (Vascutek).

The publisher is not responsible for the content or functionality of any supporting information supplied by the authors. Any queries should be directed to the corresponding author for the article.
All claims expressed in this article are solely those of the authors and do not necessarily represent those of their affiliated organizations, or those of the publisher, the editors and the reviewers.
Any product that may be evaluated in this article or claim that may be made by its manufacturer is not guaranteed or endorsed by the publisher.

Figure 3. Antegrade 0.035 PTFE coated guidewire positioning through Great Saphenous Vein (GSV) collateral.

The publisher is not responsible for the content or functionality of any supporting information supplied by the authors. Any queries should be directed to the corresponding author for the article.
All claims expressed in this article are solely those of the authors and do not necessarily represent those of their affiliated organizations, or those of the publisher, the editors and the reviewers.
Any product that may be evaluated in this article or claim that may be made by its manufacturer is not guaranteed or endorsed by the publisher.

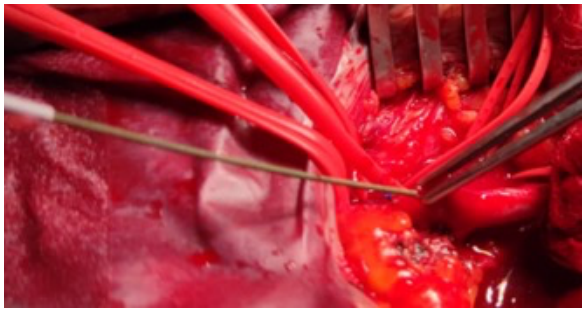

Figure 4. Over the wire 6F sheath (Cordis, Santa Clara, CA, US) through the Great Saphenous Vein (GSV) collateral.

The publisher is not responsible for the content or functionality of any supporting information supplied by the authors. Any queries should be directed to the corresponding author for the article.
All claims expressed in this article are solely those of the authors and do not necessarily represent those of their affiliated organizations, or those of the publisher, the editors and the reviewers.
Any product that may be evaluated in this article or claim that may be made by its manufacturer is not guaranteed or endorsed by the publisher.

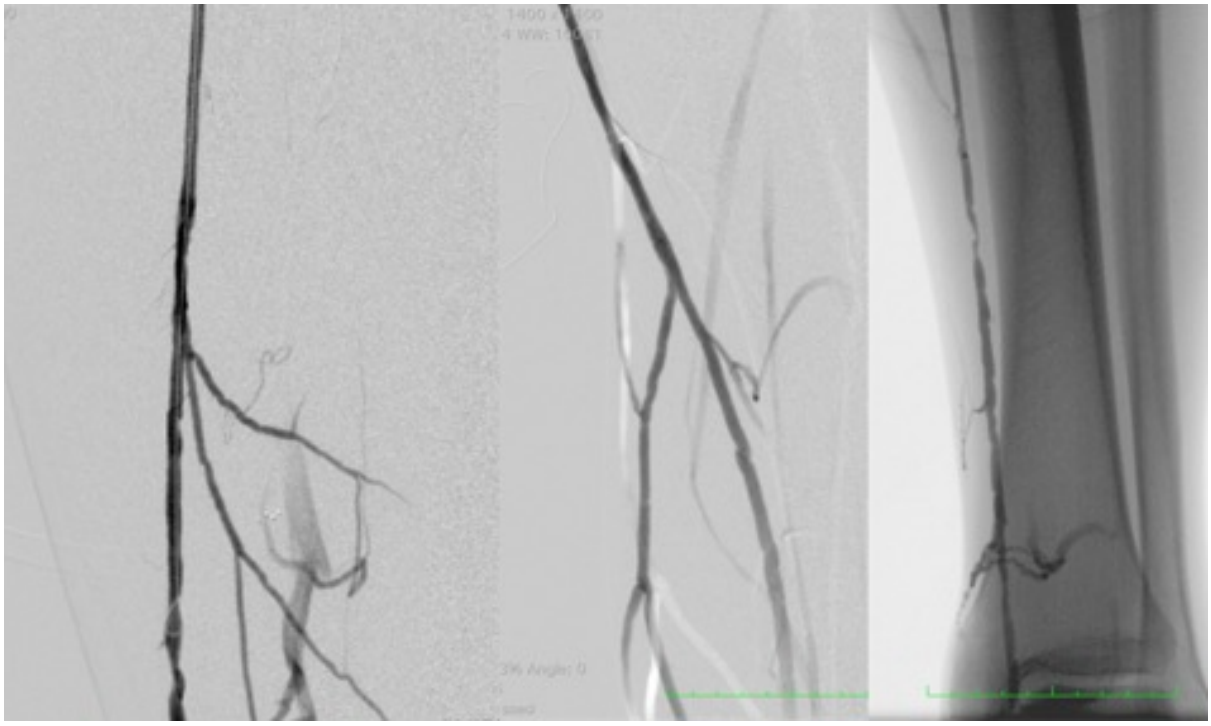

Figure 5. Initial angiography showing multiple Great Saphenous Vein (GSV) stenoses and significant collaterals at the level of the thigh.

The publisher is not responsible for the content or functionality of any supporting information supplied by the authors. Any queries should be directed to the corresponding author for the article.
All claims expressed in this article are solely those of the authors and do not necessarily represent those of their affiliated organizations, or those of the publisher, the editors and the reviewers.
Any product that may be evaluated in this article or claim that may be made by its manufacturer is not guaranteed or endorsed by the publisher.

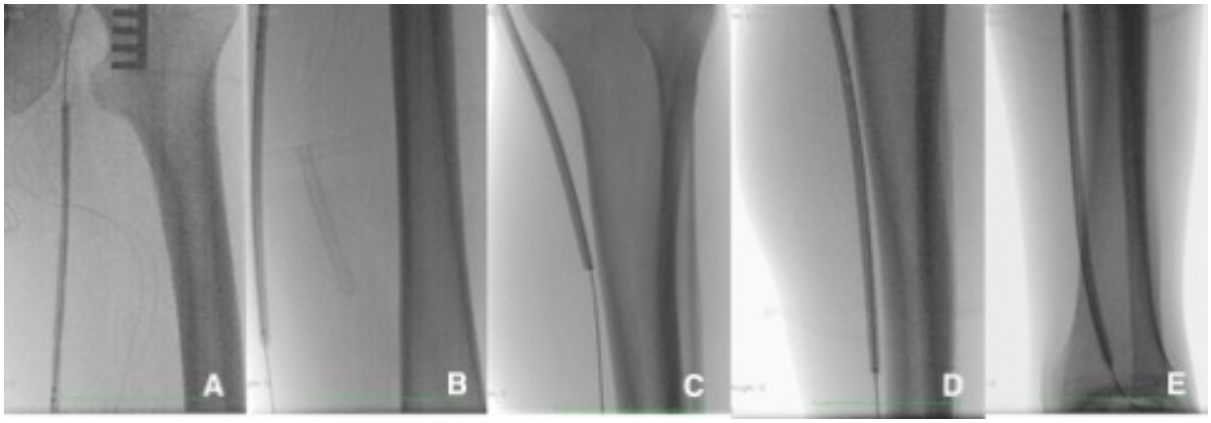

Figure 6. Great Saphenous Vein (GSV) angioplasty carried out using a 5.0x250 mm paclitaxel-coated PTA Balloon Catheter (Admiral Xtreme) thigh segment (A, B), leg segment (C, D, E).

The publisher is not responsible for the content or functionality of any supporting information supplied by the authors. Any queries should be directed to the corresponding author for the article.
All claims expressed in this article are solely those of the authors and do not necessarily represent those of their affiliated organizations, or those of the publisher, the editors and the reviewers.
Any product that may be evaluated in this article or claim that may be made by its manufacturer is not guaranteed or endorsed by the publisher.

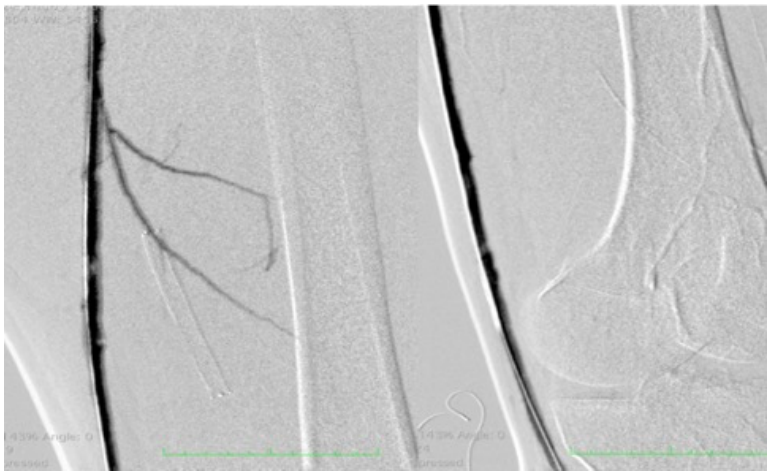

Figure 7. Control angiography showing Great Saphenous Vein (GSV) patency with no residual stenoses.

The publisher is not responsible for the content or functionality of any supporting information supplied by the authors. Any queries should be directed to the corresponding author for the article.
All claims expressed in this article are solely those of the authors and do not necessarily represent those of their affiliated organizations, or those of the publisher, the editors and the reviewers.
Any product that may be evaluated in this article or claim that may be made by its manufacturer is not guaranteed or endorsed by the publisher.

Figure 8. Great Saphenous Vein (GSV) thigh collaterals after GSV angioplasty.

The publisher is not responsible for the content or functionality of any supporting information supplied by the authors. Any queries should be directed to the corresponding author for the article.
All claims expressed in this article are solely those of the authors and do not necessarily represent those of their affiliated organizations, or those of the publisher, the editors and the reviewers.
Any product that may be evaluated in this article or claim that may be made by its manufacturer is not guaranteed or endorsed by the publisher.