

## PHOTO QUIZ

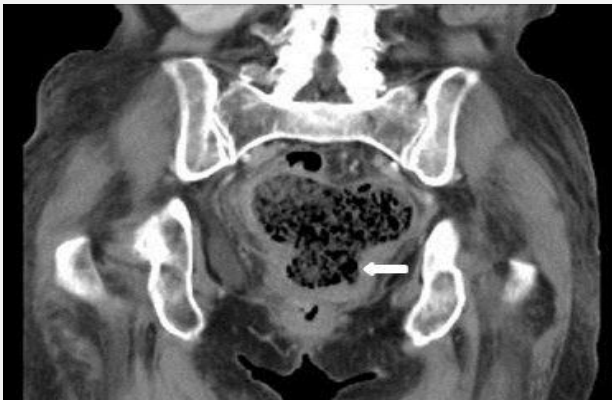## A 78-Year-Old Woman with Fecaloid Vaginal Discharge

Yuh-Feng Tsai<sup>1</sup>, Wei-Yu Chen<sup>2</sup>, Chung-Fang Chiao<sup>3</sup>, Tzong-Luen Wang<sup>4,5</sup>, Aming Chor-Ming Lin<sup>3,4,5\*</sup>

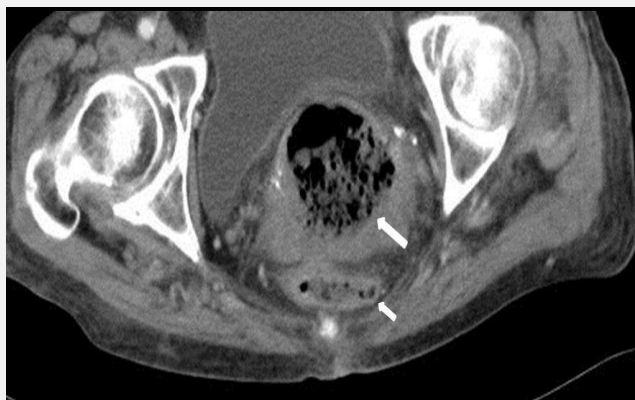
1. Department of Diagnostic Radiology, Shin Kong Wu Ho-Su Memorial Hospital, Taipei, Taiwan.
2. Division of Infectious Diseases, Shin Kong Wu Ho-Su Memorial Hospital, Taipei, Taiwan.
3. Department of Intensive Care Unit, Shin Kong Wu Ho-Su Memorial Hospital, Taipei, Taiwan.
4. Emergency Department, Shin Kong Wu Ho-Su Memorial Hospital, Taipei, Taiwan.
5. School of Medicine, Fu-Jen Catholic University, New Taipei City, Taiwan.

\*Corresponding Author: Aming Chor-Ming Lin; Emergency Department, Shin Kong Wu Ho-Su Memorial Hospital, 95 Wen Chang Rd, Taipei 111, Taiwan.  
Tel: +886-02-28332211 Ext 2082; Fax: +886-02-28353547; E-mail: M002001@ms.skh.org.tw

Received: April 2015; Accepted: June 2015



**Figure 1:** Coronal view of patient's abdominopelvic computed tomography.



**Figure 2:** Axial view of patient's abdominopelvic computed tomography.

**Case presentation:**

**A** 78-year-old woman with a history of colon cancer with metastasis to the liver was presented to our emergency department because of bilateral groin pain and difficulty in walking, which had gradually increased during the previous 5 days. The pain was of sudden onset, radiating to the back, without aggravating or relieving factors. It was associated with constipation, dysuria and vaginal discharge. She reported passing fecal matter from the vagina one month ago. On physical examination, she appeared malnourished. Her blood pressure was 98/65 mmHg, with a 108 beats/min heart rate and 28 breaths/min respiratory rate. She was afebrile. Physical examinations were unremarkable, except for pale conjunctiva, abdominal distention, and diffuse tenderness especially over the umbilicus with guarding tenderness. Bowel sounds were decreased. Pelvic examination showed a yellowish odorous vaginal discharge

from the external orifice of uterus. A complete blood cell count showed the following: leukocyte count, 34,200/mm<sup>3</sup>; segmented neutrophils, 87.5%; hemoglobin level of 7.4 mg/dl; hematocrit, 18.8%; and platelet, 180000/uL. Other laboratory studies included: glucose, 86 mg/dL; serum urea nitrogen, 28 mg/dL; serum creatinine, 0.87 mg/dL; sodium, 142 mEq/L; potassium, 4.8 mEq/L; albumin, 2.5g/dL; a carbohydrate antigen 19-9 level of 3,244 U/ml, and a carcinoembryonic antigen (CEA) level of 64.6 ng/ml. Coronal and axial cuts of patient's abdominopelvic computed Tomography (CT) are shown in figures 1 and 2.

**What is your diagnosis?**

**Diagnosis:**

CT of the abdomen and pelvis showed severely distended uterine containing air bubble and fecal material that were consistent with diagnosis of colouterine fistula.

**Case fate:**

Considering the patient's malignancy, associated comorbidities, and lack of signs of peritonitis, the patient denied colostomy. She was kept fasting and started on partial parenteral nutrition and intravenous antibiotics. She was admitted with plans for hospice care and died 12 days later.

**Discussion:**

Colon cancer associated fistula formation is a relatively rare complication. The most common type of fistula is a colovesical fistula followed by a colovaginal fistula arising from the sigmoid colon (1, 2). Colouterine fistula formation secondary to colon cancer is an extremely rare complication because of the uterus being a thick muscular organ. A colouterine fistula was first reported by Lejemtel in 1909 (3). Three main etiologies including uterine trauma, presence of abscess rupture into the bowel and the uterus, and uterine or sigmoid carcinoma have been described. A colouterine fistula might be caused by the spontaneous rupture of a gravid uterus, uterine or sigmoid colon cancer, radiotherapy, polymyomectomy, and foreign body (4-6). Diverticulitis or malignancy of the sigmoid colon can present as pyometra. Clinical manifestations of colovaginal and colouterine fistulas may be similar (7). Colon cancer may invade the uterine with subsequent abscess formation that results in colouterine fistula formation. Fistula formation by colonic cancer occurs when a tumor extends or ruptures into an adjacent organ such as bladder, small bowel or vagina (8, 9). CT is routinely performed for diagnosis in patients with a suspected colouterine fistula. In a colouterine fistula, air bubbles in the uterine cavity and colon wall joined to the uterus may be identified in CT findings (7). Colouterine fistula secondary to sigmoid cancer is a very rare condition. Colouterine fistula can present with malodorous vaginal discharge. Acute abdomen is now most commonly evaluated by CT in the emergency department. The diagnosis is easily made with clinical history and abdominopelvic CT scan, which reveal the presence of an extraluminal gas collection

within the uterine (4, 9).

**Conclusion:**

Fecal vaginal discharge may be indicative of a colouterine or a colovaginal fistula. Patients often present with passage of gas, malodorous fecal or purulent vaginal discharge for days or months. Diagnosis depends on a high index of suspicion. It should be suspected in any patient with a persistent vaginal discharge.

**Acknowledgments:**

We would like to express our special thanks to Shin Kong Wu Ho-Su Memorial Hospital staff.

**Conflict of interest:**

None

**Funding support:**

None

**Authors' contributions:**

All authors passed four criteria for authorship contribution based on recommendations of the International Committee of Medical Journal Editors.

**References:**

1. Woods RJ, Lavery IC, Fazio VW, Jagelman DG, Weakley FL. Internal fistulas in diverticular disease. *Dis Colon Rectum*. 1988;31(8):591-6.
2. Foulatier O, Verspyck E, Roman H, Scotté M. Colouterine fistula complicating diverticulitis: a case report and review of the literature. *Eur J Obstetr Gynecol Reproduct Biol*. 2003;110(1):107-10.
3. Chaikof EL, Cambria RP, Warshaw AL. Colouterine fistula secondary to diverticulitis. *Dis Colon Rectum*. 1985;28(5):358-60.
4. Halevy A, Bracha M, Jeroukhimov I, Schneider D, Nesterenko V. En bloc resection for malignant colouterine fistula. *Tech Coloproctol*. 2010;14(1):37-9.
5. Uzan J, Koskas M, Fournier P, Margulies AL, Luton D, Yazbeck C. Colouterine fistula after polymyomectomy: a case report. *J Med Case Reports*. 2014;8(1):199.
6. Islam A, Arif S. Colouterine fistula with a foreign body. *J Ayub Med Coll Abbottabad*. 2010;22(2):205-7.
7. Blumetti J, Harrison J, Abcarian H. Diverticular Fistulas to the Female Reproductive Tract: Colouterine and Colosalpingo-ovarian Fistulas. *Am Surg*. 2015;81(2):E50-1.
8. Kiani QH, George ML, Carapeti EA, Schizas AM, Williams AB. Colovesical fistula: should it be considered a single disease? *Ann Coloproctol*. 2015;31(2):57-62.
9. Shimamura T, Kokuba Y, Yube Y, et al. Sigmoid colon diverticulosis with stenosis: case report and review of the Japanese literature. *J St Marianna Uni*. 2014;5(2):117-24.

