

# Surgical dental treatment prior to liver transplantation

Paulo Sérgio da Silva Santos<sup>1</sup>, Maria Izabel Sarmiento e Souza Pacheco<sup>2</sup>,  
Mateus Pereira Alonso Soler<sup>3</sup>, Valtuir Barbosa Felix<sup>4</sup>

<sup>1</sup>DDS, MD, PhD, Department of Stomatology, Bauru School of Dentistry, University of São Paulo, Brazil

<sup>2</sup>DDS, Department of Oral and Maxillofacial Surgery, Santa Casa de Misericórdia of São Paulo, São Paulo, Brazil

<sup>3</sup>DDS, Department of Oral and Maxillofacial Surgery, Hospital Regional Sul, São Paulo, Brazil

<sup>4</sup>DDS, MD, PhD, Department of Oral and Maxillofacial Surgery, Hospital Regional of Osasco, São Paulo, Brazil

## Abstract

Oral-source infections are a potential threat for transplant candidates because oral diseases tend to be more severe and untreated in people who have received transplants. Although not yet scientifically proven, evaluation and dental treatment during the pre-transplantation period is recommended in order to prevent infections and resultant odontogenic-origin sepsis during the post-transplant period, when patients receive immunosuppressive therapy. **Aim:** To evaluate the invasive dental procedures for removing dental foci performed in patients scheduled for liver transplantation and its accompanying complications. **Methods:** The medical records of 33 pre-liver transplant recipients who were undergoing invasive dental procedures were reviewed, including their laboratory tests, special handling needs and resulting complications. **Results:** Fifty invasive dental procedures were carried out on the 33 patients. Three of them were subjected to basic periodontal treatment and 47 were subjected to multiple or simple extractions. Three surgical procedures resulted in postoperative complications. **Conclusions:** Surgical intervention to remove dental foci in liver disease patients requires careful clinical evaluation, laboratory tests, knowledge and skills in the use of local and systemic hemostatic procedures, and a partnership approach between dentists and physicians, in order to reduce the risk of complications.

**Keywords:** surgery, oral, hemostatic techniques, organ transplantation.

## Introduction

Dental treatment, including the elimination of oral and mucosal infection foci, is essential for transplant patients during both preparation and post-surgery periods; patients should be under constant dental care and undergo mycological tests, especially in the first months<sup>1-5</sup>. Oral-source infections are a potential threat to transplant candidates because oral diseases tend to be more severe if left untreated in people who have received transplants<sup>3,6</sup>. Although no evidence-based guidelines for dental septic focal treatment exist, patients should be advised to have dental foci removed before undergoing organ transplants in order to avoid post-transplant systemic and local oral complications. In addition, these patients should be organized into a dental or oral maxillofacial surgical follow-up program<sup>7</sup>.

Teeth that need to be restored but are impossible to treat, as well as those with advanced periodontal disease, must be extracted. Non-vital teeth (at risk of

Received for publication: May 26, 2011

Accepted: December 07, 2011

### Correspondence to:

Paulo Sérgio da Silva Santos  
Departamento de Estomatologia, FOB/USP  
Alameda Octávio Pinheiro Brisolla,  
9-75,17012-901 Bauru-SP  
Phone: +55 14 3235-8373,  
FAX: +55 14 3235-8000.  
E-mail: paulosss@fob.usp.br

infection) must be extracted or endodontically treated, and all active caries lesions should be treated and resulting cavities should be restored<sup>8</sup>. For any type of oral surgery, the patient must have an intact hemostatic process because even the least invasive procedures can lead to severe bleeding, increased risk of infection, poor wound healing and airways may be compromised if there is bleeding in critical fascial spaces<sup>9</sup>.

Any liver disease that affects the synthesis of clotting factors may manifest itself by an increase of prothrombin time (PT), which reflects the extrinsic pathway for the coagulation mechanism. The activated partial thromboplastin time (APTT) reflects all clotting factors except platelet factor III and factors XIII and VII and is indicative of the function of the coagulation mechanism's intrinsic pathway. Therefore, before any surgical procedure, the preoperative evaluation of these patients must include a complete blood count (CBC), PT, international normalized ratio (INR) and APTT<sup>9</sup>. This research aimed at evaluating invasive dental procedures for removing dental foci in patients scheduled for liver transplantation along with any accompanying complications.

## Material and methods

After approval by the Research Ethics Committee for the Santa Casa de Misericórdia de São Paulo, this study evaluated 33 prospective patients who were candidates for liver transplants and had been receiving treatment in a dentistry department for patients with special needs, during 3 years, according to the indication/medical records maintained by the liver transplant team. All potential candidates in the liver transplant program from regional Hospital of São Paulo, Brazil, during this period were included in the study.

The 33 selected patients consisted of 25 (75.8%) males and 8 (24.2%) females, with a mean age of 53.15 years. They underwent clinical, radiographic (panoramic and periapical x-rays) and laboratory (CBC, PT/INR, APTT) examinations for diagnosis and planning of dental treatment, totalizing 50 procedures.

Tooth extraction criteria were: presence of residual roots; extensive carious lesions with partial crown destruction and risk of pulpal involvement; teeth with periapical lesions; semi-erupted teeth; teeth with periodontal involvement; as well as the capacity and interest of the patient in caring for and maintaining oral hygiene. The periodontal treatment consisted of scaling and root planing divided into several sections, starting from the supra-gingival area, gingival and subgingival level for cases of mild to moderate periodontitis, and prescription of 5% tranexamic acid mouthwash three times a day during 7 days.

Patients were subjected to oral surgery for dental extraction to remove odontogenic foci, and received systemic antifibrinolytic therapy according to laboratory parameters INR > 3.0, APTT > 60 sec and platelet count < 30,000 cells/ $\mu$ L). Local hemostasis techniques, applied to all patients, consisted of: application of a tranexamic acid paste

(macerated pill mixed with saline or anesthetic solution) in order to fill the alveolar socket after dental extractions; the placement of fibrin sponge that was properly trimmed and well adapted to the alveolar socket<sup>10</sup>; suture with maximum coaptation of the gingival edge and application of another layer of tranexamic acid paste applied to the wound<sup>11</sup>. The systemic hemostasis technique consisted of the administration of blood derivatate or tranexamic acid<sup>12</sup> (500 mg, 3 times day), starting 2 days before the procedure and ending 3 days after.

## Results

Fifty invasive dental procedures were carried out on the 33 patients. Three of them were subjected to basic periodontal treatment and 47 were subjected to multiple (2 or more teeth, n = 39) or single (1 tooth, n = 8) extractions. Three invasive procedures resulted in postoperative complications: 1 (3.03%) single post-extraction infectious alveolitis and 2 (6.06%) cases of postoperative bleeding as a result of a simple extraction and a multiple extraction (Table 1). Evidence of poor oral hygiene in this group of patients was clearly demonstrated by the number of tooth extractions needed.

All patients had altered laboratory results (CBC – platelet count, PT/INR, APTT/RT), consistent with the clinical status of end-stage liver disease.

The only infectious complication was a dry socket, which was treated by removing sutures, intra-alveolar curettage and application of zinc oxide and eugenol paste<sup>13</sup>. The hemorrhagic complications were treated by removal of sutures, intra-alveolar curettage, irrigation with saline and 2% chlorhexidine, application of tranexamic acid paste in the alveolar socket, fibrin sponge placement, suture, application of another layer of tranexamic acid paste and daily monitoring within the first 72 h postsurgery.

## Discussion

Although there are no evidence-based guidelines for dental septic focal treatment, patients should be advised to have their dental foci removed before undergoing organ transplants and receiving immunosuppressive therapy.

Meticulous clinical examination, including extraoral and intraoral, and radiographic examinations (panoramic and periapical x-rays) are important to find infectious foci and to establish the diagnosis and the development of an adequate treatment plan. These examinations are all part of the protocol for pre-organ-transplant dental evaluation.

Laboratory assessment before dental surgery, which includes blood cell count, PT, APTT and platelet count, is mandatory for assessing the risk of bleeding during surgery or in the postoperative period, and provides the dentist and the medical team with guidance parameters that will demonstrate if there is risk of surgical or clinical complications during the monitoring of this group of patients (Figure 1).

The patients in this study sample had poor oral conditions, with the presence of plaque and calculus, periodontitis, extensive carious lesions, residual roots,

**Table 1** - Data from the gender, diagnosis and laboratory evaluation of liver transplant candidates, and total procedures and complications during the dental management.

PATIENT	GENDER	DIAGNOSIS	PT	PA	INR	APTT	PLATELETS	PROCEDURES PERFORMED	COMPLICATIONS
1	F	Cirrhosis	23.6	43	1.77	43.3	70	Extractions - 22, 34	None
2	M	Wilson Disease	19	27	2.79	62.5	62	Extractions -55, 65	None
3	M	Cirrhosis	20	40	1.88	33.6	149	Extractions - 21, 22, 24	None
4	F	Cirrhosis	17.8	55	1.47	35.5	59	Extractions - 31, 32, 41, 43	None
5	F	Cirrhosis	20.3	59	1.49	39	95.1	Extraction - 35	None
6	M	Cirrhosis	21.5	45	1.57	43.2	53	Extractions - 12, 15	Hemorrhage
7	M	Cirrhosis	22.5	51	1.67	35.5	27	Extraction - 16	None
8	M	Cirrhosis	29.7	36	2.25	40.9	67.1	Extraction - 17	Alveolitis
9	M	Cirrhosis + Diabetes	21.9	44	1.6	41	75.1	Extractions - 26, 27, 47	None
10	M	Cirrhosis	17.6	65	1.26	32.4	105	Extractions - 14, 17, 24	None
11	M	Cirrhosis	21.6	54	1.6	38.8	64.9	Extractions - 13, 24, 26, 27	None
12	M	Cirrhosis	15	84	1.1	26.7	75	Extraction - 17	None
13	M	Cirrhosis	18.9	57	1.4	33.3	70	Extractions - 14, 15, 16, 18, 44	None
14	M	Cirrhosis	16.7	68	1.24	32.5	98	Extractions - 11, 12, 13, 15, 16, 17, 21, 22, 23, 24, 25, 26, 27, 31, 32, 33, 34, 41, 42, 43, 44, 45	None
15	F	Liver Steatosis	14	100	1	24.4	220	Extractions - 11, 12, 13, 21, 22, 23	None
16	M	Cirrhosis	18.6	56	1.39	36.3	96	Extractions - 27, 28, 46	None
17	M	Cirrhosis	20.4	48	1.54	40.6	105	Extractions - 11, 15, 25	None
18	M	Sclerosing Cholangitis	15.2	82	1.11	30.1	126	Extractions - 25, 44	None
19	M	Cirrhosis	19.5	52	1.47	30.6	128	Extraction - 18	None
20	M	Cirrhosis	21	50	1.59	39.3	64.3	Extractions - 32, 33, 34, 43, 44	None
21	M	Cirrhosis	16.7	71	1.24	41.8	132	Extractions - 11, 21	None
22	F	Hepatitis C	18.6	60	1.39	34.7	57.1	Extraction - 37	None
23	F	Autoimmune Hepatitis	16.1	75	1.19	28	120	Extractions - 52, 53	None
24	M	Hepatitis C	17.5	66	1.3	36.5	53	Extractions - 31, 32, 33, 41, 42, 43	None
25	M	Cirrhosis	16.5	65	1.24	30.5	132	Extractions - 11, 13, 16, 17, 21, 23, 27, 31, 32, 33, 34, 35, 41, 42, 43, 44, 45	None
26	F	Cirrhosis	15.6	73	1.18	30.2	264	Extractions - 15, 16	None
27	M	Cirrhosis	20.9	49	1.57	41	89	Extractions - 17, 26, 27	None
28	M	Hepatitis c	14.8	87	1.09	31.8	149	Extractions - 36, 34, 33, 32, 31, 41, 42, 43, 44, 45	None
29	M	Cirrhosis	23.1	43	1.79	39.2	41	Extraction - 47	Hemorrhage
30	M	Cirrhosis	19	57	1.42	31.2	103	Extraction - 18	None
31	M	Wilson Disease	15.4	44	2.04	48.1	32	Scaling and Root Planing	None
32	F	Cirrhosis	12.2	71	1.31	36.3	152	Scaling and Root Planing	None
33	M	Cirrhosis	16.9	31	2.46	51.6	83	Scaling and Root Planing	None

Abbreviations: Prothrombin Time (PT), Prothrombin Activity (PA), International Normalized Ratio (INR), Activated Partial Thromboplastin Time (APTT)

infection by *Candida* and xerostomia. Radiographic examination revealed periapical lesions, unerupted teeth, and alveolar ridge resorption due to periodontitis. These clinical and radiographic findings are consistent with our research findings, which show that liver disease patients are in large part, consumers of alcohol and tobacco, and have poor oral hygiene<sup>5,14</sup>. Strategies for improving the preventive dental care are needed<sup>15</sup> for this group and the role of the multidisciplinary team is essential<sup>16</sup>.

In this study sample, despite the significantly altered laboratory tests and surgical procedures carried out, the rate of complications after dental surgical procedures in the liver transplant candidates (6.06%) was lower than that found by Niederhagen et al. (2003)<sup>17</sup> (15.4%) and fairly consistent with

that found by Stanca et al. (2010)<sup>18</sup> (5%). The few complications were of hemorrhagic and infectious nature and were easily controlled. Our results suggest that proper surgical techniques associated with local and systemic haemostatic procedures are effective in preventing complications associated with coagulation disorders that liver disease patients may develop. Of the 33 patients in this study, 2 had previously received blood transfusions, and 31 patients were treated only with local hemostatic maneuvers. In two cases, when bleeding during surgery was greater than expected, a successful intravenous administration of vitamin K was carried out.

The reduction in salivary flow and the presence of candidiasis found in some patients may be associated with the use of diuretics for the treatment of ascites and edema,

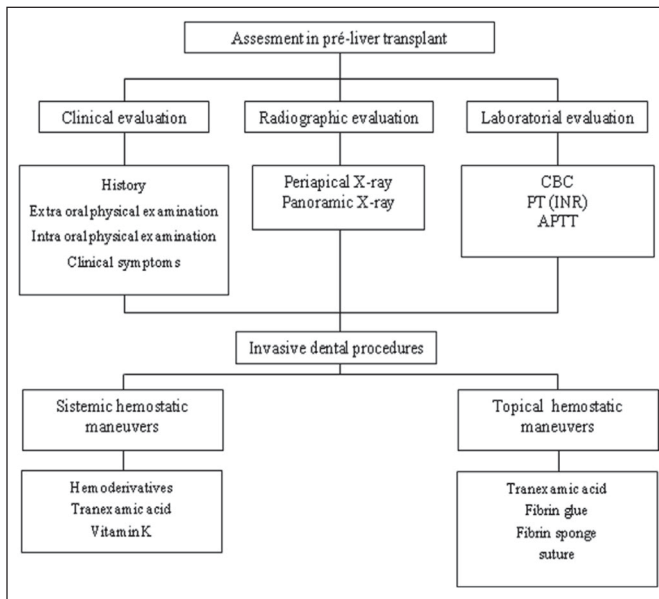


Fig. 1. Algorithm criteria for dental care to patients scheduled for liver transplantation

frequent complications of cirrhosis, which increases the deposition and retention of plaque as well as the susceptibility of opportunistic infections. This condition requires special attention from the dental professional to prevent and treat opportunistic infections.

Solid organ transplant patients have a high risk of developing squamous cell carcinoma of the upper digestive tract, which is also associated with prolonged use of immunosuppressant drugs, but it is primarily attributed to smoking<sup>5</sup>. This condition requires special care when monitoring these patients in the post-transplant period.

Most patients in this study reported not having received any dental monitoring because dental professionals reported lack of knowledge on management techniques and treatment of liver disease and transplant patients. This fact corroborates the findings of Guggenheimer et al. (2007)<sup>4</sup>, who studied patients undergoing liver transplant<sup>5</sup>. The need for radical prophylactic dental sanitation should be further studied so that appropriate protocols are established for these patients.

In conclusion, the surgical intervention to remove dental foci in liver disease patients requires careful clinical evaluation, laboratory tests, knowledge and skills in the use of local and systemic hemostatic maneuvers, and a well established partnership approach between dentists and physicians in order to maintain a low risk of complications.

## Acknowledgements

We thank the Santa Casa de Misericórdia de São Paulo for the assistance given to us throughout our research.

## References

1. Wakefield CW, Thronson RR, Brock T. Liver transplantation: dentistry is an essential part of the team. *J Tenn Dent Assoc.* 1995; 75: 9-16.

2. Douglas LR, Douglass JB, Sieck JO, Smith PJ. Oral management of the patient with end-stage liver disease and the liver transplant patient. *Oral Surg Oral Med Oral Pathol Oral Radiol Endod.* 1998; 86: 55-64.
3. Guggenheimer J, Mayher D, Eghtesad B. A survey of dental care protocols among US organ transplant centers. *Clin Transplant.* 2005; 19: 15-8.
4. Guggenheimer J, Eghtesad B, Close JM, Shay C, Fung JJ. Dental health status of liver transplant candidates. *Liver Transpl.* 2007; 13: 280-6.
5. Golecka M, Mierzwińska-Nastalska E, Oldakowska-Jedynak U. Influence of oral hygiene habits on prosthetic stomatitis complicated by mucosal infection after organ transplantation. *Transplant Proc.* 2007; 39: 2875-8.
6. Ribeiro PM, Bacal F, Koga-Ito CY, Junqueira JC, Jorge AO. Presence of *Candida* spp. in the oral cavity of heart transplantation patients. *J Appl Oral Sci.* 2011; 19:6-10.
7. Rustemeyer J, Bremerich A. Necessity of surgical dental foci treatment prior to organ transplantation and heart valve replacement. *Clin Oral Investig.* 2007; 11: 171-4.
8. Little JW, Rhodus NL. Dental treatment of the liver transplant patient. *Oral Surg Oral Med Oral Pathol.* 1992; 73: 419-26.
9. Ziccardi VB, Abubaker AO, Sotereanos GC, Patterson GT. Maxillofacial considerations in orthotopic liver transplantation. *Oral Surg Oral Med Oral Pathol.* 1991; 71: 21-6.
10. Medeiros FB, de Andrade AC, Angelis GA, Conrado VC, Timerman L, Farsky P, et al.. Bleeding evaluation during single tooth extraction in patients with coronary artery disease and acetylsalicylic acid therapy suspension: a prospective, double-blinded, and randomized study. *J Oral Maxillofac Surg* 2011; 69: 2949-55.
11. Hewson I, Makhmalbaf P, Street A, McCarthy P, Walsh M. Dental surgery with minimal factor support in the inherited bleeding disorder population at the Alfred Hospital. *Haemophilia.* 2011; 17: e185-8.
12. Givol N, Goldstein G, Peleg O, Shenkman B, Zimran A, Elstein D, et al.. Thrombocytopenia and bleeding in dental procedures of patients with Gaucher disease. *Haemophilia.* 2011; May 5. doi: 10.1111/j.1365-2516.2011.02540.x. [Epub ahead of print]
13. Oginni FO, Fatusi OA, Alagbe AO. A clinical evaluation of dry socket in a Nigerian teaching hospital. *J Oral Maxillofac Surg.* 2003; 61: 871-6.
14. Lins L, Bittencourt PL, Evangelista MA, Lins R, Codes L, Cavalcanti AR, et al.. Oral health profile of cirrhotic patients awaiting liver transplantation in the Brazilian Northeast. *Transplant Proc.* 2011; 43: 1319-21.
15. Shiboski CH, Kawada P, Golinveaux M, Tornabene A, Krishnan S, Mathias R, et al.. Oral disease burden and utilization of dental care patterns among pediatric solid organ transplant recipients. *J Public Health Dent.* 2009; 69: 48-55.
16. Gelb B, Feng S. Management of the liver transplant patient. *Expert Rev Gastroenterol Hepatol.* 2009;3: 631-47.
17. Niederhagen B, Wolff M, Appel T, von Lindern JJ, Bergé S. Location and sanitation of dental foci in liver transplantation. *Transpl Int.* 2003; 16: 173-8.
18. Stanca CM, Montazem AH, Lawal A, Zhang JX, Schiano TD. Intranasal desmopressin versus blood transfusion in cirrhotic patients with coagulopathy undergoing dental extraction: a randomized controlled trial. *J Oral Maxillofac Surg.* 2010; 68: 138-43.