

Coccidiosis due to *Isoospora curio* (Trachta & Silva et al. 2006) in lesser seed-finches *Sporophila angolensis* (Linnaeus, 1766) at a commercial breeding facility - Case report*

Lilian C. de S. O. Batista¹⁺, Marcelo dos S. D. Vasconcellos², Matheus M. dos Passos², Bruno do B. Lopes³ and Bruno P. Berto⁴

ABSTRACT. Batista L.C. deS.O., Vasconcellos M. dosS.D., dos Passos M.M., Lopes B. doB. & Berto B.P. **Coccidiosis due to *Isoospora curio* (Trachta & Silva et al. 2006) in lesser seed-finches *Sporophila angolensis* (Linnaeus, 1766) at a commercial breeding facility - Case report.** [Coccidiose por *Isoospora curio* (Trachta & Silva et al. 2006) (Apicomplexa: Eimeriidae) em *Sporophila angolensis* (Linnaeus, 1766) numa criação comercial - Relato de caso]. *Revista Brasileira de Medicina Veterinária*, 37(4):401-405, 2015. Curso de Pós-Graduação em Ciências Veterinárias, Instituto de Veterinária, Universidade Federal Rural do Rio de Janeiro, *Campus Seropédica*, BR 465 Km 7, Seropédica, RJ 23890-000, Brasil. E-mail: liliancsobatista@hotmail.com

Monitoring of a lesser seed-finch breeding is of great importance, for even the clinically healthy animals may be infected. When coccidiosis is diagnosed early, it can often be avoided clinical signs of the disease and the number of deaths in the breeding when associated with hygiene practices in the breeding system. Despite of the low frequency of coccidiosis in the studied passerines, *Isoospora curio* was the unique species found associated with passerines that died in the commercial breeding facility.

KEY WORDS. Coccidiosis, *Isoospora curio*, commercial breeding.

RESUMO. O monitoramento de um plantel é de grande importância, pois mesmo os animais clinicamente saudáveis podem estar parasitados. Quando a coccidiose é diagnosticada precocemente, frequentemente podem-se evitar os sinais clínicos da doença e o número de óbitos no criatório quando for associado às práticas de higiene na criação. Apesar da baixa frequência da coccidiose nos animais estudados, a única espécie encontrada foi *Isoospora curio* associada aos animais que vieram a óbito na criação comercial.

PALAVRAS-CHAVE. Coccidiose, *Isoospora curio*, criação comercial.

INTRODUCTION

The Passeriformes order is the largest order of Aves. This order has small birds with many colors and different vocal repertoires. Among the songbirds of this order, the lesser seed-finches *Sporophila angolensis* (Linnaeus, 1766) are considered one of the most important. This characteristic makes this species one of the most appreciated in Brazil and many of them have been kept in commercial breeding (Coutteel 2003, Trachta & Silva et al. 2006, Sigris 2013, Wikiaves 2015).

Among the parasitic diseases that affect birds

*Received on June 3, 2015.

Accepted for publication on 28 de agosto de 2015.

¹ Médica-veterinária, MSc. Curso de Pós-Graduação em Ciências Veterinárias, Instituto de Veterinária, Universidade Federal Rural do Rio de Janeiro (UFRRJ), *Campus Seropédica*, BR 465 Km 7, Seropédica, RJ 23890-000, Brasil/Faculdade de Medicina Veterinária, Fundação Educacional Dom Arcoverde, Rua Sargento Victor Hugo, 161, Bairro de Fátima, Valença, RJ 27600-000, Brasil. *Author for correspondence, E-mail: liliancsobatista@hotmail.com - bolsista CAPES.

² Curso de Medicina Veterinária, Faculdade de Medicina Veterinária, Fundação Educacional Dom Arcoverde, Rua Sargento Victor Hugo, 161, Bairro de Fátima, Valença, RJ 27600-000.

³ Biólogo, Programa de Pós-Graduação em Ciência, Tecnologia e Inovação, UFRRJ, *Campus Seropédica*, BR 465 Km 7, Seropédica, RJ 23890-000. E-mail: biolopesbb@hotmail.com - bolsista CAPES.

⁴ Biólogo, DSc. Departamento de Biologia Animal, Instituto de Biologia, UFRRJ, *Campus Seropédica*, BR 465 Km 7, Seropédica, RJ 23890-000. E-mail: bertobp@ufrj.br

kept in captivity, coccidiosis is considered a major cause of enteritis and death. This disease is caused by protozoa coccidia mainly of Eimeriidae family which is transmitted by ingestion of oocysts shed in feces (Freitas et al. 2003, Saks et al. 2006).

The coccidia of the genera *Eimeria* Schneider, 1875 and *Isospora* Schneider, 1881 are the most important parasites of the order Passeriformes, being the genus *Isospora* the most common (Page & Haddad 1995, Dolnik et al. 2010, Berto et al. 2011). Species of these genera infect the epithelial cells of the intestinal mucosa, causing disorders in the mucosa and hence diarrhea, sometimes hemorrhagic, and interference in the absorption of nutrients (Freitas et al. 2003). The most common clinical signs are characterized by ruffled feathers, apathy, loss of appetite or exacerbated appetite, diarrhea, weakness, weight loss, cachexy "breast dry" and prostration. Also can be observed reproductive problems, skin disturbs and moulting late (Dolnik et al. 2010, Carneiro et al. 2011).

The adult passerines are usually asymptomatic, being only a source of infection to other birds, which being very young or immunocompromised may suffer profound effects on physical health and come to death (Page & Haddad 1995, Dolnik 2003). Anything that compromises the immunity of a passerine with asymptomatic coccidiosis can take to a manifestation of an acute condition of coccidiosis (Soulsby 1986).

In *S. angolensis* are reported outbreak and mortality of specimens between two and three months old (Guimarães 2006), being related to three *Isospora* spp. from this host species in Brazil: *Isospora curio* Trachta & Silva et al. 2006, *Isospora braziliensis* Trachta & Silva et al. 2006 and *Isospora paranaensis* Trachta & Silva et al. 2006 (Trachta & Silva et al. 2006).

The non-invasive method for determining the presence and quantity of these parasites is the detection and counting of oocysts from droplets of feces (López et al. 2007). These fecal samples should be collected preferably in the late afternoon, because all life stages of *Isospora*, including the oocysts shedding, are associated with circadian rhythm in several families of Passeriformes, occurring a peak of oocysts shedding between 3:00 PM to 8:00 PM (Dolnik 2006).

Infection prevention measures for coccidia in passerines are related to the general care of hygiene in the breeding facility, balanced nutrition, good water, rules appropriate for the type of breeding and training of handlers in the care of the handling

of symptomatic passerines (Carneiro 2011). In a commercial breeding facility, control is done with periodic exams of feces and strategic medications during the year. The adult passerines which are submitted to this control have chicks more resistant and less susceptible to symptomatic coccidiosis (Benez 2001).

This study aims to notify the coccidiosis due to *I. curio* in lesser seed-finches kept in a commercial breeding facility in the municipality of Valença, state of Rio de Janeiro, Brazil.

HISTORICAL FINDINGS

Selection of the location and species studied

Forty-eight fecal samples of lesser seed-finches *S. angolensis* were collected in a commercial breeding facility located at the Municipality of Valença in the State of Rio de Janeiro, Brazil. These lesser seed-finches were aged between one month and six years, being 23 with less than one year old.

Sample collection

The collecting of samples was according to the method described by Dolnik (2006) and Dolnik et al. (2009), where the samples of droplets of feces were collected individually from a paper towel placed on the bottom of the cages. These samples were collected at late afternoon respecting the circadian rhythm of elimination of oocysts (Lopez et al. 2007, Coelho et al. 2013), in the period from May to June 2014.

The samples were identified, placed in plastic vials containing potassium dichromate 2.5% ($K_2Cr_2O_7$) solution at 1:6 (v/v) and transported to the Laboratório de Coccídios e Coccidioses (LCC) located at Universidade Federal Rural do Rio de Janeiro (UFRRJ), Campus Seropédica, RJ.

Sample processing

In LCC, the samples were incubated at room temperature for three days, when c.70% of the oocysts were sporulated. Oocysts were recovered by flotation in Sheather's sugar solution (Specific gravity: 1.20) and examined microscopically using the technique described by Duszyński & Wilber (1997) and Berto et al. (2014). Morphological observations, line drawings, photomicrographs and measurements were made using a Zeiss microscope equipped with a digital camera. Line drawings were edited using two software applications from CorelDRAW® (Corel Draw Graphics Suite, Version 11.0, Corel Corporation, Canada), specifically Corel DRAW and Corel PHOTO-PAINT. All

measurements are in micrometers and are given as the range followed by the mean in parentheses.

Evaluation of the passerines

In total fecal samples from 48 lesser seed-finches were examined and 4 (8.33%) were positive for coccidia. Positive animals have not characteristic clinical signs of coccidiosis; however they died about 20 days after collection of samples. These deaths may have occurred because of age or high intensity of infection that led them to an acute condition of coccidiosis (Figure 1). In the fecal samples of one of these dead passerines, which had three months old, was observed the presence of intestinal mucosa fragments containing many unsporulated oocysts (Figure 2).

The oocysts observed from the fecal samples are subspherical, measuring 22–24 x 21–23 μm (23.1x 22.4), with smooth, bilayered wall c.1.1 thick. Micropyle, oocyst residuum and polar granule are

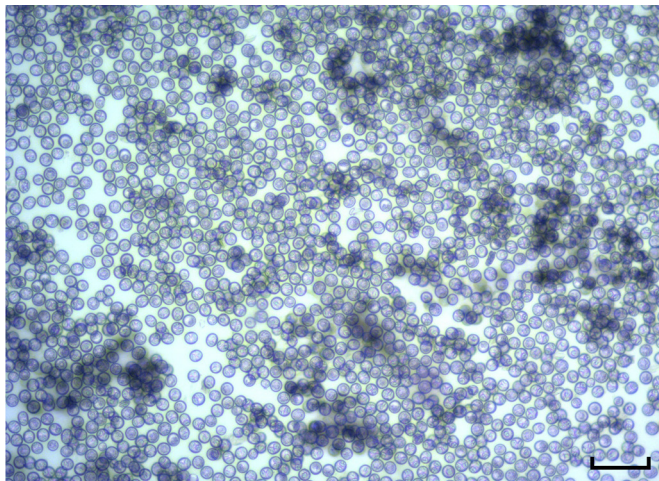


Figure 1. Photomicrograph of sporulated oocysts of *Isoospora curio* observed in fecal samples of lesser seed-finches *Sporophila angolensis* indicating the high intensity of infection. Sheather's sugar solution. Scale-bar: 100 μm .

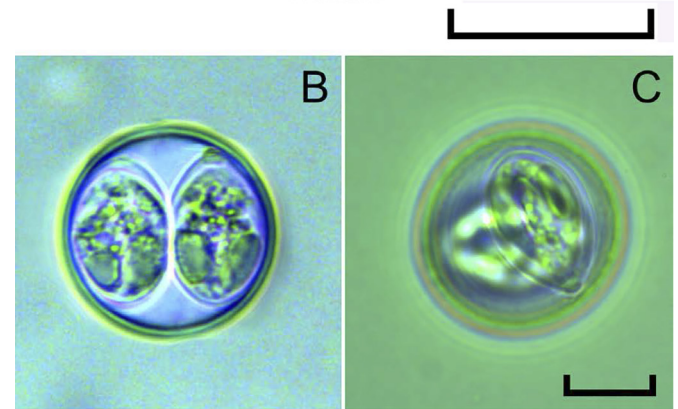
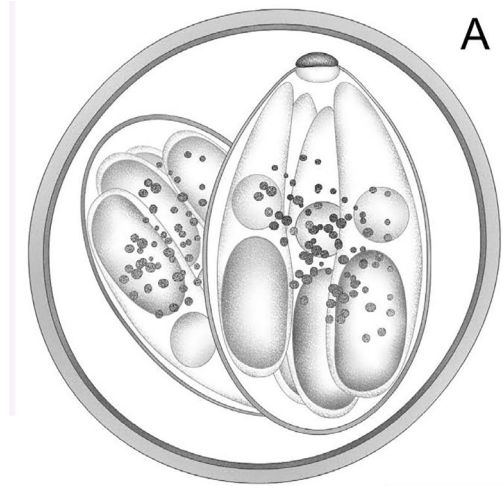


Figure 3. Oocysts of *Isoospora curio* observed in fecal samples of lesser seed-finches *Sporophila angolensis*. A - Composite line drawing and, B and C - photomicrographs. Scale-bar: 10 μm .

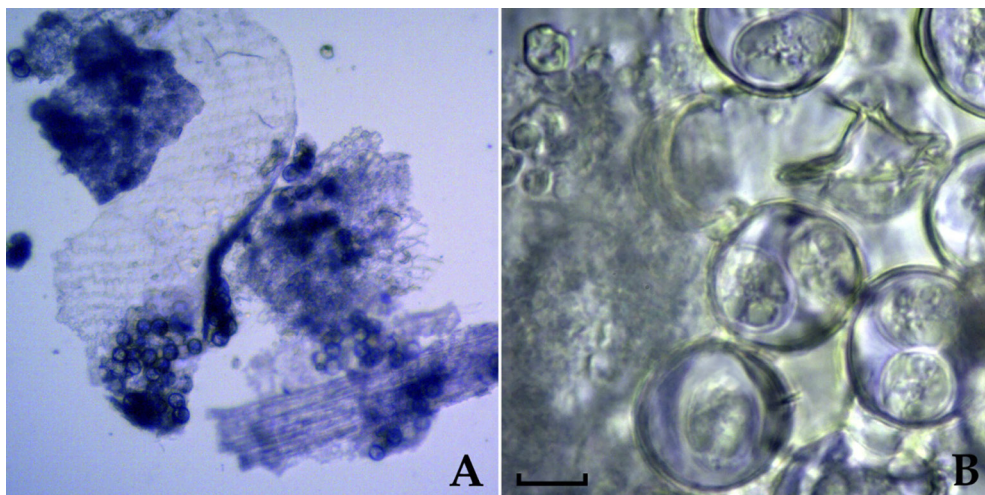


Figure 2. Photomicrograph of sporulated oocysts of *Isoospora curio* observed in an intestinal mucosa fragment in the fecal samples of lesser seed-finches *Sporophila angolensis* indicating the severity of infection. Sheather's sugar solution. Scale-bar: A = 100 μm and, B = 10 μm .

absent. Sporocysts are ovoidal, measuring 16–17x 10–11 µm (16.4 x 10.4). Stieda body is knob-like and sub-Stieda body is small, rounded and barely discernible. Sporocyst residuum is composed of scattered spherules. Sporozoites are vermiform, with one elongate refractile body and a nucleus (Figure 3). These oocysts had the same characteristic features of the oocysts of *I. curio* originally described by Trachta e Silva et al. (2006) from *S. angolensis* in the State of Mato Grosso do Sul, Brazil.

DISCUSSION

In the current work, the definition of the period for the sample collection was based on previous studies, being held at late afternoon (precisely at 5:00 PM), which favored a larger quantity of oocysts in the fecal samples of the passerines. This activity, respect the circadian rhythm of oocysts shedding. Similar procedures were previously observed by Lopez et al. (2007) in European serins *Serinus serinus* (Linnaeus, 1766) and garden warblers *Sylvia borin* (Boddaert, 1783) and Coelho et al. (2013) in green winged saltators *Saltator similis* d'Orbigny & Lafresnaye, 1837. This observation had been already reported by Boughton (1933) when first observed that oocysts shedding in domestic sparrows *Passer domesticus* Linnaeus, 1758 is not constant throughout the day, occurring mainly in the late afternoon.

In one of the dead passerines, which had three months old, was observed fragments of intestinal mucosa in its fecal sample. This observation indicates the high severity of the infection, because the *Isospora* spp. are recognized to infecting the cells of the intestinal epithelium causing lesions (Godoy & Matushima 2010). Coccidiosis can induce different degrees of inflammatory processes in hosts, where can be observed meronts in intestinal mucosa (de Vasconcelos et al. 2012). These conditions can be observed in passerines that had not previous exposure to the parasite or when the parasitic load is sufficiently high, which may explain the case reported in the current work.

In Brazil, Guimarães (2006) reported outbreaks and mortality in young lesser seed-finches between two and three months old. Petrucci et al. (2009) reported mortality due to *Isospora* sp. in young lesser seed-finches with ten days old in a breeding facility at the Municipality of Campo dos Goytacazes in the State of the Rio de Janeiro. These reports are similar to observed data in the current work. Additionally, it should be emphasized that, in the current work, the passerines highly parasitized had

no clinical signs of disease and both died. Dolnik (2003), in previous work, affirms that young passerines with high intensity of infection, reinfection or confined in environments containing parasites, can have effects on physical health and survival, which was observed in the current work.

Regardless of the number of infected passerines, it can be observed that coccidiosis always causes disturb to the passerines in captivity. In the State of Mato Grosso do Sul, was reported a prevalence of 26.4% for *Isospora* spp. in 675 fecal samples from lesser seed-finches. This parasitism was associated to problems in the breeding, such as reproductive disturbs, weight loss and death (Trachta & Silva et al. 2006). Likewise, Vasconcellos et al. (2013) reported prevalence of 90% for *Isospora* spp. in 40 fecal samples from green winged saltators, reared near to the breeding facility of the current work. This last result (Vasconcellos et al. 2013) is quite different of the current work, possibly due to two conditions/characteristics: (1) The green winged saltators have a different behavior and feeding habits of the lesser seed-finches, such as they accumulate large amounts of feces in the cage, food and water and therefore they are more susceptible to be infected with oocysts. In this sense, Dolnik et al. (2010) reported that, there are differences in the intensity of infection due to *Isospora* spp. in different species of passerines, as arising from different behavior and feeding habits; (2) the selected fecal samples were all diarrheal, while in the current work the samples were collected regardless of the aspect.

The breeding facility of lesser seed-finches of the current work had satisfactory hygienic conditions, with clean cages, suspended floor and waterbeds and feeders clean and distant from the perches, which justifies the low prevalence of *Isospora* spp. in the passerines. Despite the high intensity of infection in the positive passerines, hygiene was an important factor in limiting the transmission of sporulated oocysts to other passerines; since that, the oocyst becomes infective only after the sporulation process, which should occur one to three days after shedding. In this sense, Krautwald-Junghanns et al. (2009) affirm that daily removal of feces and the cleaning of waterbeds and feeders reduces significantly the amount of infective oocysts.

The morphological and morphometric studies developed for the sporulated oocysts observed in the fecal samples of the current work, suggest the specific identification of *I. curio*. All morphological and morphometric characteristic features are quite similar, except the substieda body. In the original

description of Trachta & Silva et al. (2006), *I. curio* is described with substieda body absent; however, as the substieda body was observed as small and sometimes barely discernible in the current work, it is possible that the authors of the original description have not perceived its presence. Therefore, further morphological and morphometric studies on *Isoospora* spp. from *S. angolensis* are required to confirm that *I. curio* has substieda body, or that the oocysts observed in this study are a new species.

REFERENCES

- Benez S.M. *Aves - Criação - Clínica - Teoria - Prática - Silvestres - Ornamentais - Avinhados*. 3ª ed., Robe Editorial, São Paulo, 2001. 522p.
- Berto B.P., Flausino W., McIntosh D., Teixeira-Filho W.L., Lopes C.W.G. Coccidia of New World passerine birds (Aves: Passeriformes): a review of *Eimeria* and *Isoospora* (Apicomplexa: Eimeriidae). *Systematic Parasitology*, 80:159-204, 2011.
- Berto B.P., McIntosh D., Lopes C.W.G. Studies on coccidian oocysts (Apicomplexa: Eucoccidiorida). *Rev. Bras. Parasitol. Vet.*, 23:1-15, 2014.
- Boughton D.C. Diurnal gametic periodicity in avian *Isoospora*. *Am. J. Epidemiol.*, 18:161-184, 1933.
- Carneiro M.B., Calais Junior A. & Martins I.V.F. Avaliação coproparasitológica e clínica de aves silvestres e exóticas mantidas em criatórios particulares no município de Alegre-ES. *Ciênc. Anim. Bras.*, 12:525-529, 2011.
- Coelho C.D., Berto B.P., Neves D.M., Oliveira V.M., Flausino W. & Lopes C.W.G. Oocyst shedding by green-winged-saltator (*Saltator similis*) in the diagnosis of coccidiosis and *Isoospora similis* n. sp. (Apicomplexa: Eimeriidae). *Rev. Bras. Parasitol. Vet.*, 22:64-70, 2013.
- Coutteel P. Veterinary aspects of breeding management in captive passerines. *Seminars in Avian and Exotic Pet Medicine*, 12:3-10, 2003.
- de Vasconcelos T.C.B., Longa C. da S., Campos S.D.E., Costa C.H.C. & Bruno S.F. Coccidiose em *Sporophila maximiliani* (Passeriformes: Emberizidae): relato de dois casos. *Rev. Bras. Med. Vet.*, 34:261-264, 2012.
- Dolnik O. Same aspects of the biology and host-parasite interactions of *Isoospora* spp. (Protozoa: Coccidiida) of passerine birds. *J. Ornithol.*, 144:379-380, 2003.
- Dolnik O. The relative stability of chronic *Isoospora sylvianthina* (Protozoa: Apicomplexa) infection in blackcaps (*Sylvia atricapilla*): evaluation of a simplified method of estimating isosporan infection intensity in passerine birds. *Parasitol. Res.*, 100:155-160, 2006.
- Dolnik O.V., Palinauskas V. & Bensch S. Individual oocysts of *Isoospora* (Apicomplexa: Coccidia) parasites from avian feces: from photo to sequence. *J. Parasitol.*, 95:169-174, 2009.
- Dolnik O.V., Dolnik V.R., Bairlen F. The effect of host foraging ecology on the prevalence and intensity of coccidian infection in wild passerine birds. *Ardea*, 98:97-103, 2010.
- Duszynski D.W., Wilber P.G. A guideline for the preparation of species descriptions in the Eimeridae. *J. Parasitol.*, 83:333-336, 1997.
- Freitas M.F.L., Oliveira J.B., Cavalcanti M.B. & Freitas D.A. Occurrence of coccidiosis in canaries (*Serinus canarius*) being kept in private captivity in the state of Pernambuco, Brazil. *Parasitol. Latinoam.*, 58:86-88, 2003.
- Godoy S.N. & Matushima E.R. A survey of diseases in Passeriform birds obtained from illegal wildlife trade in São Paulo city, Brasil. *J. Avian Med. Surg.*, 24:199-209, 2010.
- Guimarães M.B. Passeriformes (pássaro, canário, saíra, gralha), p.324-337. In: Cubas Z.S., Silva J.C.R. & Catão-Dias J.L. (Eds), *Tratado de animais selvagens*. Roca, São Paulo, 2006.
- Krautwald-Junghanns M.E., Zebisch R. & Schmidt V. Relevance and treatment of coccidiosis in domestic pigeons (*Columbia livia* forma domestica) with particular emphasis on Toltrazuril. *J. Avian Med. Surg.*, 23:1-5, 2009.
- López G., Figuerola J. & Soriguer R. Time of day, age and feeding habits influence coccidian oocyst shedding in wild passerines. *Intern. J. Parasitol.*, 37:559-564, 2007.
- Page C.D. & Haddad K. Coccidial infections in birds. *Seminars in Avian and Exotic Pet Medicine*, 4:138-144, 1995.
- Petrucci M.P., Pontes L.A.C. & Batista A.M. Terapêutica da coccidiose em criatório comercial de curió (*Oryzoborus angolensis*) no município de Campos de Goytacazes, Rio de Janeiro. *J. Bras. Ciênc. Anim.*, 2:1-2, 2009.
- Saks I., Karu U., Ots I. & Hõrak P. Do standart measures of immunocompetence reflect parasite resistance? The case of Greenfinch coccidiosis. *Funct. Ecol.*, 20:75-82, 2006.
- Sigrist T. *Guia de Campo Avis Brasilis - Avifauna Brasileira*. Avis Brasilis, São Paulo, 2013, p.488.
- Soulsby E.J.L. *Helminths, Arthropods and Protozoa of Domesticated Animals*, 7th ed. London, Bailliere Tindall, 1986. 868p.
- Trachta & Silva E.A., Literák I. & Koudela B. Three new species of *Isoospora* Schneider, 1881 (Apicomplexa: Eimeriidae) from the lesser seed-finch, *Oryzoborus angolensis* (Passeriformes: Emberizidae) from Brazil. *Mem. Inst. Oswaldo Cruz*, 101:573-576, 2006.
- Vasconcellos M.S.D., Batista L.C.S.O., Vidal L.G.P. & Passos M.M. Intensidade de infecção por *Isoospora* spp. (Apicomplexa: Eimeriidae) em trinca-ferros-verdadeiros *Saltator similis* d'Orbigny, Lafresnaye (Passeriformes: Cardinalidae) mantidos em cativeiro no Município de Valença, Estado do Rio de Janeiro, Brasil. *Coccidia*, 1:39-43, 2013.
- Wikiaves. Curio. Disponível at: <<http://www.wikiaves.com.br/curio>>. Acess on: Apr 25, 2015.