

COCCIDIOSIS IN A BLUE-FRONTED AMAZON PARROT (*Amazona aestiva*) UNDER QUARANTINE - CASE REPORT*

Lianna Maria de Carvalho Balthazar¹⁺, Bruno do Bomfim Lopes², Bruno Pereira Berto³, Caroline Spitz dos Santos¹, Walter Leira Teixeira Filho⁴, Daniel Medeiros Neves⁵ e Carlos Wilson GomesLopes⁶

ABSTRACT. Balthazar L.M. de C., Lopes B. do B., Berto B.P., dos Santos C.S., Teixeira Filho W.L. Neves D.M. & Lopes C.W.G. **Coccidiosis in a Blue-fronted Amazon parrot (*Amazona aestiva*) under quarantine - Case report.** [Coccidiose em um papagaio verdadeiro (*Amazona aestiva*) mantido em confinamento - Relato de caso]. *Revista Brasileira de Medicina Veterinária*, 35(4):392-396, 2013. Programa de Pós-Graduação em Ciências Veterinárias, Instituto de Veterinária, Universidade Federal Rural do Rio de Janeiro, Campus Seropédica, BR 465 Km7, Seropédica, RJ 23897-970, Brasil. E-mail: liannavet@yahoo.com.br

An adult male blue-fronted Amazon parrot (*Amazona aestiva*), was kept under quarantine in CETAS/IBAMA Seropédica, RJ, Brazil. Clinical signs consisted of apathy, anorexia, weight loss, ruffled and dull feathers and greenish mucoid diarrhea. Feces were observed stuck to the feathers around the cloacae. Oocysts of the both sample were placed in a 2.5% solution of $K_2Cr_2O_7$ to allow them to sporulate. Upon microscopic examination, unsporulated oocysts were observed in the feces of the first sample. However, oocysts of the second sample, collected three days after the first sample, sporulated and they were recovered for determining the species. The oocysts varied from ovoidal to ellipsoidal with $27.9 \times 26.9\mu m$ in diameters, with a smooth wall consisting of two layers of $1.4\mu m$ thickness. Micropyle and oocyst residuum were absent, but polar granules were present. Sporocysts were elongated and ellipsoidal measuring $19.6 \times 11.1\mu m$. The Stieda body presented a knob-like appearance and was slightly pointed in the external surface. The substieda body was undefined. The sporocyst residuum was composed of scattered granules and the sporozoites were vermiform with a refractile body and a nucleus. The characteristics of the oocysts were similar to those described previously as *Eimeria amazonae*. In addition to the case report of a clinical coccidiosis, comments on geographic distribution and interspecific infections are presented herein.

KEY WORDS. *Amazona aestiva*, coccidiosis, CETAS, quarantine.

RESUMO. Um papagaio verdadeiro (*Amazona aestiva*), adulto, macho, estava mantido em regime de quarentena no CETAS/IBAMA em Seropédica,

RJ. Como sinais clínicos foram observados apatia, anorexia, perda de peso, penas, eriçadas e sem brilho, com diarréia mucoide de coloração esverdeada,

* Received on August 5, 2012.

Accepted for publication on September 18, 2013.

¹ Médica-veterinária, MSc. Programa de Pós-Graduação em Ciências Veterinárias, Instituto de Veterinária (IV), Universidade Federal Rural do Rio de Janeiro (UFRRJ), BR 465 Km 7, Seropédica, RJ 23897-970, Brasil. *Author for correspondence. E-mail:liannavet@yahoo.com.br carolinespitz@yahoo.com.br

² Biólogo Autônomo. Laboratório de Coccídios e Coccidioses, Departamento de Parasitologia Animal (DPA), IV, UFRRJ. BR 465 Km 7, Seropédica, RJ 23897-970. E-mail:biolopesbb@hotmail.com

³ Biólogo, DSc. Departamento de Biologia Animal, Instituto de Biologia, UFRRJ, BR 465 Km 7, Seropédica, RJ 23897-970. E-mail:bertobp@ufrj.br

⁴ Biólogo, PhD. Departamento de Parasitologia Animal (DPA), IV, UFRRJ, BR 465 Km 7, Seropédica, RJ 23897-970. E-mails: leira@ufrj.br

⁵ Médico-veterinário, MSc. Centro de Triagem de Animais Silvestres, Instituto Brasileiro do Meio-Ambiente e dos Recursos Naturais Renováveis (IBAMA), Ministério do Meio Ambiente e Recursos Renováveis, Seropédica, RJ 23835-400. E-mails: danielmn35@hotmail.com

⁶ Médico-veterinário, PhD, LD. DPA, IV, UFRRJ, BR 465 Km 7, Seropédica, RJ 23897-970. E-mail:lopesewg@ufrj.br - CNPq fellowship.

parte residual aderida as penas ao redor da cloaca. Os oocistos de ambas amostras foram colocadas numa solução a 2,5% de $K_2Cr_2O_7$, para lhes permitir esporular. Após exame microscópico, os oocistos da primeira amostra não esporularam. No entanto, os oocistos da segunda amostra, recolhidas três dias após a primeira amostra esporuladas e foram recuperados para determinar as espécies. Os oocistos esporulados variaram de ovoide a elipsoide medindo $27,9 \times 26,9 \mu m$, com uma parede lisa constituída de duas camadas com $1,4 \mu m$ de espessura. Micrópila e resíduo dos oocistos foram ausentes, mas grânulos polares foram presentes. Esporocistos foram alongados e elipsoidais com $19,6 \times 11,1 \mu m$. Corpo de Stieda em forma de botão levemente pontudo em sua porção exterior. Corpo de substieda indefinido. O resíduo do esporocisto foi constituído por grânulos dispersos e os esporozoítos foram lanceolados com um corpo refrátil e um núcleo. As características dos oocistos esporulados foram semelhantes à descrita para *Eimeria amazonae*. Ao lado da descrição da coccidiose clínica foi feitas observações sobre a distribuição geográfica e as infecções intestinais.

PALAVRAS-CHAVE. *Amazona aestiva*, coccidiose, CETAS, quarentena.

INTRODUCTION

In Brazil, nearly 12 million animals are illegally traded every year, with specimens of the orders Passeriformes and Psittaciformes often being seized by the environmental authorities from pet owners who keep such animals without legal permission (Ferreira & Glock, 2004, Araújo et al. 2010, IBAMA 2012). In this context, the Centers for Wildlife Screening (CETAS) has the purpose of receiving, cataloguing and treating wild animals rescued or seized by their inspectors, including wild animals maintained illegally as pets (IBAMA 2012).

Coccidiosis in parrots is relatively infrequent, and most often demonstrates a subclinical evolution, but in immunosuppressed, young or stressed animals clinical disease characterized by inactivity, weight loss, retarded growth and greenish or hemorrhagic watery diarrhea, can be observed. Importantly, intestinal lesions caused by coccidia can serve as a gateway for other infections (Godoy 2007). The current manuscript aims to relate a case of coccidiosis in a blue-fronted Amazon parrot kept in quarantine.

CLINICAL FINDINGS

A blue-fronted Amazon parrot (*Amazona aestiva* Linnaeus, 1758) was maintained in an individual cage under quarantine at a Screening Center (CETAS)/IBAMA in the Municipality of Seropédica in the State of Rio de Janeiro, Brazil. Clinical signs were recorded as consisting of apathy, anorexia, weight loss and, ruffled and dull feathers, and notably the production of greenish mucoid diarrhea. Feces were also observed adhered to feathers around the cloacae (Figure 1a,b). Two fresh fecal samples were collected from the bottom of the cage after defecation on two occasions, with a three day interval between collection point. On both occasions samples were immediately placed into plastic vials and transported to the Laboratório de Coccídios e Coccidioses at the Departamento de Parasitologia Animal, Instituto de Veterinária in the Universidade Federal Rural do Rio de Janeiro, *Campus* Seropédica, RJ. A large number of unsporulated oocysts were observed in both samples following the use of a flotation technique in Sheather's sugar solution (sp.g. 1.20). Thereafter, portions of both samples were placed in a thin layer (c.5 mm) of $K_2Cr_2O_7$ 2.5% (w/v) solution in Petri plates with incubation at 23–28°C for up to 10 days, or until 70% of the oocysts were sporulated. However, only the oocysts present in the second sample sporulated. Subsequent identification of sporulated oocysts was used based upon phenotypic characteristics reported by Tenter et al. (2002) and microscopic examination of the morphological characteristics indicated by Duszynki & Wilber (1997). Morphological observations and measurements, in μm , were made using a Zeiss binocular microscope with an apochromatic oil immersion objective lens and a PZO K-15X ocular micrometer. Photomicrographs were taken using an electronic digital camera. Size ranges are provided in parenthesis followed by the mean, and shape index (length/width).

Initially, the oocysts were not sporulated (Figure 2a), but 70% sporulation was observed over a period of seven days. Oocysts (N=10) were ellipsoidal, $41.4 (36-47) \times 26.3 (24-30)$, with shape-index of 1.58. Oocyst walls were bi-layered, smooth and showed a thickness of $1,4 \mu m$. Micropyle and oocyst residuum were absent, but polar granules were present. Sporocysts (N=10) were ellipsoidal, $19.6 \times 11.1 \mu m (18.4-21.6 \times 8.6-10.6)$. The Stieda body was lightly pointed while the SSB was undefined. The sporocyst residuum was comprised by scattered granules; the



Figure 1. Blue-fronted Amazon parrot. Clinical Coccidiosis (A); greenish watery diarrhea with fecal debris adhered on the cloacae surrounding feathers (B).

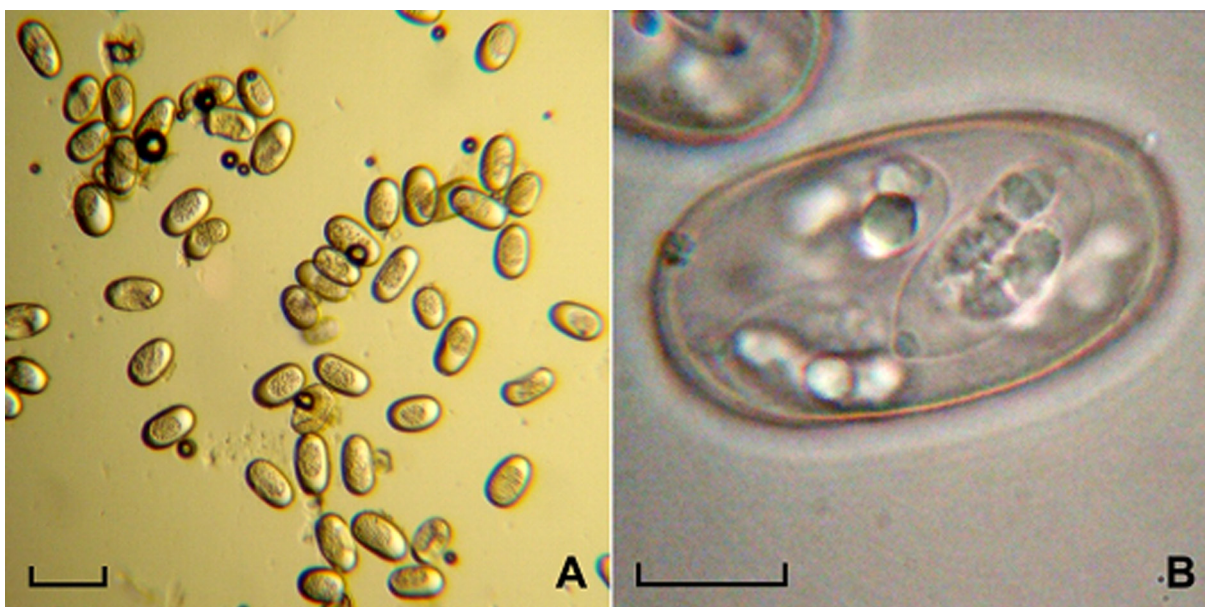


Figure 2. Blue-fronted Amazon parrot. Photographs of *Eimeria amazonae*: unsporulated oocysts. Scale-bar: 50µm (A); sporulated oocyst. Scale-bar: 10 µm (B).

sporozoites were vermiform and possessed a refractile body and a nucleus (Figure 2b).

DISCUSSION

The majorities of the case reports of disease outbreaks, particularly coccidiosis, among animals held under quarantine has associated disease with overcrowding, confinement and stress, and have sometimes reported transmission among the same species or among species of the same family, kept at over-capacity. Such conditions do not represent adequate quarantine; thereby facilitating the spread of patho-

gens. Preventive procedures, implemented upon the arrival of the animal at a screening enter until their subsequent allocation or re-introduction, are fundamental for each animal and are a pre requisite to avoid the dispersion of pathogens, both to their natural environments if they are returned there to, or to other environments to which they may be sent e.g. zoological parks (Godoy 2007, Fritzen 2008).

The clinical signs observed in the animals in this study were considered representative of coccidiosis, and were in part, similar to those described by Godoy (2007), characterized by apathy, ruffled fe-

Table 1. Comparative analysis of sporulated oocysts observed in Psittacid Parrots in Brazil.

Coccidia species	Hosts	Forms	Oocysts		Shaped Index	Wall	References
			Diameters (μm)				
			Length	Width			
<i>Eimeria aestiva</i> (N= 60)	<i>Amazona aestiva</i>	Ovoidal	36,8 (33,2-41,5)	23,7 (21,7-25,7)	1,55	bi-layered	Hofstatter & Guaraldo, 2011
<i>Eimeria amazonae</i> (N= 60)	<i>Amazona ochrocephala</i>	Ellipsoidal	48,9 (44,4-53,8)	36,2 (32,2-39,5)	1,35	bi-layered	Hofstatter & Kawazoe, 2011
<i>Eimeria ochrocephala</i> (N= 60)	<i>Amazona ochrocephala</i>	Ellipsoidal	43,8 (37,9-49,3)	27,7 (24,1-32,0)	1,58	bi-layered	Hofstatter & Kawazoe, 2011
<i>Eimeria amazonae</i> (N= 10)	<i>Amazona aestiva</i>	Ovoidal -I Ellipsoidal	41,4 (36,3-46,7)	26,3 (23,6-29,7)	1,58	bi-layered	Present work

athers, greenish watery diarrhea with fecal debris adhered on the cloacae surrounding the feathers, and associated with a large number of oocysts in the fecal samples.

The presence of numerous oocysts was recorded in the freshly collected fecal samples, but they were not sporulated, making it difficult to identify the coccidia species. A comparative analysis of sporulated oocysts observed in Psittacid parrots in Brazil was undertaken (Table 1), as an aid to identification of the oocysts recovered in the current work. It was noted that the morphological descriptions of the sporulated oocysts recovered from the second fecal sample collected in this study were similar to those for *E. aestiva*, as previously described by Hofstatter & Guaraldo (2011) in the feces of a Blue-fronted Amazon parrot (*A. aestiva*), yet at the same they were not morphologically dissimilar from the descriptions of *E. amazonae* and *E. ochrocephalae* reported by Hofstatter & Kawazoe (2011) in the yellow-crowned Amazon parrot (*Amazona ochrocephala* Gmelin, 1788). In light of these difficulties, it is worth considering that the species described by Hofstatter & Kawazoe (2011) and Hofstatter & Guaraldo (2011) may be related as the same species. In fact, this statement was based on an assessment of the geographical distribution of both parrots (Figure 3), which were characterized as sympatric species (IUCN 2013). In addition, they can be captured and maintained in the same quarantine conditions which could favor infection of both species of parrot, with the same infectious agent. As final comments, and in accordance with the recommendations of Duszyński & Wilber (1997), oocysts recovered from a host species should be compared in detail with the sporulated oocyst described previously in the same host family in which the oocysts were found.

Acknowledgements. We are thankful to the CETAS/IBAMA located at Municipality of Seropédica

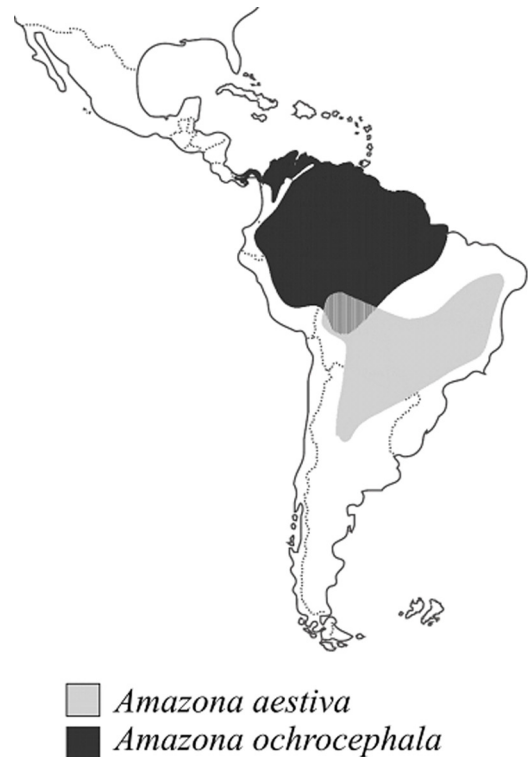

Figure 3. Geographic range of both parrots in Brazilian territory, according to (IUCN, 2013).

in the State of Rio de Janeiro, Brazil, in particular for staff, that allowed us to take care of this animal, and FAPERJ for supporting this research.

REFERENCES

- Araújo A.C.B., Behr E.R., Longhi S.J., Menezes P.T.S. & Kaniéski M.R. Diagnóstico sobre a avifauna apreendida e entregue espontaneamente na região central do Rio Grande do Sul, Brasil. *Biociências*, 8:279-284, 2010.
- Duszyński D.W. & Wilber P.G. A guideline for the preparation of species descriptions in the Eimeriidae. *J. Parasitol.*, 83:333-336, 1997.
- Ferreira C.M. & Glock L. Diagnóstico preliminar sobre a avifauna traficada no Rio Grande do Sul, Brasil. *Biociências*, 12:21-30, 2004.
- Fritzen C. *Análise das ações de medicina veterinária no Centro de Reabilitação de Animais Silvestres (Cereias), Araucruz - ES*. 2008. 64p. Especialização (Medicina de Animais Selvagens e Exóticos), Universidade Castelo Branco,

- Rio de Janeiro, 2008. (Disponível at: <[http://www.qualittas.com.br/uploads/documentos/Analise %20das%20Acoes%20de%20Medicina%20Veterinaria%20%20Carolina%20Fritzen.PDF](http://www.qualittas.com.br/uploads/documentos/Analise%20das%20Acoes%20de%20Medicina%20Veterinaria%20%20Carolina%20Fritzen.PDF)>.)
- Godoy S.N. Psittaciformes (Arara, Papagaio, Periquito), p.222-251. In: Cubas Z.S., Silva J.C.R. & Catão-Dias J.L. (Eds), *Tratado de animais selvagens - Medicina Veterinária*. Manole, São Paulo, 2007.
- Hofstatter P.G. & Guaraldo A.M. A new eimerian species (Apicomplexa: Eimeriidae) from the blue-fronted Amazon parrot *Amazona aestiva* L. (Aves: Psittacidae) in Brazil. *J. Parasitol.*, 97:1140-1141, 2011.
- Hofstatter P.G. & Kawazoe U. Two new *Eimeria* species (Apicomplexa: Eimeriidae) from the yellow-crowned Amazon *Amazona ochrocephala* (Aves: Psittacidae) in Brazil. *J. Parasitol.*, 97:503-505, 2011.
- IBAMA. Projeto CETAS - Educação Ambiental. Uma ferramenta contra os maus-tratos e o tráfico de animais silvestres. Instituto Brasileiro do Meio Ambiente e dos Recursos Naturais e Renováveis Disponível em: <<http://www.ibama.gov.br/faunasilvestre/wp-content/files/projeto-educacao.pdf>>. Acesso em: 6 jul 2012.
- Tenter A.M., Barta J.R., Beveridge I., Duszynski D.W., Mehlhorn H., Morrison D.A., Thompson R.C. & Conrad P.A. The conceptual basis for a new classification of the coccidia. *Int. J. Parasitol.*, 32:595-616, 2002.
- IUCN. *Amazona*. Disponível at: <<http://www.iucnredlist.org>>. Accessed on: 10 jul. 2013.

