

CASE REPORT

Swyer syndrome: A rare case

Hema Kumari Pradhan¹, Ganesh Dangal¹, Manoj Krishna Shrestha²¹Department of Obstetrics and Gynaecology, Kathmandu Model Hospital, Kathmandu, Nepal²Department of Pediatric Surgery, Kathmandu Model Hospital, Kathmandu, Nepal

Correspondence to: Dr. Hema Kumari Pradhan, Email: drhemapradhan@hotmail.com

INTRODUCTION

Swyer syndrome is a disorder of sex development (DSD) first described by Dr Swyer in 1955.¹ The incidence is 1:80000.² Mutation in several different genes cause Swyer syndrome or can be inherited as autosomal dominant, autosomal recessive, X-linked or Y-linked manner.³

The patients with Swyer syndrome have pure gonadal dysgenesis with 46 XY karyotypes. They present with female phenotype, delayed puberty, and primary amenorrhoea. They have normal looking external genitalia, vagina, hypoplastic uterus, tubes and streak dysgenetic gonads. The dysgenetic gonads may develop gonadoblastoma in 20-30 % of cases, usually bilateral, sometimes dysgerminoma and even embryonal cancer.⁴ Gonadectomy is advised as soon as the diagnosis is confirmed.⁶ The objective of reporting this case is to share experience with managing this rare disease as

LEARNING POINTS

1. In primary amenorrhoea, investigation should be done if there are no secondary sexual characteristics by the age of 13 years.
2. Secondary sexual characteristics appear after gonadectomy (due to risk of gonadal malignancies) and hormone replacement therapy.

diagnosis and management is important due to chance of gonadal malignancy if not treated.

CASE DESCRIPTION

A 16-year-old reared as girl presented with primary amenorrhoea. On examination, she was female phenotype, having a height of 165 cm, weight of 51 kg, and breasts Tanner stage II. Her vulva appeared normal, with a hymenal opening, sparse axillary and pubic hair (**FIGURE 1**). There was no palpable mass in the abdomen. She was her parent's only daughter, and

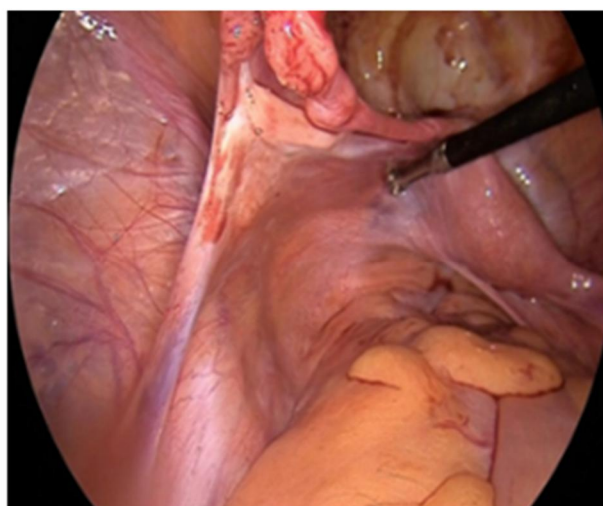
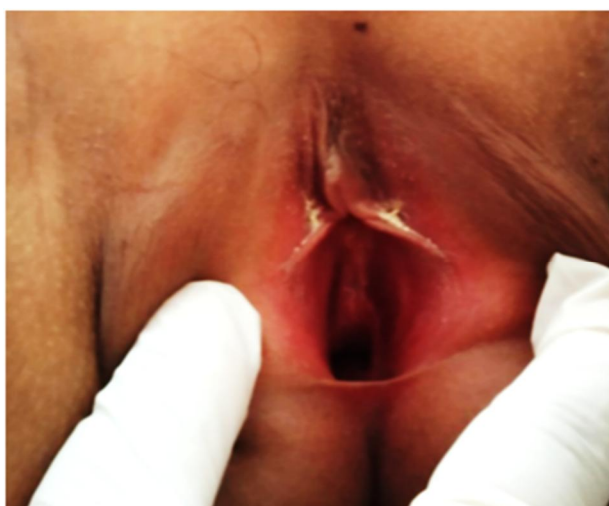

FIGURE 1 Local examination showing hymenal opening (left) and laparoscopic finding showing streak gonad, fallopian tube and small uterus (right)

there was no such history in her family. Ultrasonography reported a small uterus (2.7 cm × 0.5 cm × 0.9 cm) and non-visualization of ovaries. Her hormone test reports were as follows: estradiol 5 pg/ml, leutinizing hormone 5.07mIU/ml, follicle stimulating hormone 17.57 mIU/ml, and testosterone 0.03ng/ml which means she had hypergonadotrophic hypogonadism. Her thyroid function and prolactin were normal. She had 46XY karyotypes (**FIGURE 2**), which were reconfirmed from another laboratory. No other genetic analysis could be done. Her radiological age, as determined from X-Rays of both wrists, was 14-16 years. Finally, she was diagnosed to have Swyer syndrome.

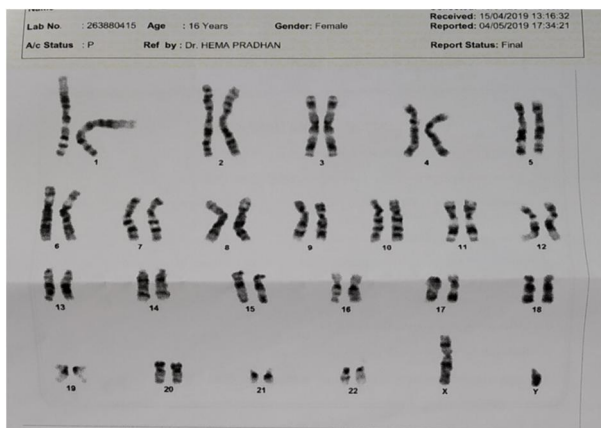

FIGURE 2 Karyotyping 46XY

CASE MANAGEMENT

The parents were counseled about the diagnosis being gonadal dysgenesis and there is chance of gonadoblastoma. For this she needs gonadectomy followed by hormone replacement therapy (HRT) which will be started after the operation. She can marry and have normal sexual life. For pregnancy donor egg will be required. The parents and the girl consented for operation. Laparoscopy done under general anesthesia which showed hypoplastic uterus, streak gonads and fallopian tubes on both side as shown in **FIGURE 1**. Bilateral gonadectomy along with removal of tubes was done. Histopathology revealed stroma in both gonads with no primordial follicles. After the operation, HRT was started. Initially 2 mg of estradiol was given daily for 3 month and medroxyprogesterone 10 mg daily for 10 days. She had withdrawal bleeding and HRT was

continued. On regular follow up, she was satisfied with withdrawal bleeding after medroxyprogesterone. After one year of treatment, her breast size increased to Tanner III. During the COVID-19 pandemic, she did not come for follow up. She informed over telephone that she stopped HRT and menstruation stopped too. After repeated counseling, she started her HRT and now is having withdrawal bleeding regularly.

DISCUSSION

Primary amenorrhoea is defined as the absence of menses by 13 years of age in the absence of secondary sexual characteristics or by the age of 15 years in the presence of normal secondary sexual characteristics.⁷ Swyer syndrome, a pure gonadal dysgenesis is a rare cause of primary amenorrhoea. Swyer syndrome results due to mutations in genes such as ARX, ATRX, CBX2, DHH, DMRT1, GATA4, MAMLD1, MAP3K1, NR0B1, NR5A1, SOX9, WNT4, WT1, WWOX, SRY, and WNT4 which affects testicular differentiation and inhibit anti-Mullerian hormone (AMH). The SRY gene is deleted in approximately 10–15%, and mutated in an additional 10–15%, of patients.⁸ Patients with Swyer syndrome are of female phenotype, tall or normal height, with insufficient pubertal development and having primary amenorrhoea. Due to absence of AMH the Mullerian duct develops into uterus and tubes. As the XY gonads fail to develop into testes, there is no production of testosterone. As a result, they have female external genitalia with hymenal opening. Hormonal test will show raised gonadotropins, decreased estrogen and normal female level androgens. Our patient also had hypergonadotrophic hypogonadism. The differential diagnosis are androgen insensitivity syndrome with 46XY karyotyping and true hermaphroditism. In androgen insensitivity syndrome, the breasts are well developed, have blind vagina, due to AMH the internal female organs are not formed, and testosterone is in normal male level. In true hermaphroditism, ovotestes will be present. In our case, there was no ovarian and testicular tissue in the streak gonads. Another common cause of primary amenorrhoea is Mayer-Rokitansky-Kuster-Hauser syndrome, where the karyotype is 46XX, with well-developed female secondary sexual characteristics, and absence or rudimentary uterus or vagina.⁷

There is high risk of malignant gonadal tumour development in patients with female phenotype carrying Y chromosome. In Swyer syndrome, there is high chance of gonadoblastoma and dysgerminoma, so gonadectomy is advised as soon as diagnosis of Swyer syndrome is established.² After gonadectomy, HRT is started for development of secondary sexual characteristics and menstruation. They can have normal sexual life and can have baby with donor oocyte.³ The limitation of this study was lack of genetic analysis for mutant genes due to unavailability.

To summarize, Swyer syndrome is a rare cause of primary amenorrhoea. Proper diagnosis is important as there is a high chance of gonadoblastoma, and the patient needs a gonadectomy. Due to advances in assisted reproductive techniques, pregnancy is possible with donor oocytes.

Acknowledgments

I would like to thank the patient and her parents for their cooperation.

Author Contributions

Conception and design- HKP. Acquisition, analysis, and interpretation of data- HKP. Manuscript drafting and revising it critically- HKP, GD, MKS. Approval of the final version of the manuscript- HKP, GD, MKS. Guarantor accuracy and integrity of the work- HKP.

Funding

This study did not receive any funding.

Conflict of Interest

The authors have no conflict of interest to declare.

Ethical Approval

The study being a case report does not have ethical approval from the institutional review board, but the patient and her parents gave consent for the photo and reporting.

ORCID iD

Hema Kumari Pradhan <https://orcid.org/0000-0003-1508-2099>

REFERENCES

1. Korkmaz H, Özkaya M, Akarsu E. Swyer Syndrome: A Case Report. *Turkish Journal of Endocrinology & Metabolism*. 2014; 18 (2) . DOI: <https://doi.org/10.4274/tjem.2365>.
2. Afsana F, Pathan MF, Shelly SJ. A Rare Case of Swyer Syndrome. *BIRDEM Medical Journal*. 2019 May 6;9(2):174-6. DOI: <https://doi.org/10.3329/birdem.v9i2.41289>.
3. Taneja J, Ogutu D, Ah-Moye M. Rare successful pregnancy in a patient with Swyer Syndrome. *Case Rep Women's Health*. 2016 Oct 18;12:1-2. DOI: <https://doi.org/10.1016/j.crwh.2016.10.001>.
4. Behtash N, Karimi Zarchi M. Dysgerminoma in three patients with Swyer syndrome. *World J Surg Oncol* 2007;5:71. DOI: <https://doi.org/10.1186/1477-7819-5-71>
5. Michala L, Goswami D, Creighton SM, Conway GS. Swyer syndrome: presentation and outcomes. *BJOG: An International Journal of Obstetrics & Gynaecology*. 2008 May;115(6):737-41. DOI: <https://doi.org/10.1111/j.1471-0528.2008.01703.x>.
6. Cherukuri S, Jajoo S S, Dewani D, Andela M. The Mysteries of Primary Amenorrhea: Swyer Syndrome. *Cureus*. 2022 Aug 19; 14(8): e28170. DOI: <http://dx.doi.org/10.7759/cureus.28170>.
7. Baker VL, Beall SA. Amenorrhea Chapter 34. Berek and Novak's Gynecology. 16th ed. Berek JS, Berek DL, editors. Wolters Kluwer, Philadelphia, 2020; p2034-88.
8. Khare J Deb P, Srivastava P, Reddy B H. Swyer syndrome: The gender swayer? *Alexandria Journal of Medicine* (2017) 53:2, 197–200. DOI: <https://doi.org/10.1016/j.ajime.2016.05.006>.