

Computer-Assisted Oral and Maxillofacial Reconstruction

Alexander Schramm¹, Ralf Schön², Martin Rücker¹, Enno-Ludwig Barth¹, Christoph Zizelmann² and N.-C. Gellrich¹

¹Department of Oral and Maxillofacial Surgery, Medical University of Hannover, Germany

²Department of Oral and Maxillofacial Surgery, University Hospital Freiburg, Germany

Ablative tumor surgery, orbital and mid face reconstruction as much as skull base surgery requires detailed planning using CT or MRI. Reconstruction is depending on reliable information to choose correct type of grafts and to predict the outcome. Benefits and indications of computer-assisted surgery in the treatment of cranio-maxillofacial surgery are demonstrated. Based on a CT or MRI data set, an optical navigation system was used for preoperative planning, intraoperative navigation and postoperative control. Surgery was preoperatively planned and intraoperatively navigated. Preoperatively, required soft and hard tissue was measured using the mirrored data set of the unaffected side; size and location of the graft were chosen virtually. Intraoperatively, contours of transplanted tissues were navigated to the preoperatively simulated reconstructive result. Preoperatively outlined safety margins could be exactly controlled during tumor resection. Reconstruction was designed and performed precisely as virtually planned. Image-guided treatment improves preoperative planning by visualization of the individual anatomy, intended reconstructive outcome and by objectivation the effect of adjuvant therapy. Intraoperative navigation makes tumor and reconstructive surgery more reliable by showing the safety margins, saving vital structures and leading reconstruction to preplanned objectives.

Keywords: computer-assisted surgery, navigational surgery, frameless stereotaxy, intraoperative navigation.

1. Introduction

Computer-assisted technology was initially developed to provide neurosurgeons with accurate guidance during surgical procedures. Stereotactic procedures were introduced to neuro surgery in the early 1980s, and currently systems with and without robotic navigation are in use for

specific medical indications. For oral and maxillofacial surgery nowadays, mechanical, electromagnetic and optic systems are available to perform navigational surgery by frameless stereotaxy. In the following pages, function and indications for frameless stereotaxy and computer-assisted treatment in oral and maxillofacial surgery are described.

2. Computer-Assisted Treatment

Clinical application of computer-assisted treatment is performed in three steps. The first step is the analysis of the problem, planning of treatment and simulation of surgical procedures. Part two is the navigational surgery performed as frameless stereotaxy. Step three consists of posttherapeutic control. Indications in traumatology are primary and secondary reconstruction of the orbit and the decompression of the optical nerve [1].

Indications in tumor surgery are minimal invasive biopsies, resections of extensive tumors of the midface and skull base — especially following adjuvant chemo- or radiotherapy — and primary and secondary reconstruction of the facial skeleton [2]. Although it is possible to navigate the insertion of dental implants in the maxilla and mandible, the indication is limited to insertion of zygomatic fixtures or extremely specific anatomical demands.

2.1. Frameless Stereotaxy

In Figure 1 function of an optic navigation system is described. Infrared localization of the tip of a surgical tool allows correlation of anatomic situation and patient's spiral CT or MRI data set. Defined reference points exposable in the anatomic situation and visible in the data set of the patient are needed for registration of the system.

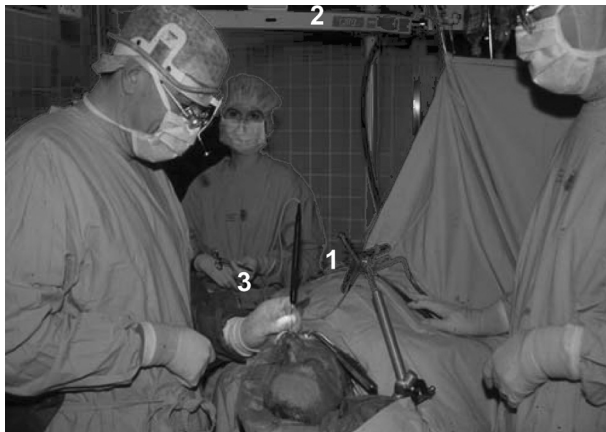


Fig. 1. Surgical Navigation Tool (Stryker-Leibinger, Germany): the infrared LED's of the pointer (1) are detected by the infrared cameras (2). Patient's head is fixed to a Mayfield clamp and movement is tracked by the dynamic reference frame (3).

Registration with anatomical landmarks or skin fiducial markers lack of accuracy, registration with devices fixed within the oral cavity interfere with surgical procedures [3,4]. Fiducial markers fixed to bone screws is invasive and limited to one surgical intervention a few days after data acquisition.

Non invasive registration for multiple use in the same patient can be achieved by fixing markers for CT or MRI scans to an individually performed occlusal splint (Fig. 2) with high accuracy (approximately 1 mm). Only in edentulous patients there is still a need for invasive markers fixed to intra- end extraoral temporary implants. Referencing of the navigation system is done by correlation of the outlined markers in the CT/MRI to the markers in the anatomic situs by the tracked tip of the pointer.

The head of the patient is normally fixed to a Mayfield clamp which is tracked by an dynamic reference frame to allow changing of the position during operation. Non invasive tracking

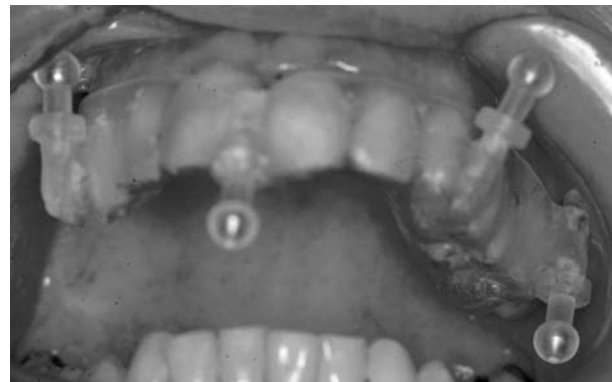

Fig. 2. Occlusal splint with markers for data acquisition in the CT (for MRI scans gadolinium filled markers are available).

can be achieved by fixing this dynamic reference frame to the occlusal splint. With this technique also navigational surgery of the mobile mandible can be performed. With frameless stereotaxy the surgeon is able to localize any desired anatomical structure with the pointer and lead the surgical intervention to the preplanned and simulated result. With specific technique he is also able to guide the tip of any tracked surgical tool (drill, fraise, chisel or endoscope) or to localize the focus of a surgical microscope.

2.2. Periorbital Reconstruction

In craniomaxillofacial surgery advances in imaging techniques (spiral-CT, 3D-imaging) and associated technologies (stereolithographic models, CAD/CAM) have led to improved preoperative planning within the past years. Stereolithography models are suitable to resemble the actual situation of the patient three-dimensional situation of hard tissue defects and allow to some degree pre- or intraoperative manufacturing of individual prostheses; they do not fulfill all the requirements for craniomaxillofacial plastic and reconstructive procedures i.e. preoperative planning with virtual correction, intraoperative navigation and postoperative control. Stereolithographic models resemble just one given situation within the greyscale of the acquired spiral-CT data set. They always imply the mistake of "pseudoforamina" in thin bony structures, which are widely present in the (peri-) orbital region.

In contrast, a spiral-CT data set allows information on a variety of either soft and hard tissue questions, which is just limited by the

way of transformation of the information from the radiologist to the craniomaxillofacial surgeon. However, to get sufficient information on the preoperative situation, the surgeon himself has to get familiar with the so called surgical anatomy. Modern navigation systems provide the possibility to handle easily the natively acquired CT-data set, so that the surgeon can adapt the greyscale and the reconstructions to his demands. This is very important, especially in cases of enophthalmus, to assess exactly the displacement of orbital contents. Furthermore, the spiral-CT/MRI data set can be used for measuring and virtual correction. The following procedures can be achieved:

1. Measurement of distances allows for exact intraindividual comparison of form.
2. Volume measuring allows for precise judgement on orbital contents.
3. Mirroring parts of the data set to an individually created treatment aim allows exact restoration of form in defined dimensions.
4. Virtual insertion and positioning of autologous bone grafts realizes preoperative simulation of augmenting defects within and around the orbit.
5. Outlining of vital and important anatomical structures like the optic nerve is easily possible.
6. Intraoperative navigation allows to check on anatomy online and to compare preoperatively planned contours with present situation before, during and after correction.

In cases where postoperative control spiral-CT/MRI are performed (extended craniofacial reconstructive surgery) changes between the preceding and the actual CT/MRI are easily assessable.

Especially in en- or exophthalmus cases, measurement of the sagittal projection can be done in the same position on the workstation like the patient will be on the operating table. The sagittal projection of the eyeball can virtually be marked and corrected. To assess asymmetry, proper measurement of distances between anatomic structures will help to determine the severity of a deformation. Within the orbit transverse, cranio-caudal and posterior-anterior measurement allow to determine areas of deficient bone and to evaluate how much grafted bone volume or reconfiguration of periorbital bone is necessary. By this procedure the surgeon himself is not limited to a subjective clinical estimation of the asymmetry, but he gets

familiar with the individual discrepancies in all three dimensions. The diagnostic value of the multiplanar assessment including the 3D-images is one of the most important features of the system.

Additionally to measuring functions, the volume rendering tool allows evaluation of affected and non affected orbital contents with individual mm^3 -figures. By this method the orbit can be directly compared to the other side. The majority of orbital deformities is unilateral, so that most of the cases can be approached by this side-to-side comparison. A further development of the idea to compare one side to the other is the mirroring tool (Fig. 3). The surgeon has to define the individual level to which the data set shall be mirrored from the unaffected to the deformed side, and he has to set the range, within which the mirroring process shall be performed. The software guides the surgeon step by step through this procedure. The optimal virtual reconstruction can be done and stored. During the operation these new contours can be navigated and serve as a control of the ongoing orbital reconstruction.

Furthermore, outlining of anatomical structures can be performed before the operation, so that during the corrective procedure structures such as the optic nerve can be avoided. Additionally, virtual limits for bone graft positions can be marked, so that calvarian split grafts are not placed beyond these marks. Intraoperatively either the native CT-data set or the modified CT-data set can be used, so that navigation of intraoperatively achieved reconstruction in comparison to preoperative virtual correction is possible at any step of the operation. This means a real innovation in planning and correction, especially of orbital deformities [5].

2.3. Optic Nerve Decompression

Traumatic optic neuropathy in severe skull base trauma cases requires decompression of the optic nerve if there is loss of vision due to dislocated bony fragments or if the vision decreases under drug therapy with high dose steroids. The operation is performed with a surgical microscope. Preoperative planning of the surgical approach can be transformed into the monitor of the microscope to navigate the surgeon to the optic canal (Fig. 4).

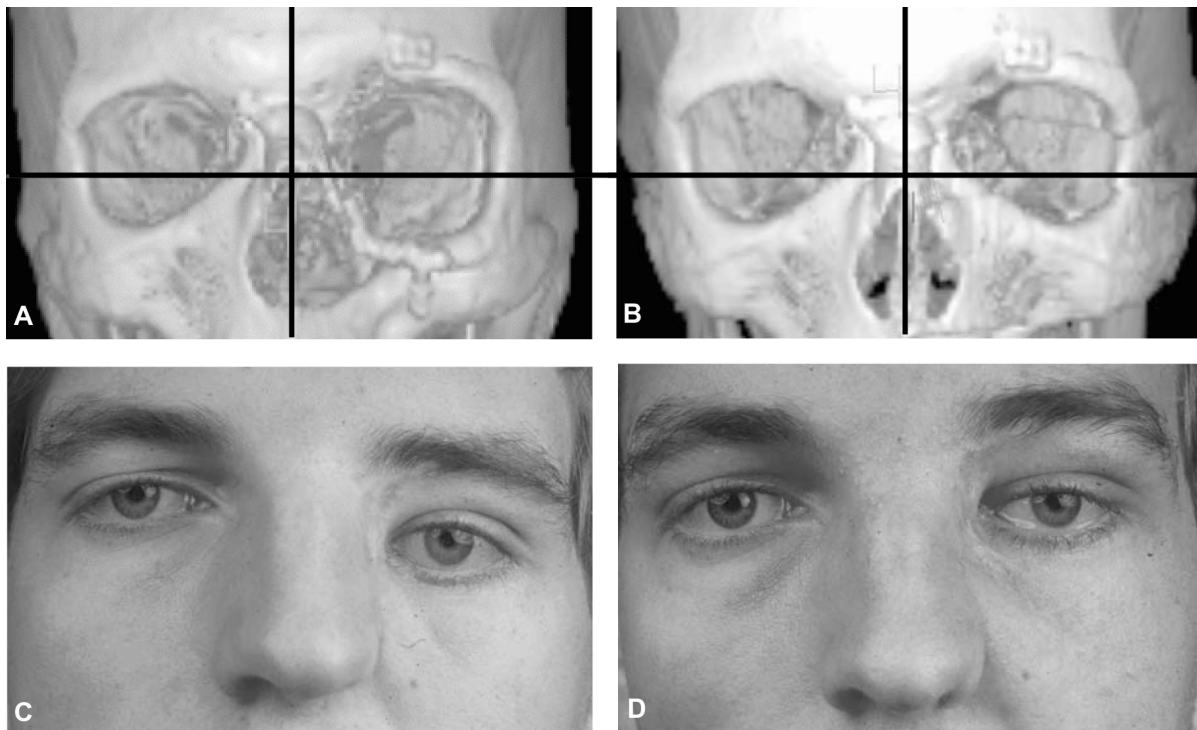


Fig. 3. Periorbital deformation: preoperative 3D reconstruction view (A) and clinical view (C). The simulation of the intended reconstruction result is performed mirroring the unaffected side in the CT data set (B). Orbital reconstruction was performed using navigational surgery. The clinical view 6 months after surgery is shown (D).

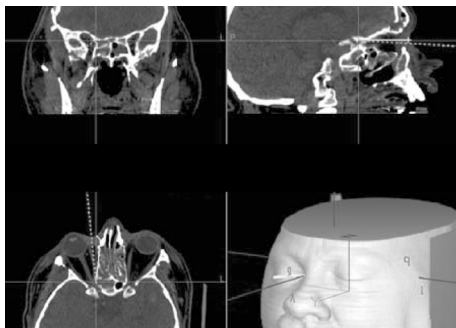


Fig. 4. Decompression of the optic nerve (intraoperative monitoring). The center of the cross shows the focus of the operation microscope. With this technique the surgeon is able to localize any structure of the anatomic situation.

The focus of the microscope is correlated to the CT data set, so the surgeon is able to identify the anatomic structures he sees through the lens by watching the CT scan at any time. Using frameless stereotaxy, the decompression of the optic nerve in trauma or tumor cases becomes a safe and predictable, as well as a minimally invasive procedure.

2.4. Tumor Surgery

Frameless stereotaxy allows minimal invasive approaches for biopsy of suspected tumors of the midface and skull base (Fig. 5) by guiding the surgeon, for example, via an intraoral approach to the pathologic process. Therefore, the safety of minimal invasive surgical procedures, such as endoscopic surgery of paranasal sinuses or skull base, biopsy of suspicious tissues and

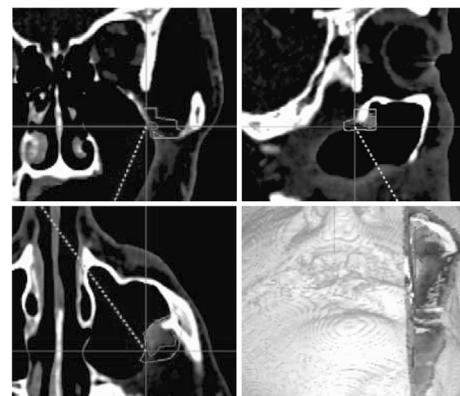


Fig. 5. Image-guided biopsy (intraoperative view). The center of the cross shows the tip of the tongue on the posterior wall of the left maxillary sinus.

tumor resections through an intraoral approach, are increased by intraoperative navigation.

Treatment of malignancies in cranio-maxillofacial surgery however requires more than exact localization of anatomical structures. Ablative tumor surgery requires detailed and exact planning using computed tomography (CT) and/or magnetic resonance imaging (MRI) to show extension of the malignoma, to define intended safety margins and to point out relevant structures. Adjuvant pre-, intra- or postoperative chemo- and radiotherapy requires the informations also. Reconstruction following tumor resection, especially in the midface and orbit regions, demand reliable information also to choose correct type and volume of grafts and to predict the outcome.

Computer-assisted treatment improves preoperative analyzing by combining CT and MRI data for valid 3D visualization of the anatomy position. Pre- and posttherapeutic tumor volume (surgery, chemotherapy, radiotherapy) can be assessed precisely in three dimensions to prove the efficiency of adjuvant therapies and to detect recurrences. The pretherapeutic tumor volume can be transferred to the latest dataset to perform resection within the pretherapeutic borderlines (Fig. 6) increasing radicality of treatment. Immediate reconstruction of severe cranio-maxillofacial deformities after tumor resection can be easily performed by navigational surgery using the pretherapeutic CT scan as a perfect simulation of the intended reconstruction result).

Intraoperative navigation makes radical tumor surgery more reliable by facilitating the safety margins, saving vital structures, guiding the radiation tube, especially in intraoperative irradiation and primary reconstruction, according to the preoperative situs. In secondary reconstruction cases the needed size and shape of the graft can be assessed preoperatively and intraoperatively, their position can be precisely controlled [6].

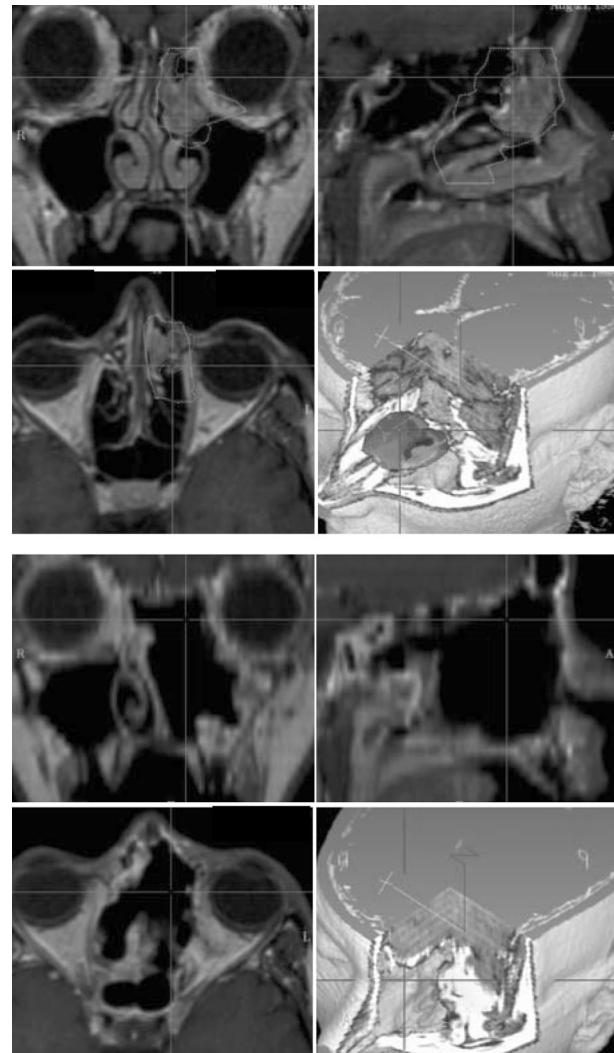


Fig. 6. Esthesioneuroblastoma after adjuvant chemotherapy (upper part). The original tumor (outer margin) volume before chemotherapy was transferred to the data set to facilitate resection inside the pretherapeutic margins. The postoperative control (lower part) demonstrates radical resection and adequate immediate reconstruction of the left orbit.

2.5. Oral Implantation

Installation of fixtures for prosthetic reconstruction in the upper jaw in patients with extensive bone and soft tissue defects is still a challenge. These situations usually require the support of vascularized bone or composit grafts and secondary insertion of endosseous implants. The zygomatic fixture (Brånemark System, Nobel Biocare, Köln, Germany) provides additional support in the above described situations by anchoring implants in the zygomatic bone. The dimension of these zygomaticus fixtures and the

complex anatomy due to previous surgical procedures demand specific treatment for a precise and safe insertion of the implants. Preoperative planning and intraoperative monitoring of the navigationally guided position of zygomatic fixtures after subtotal maxillectomy seems to be a helpful device. Bilateral insertion of zygomatic fixtures added to standard Brånemark fixtures placed in the remaining anterior maxillary bone or unilateral insertion of two parallel zygomatic implants after partial resection of the maxilla, are facilitated for navigational surgery (Fig. 7). The use of zygomatic fixtures after ablative tumor surgery with resection of the maxillary bone provides immediate prosthetic reconstruction without additional bone grafting. Computer-assisted insertion of these implants improves preoperative planning by 3D

visualization of the anatomic situs and virtual positioning of the fixture and facilitates clinical procedure by guiding the drill to the intended position [7].

In case of extensive preprosthetic bone grafting procedures the computer-assisted planning of insertion of dental implants allows the preoperative comparison between prosthetic demands for the implant axis and bony tissue. The intraoperative navigation of the insertion of standard dental implants in the maxilla and in the mandible has no benefits compared to standard insertion techniques. The higher radiation dose for using CT scans instead of panoramic X-rays demands restrictive use of navigation in oral implantation [8].

3. Conclusion

The higher radiation dose of the CT scan demands restrictive use of navigation systems. Precise registration of the system is the mean precondition to reach acceptable accuracy. For the described indications in cranio-maxillofacial surgery navigational surgery is a helpful tool for minimally invasive surgery, increasing radicality of tumor treatment, preventing damaging of vital structures and leading the reconstruction to preplanned, defined results. Indications are tumors of the midface and skull base, orbital and midface reconstruction, optic nerve decompression, complex orthognathic and cranio-facial surgery and the insertion of zygomatic fixtures. Future perspectives are simulation of multiple osteotomies and moving various fragments to achieve virtual surgery for any kind of oral and cranio-maxillofacial surgery.

References

- [1] R. SCHMELZEISEN, R. SCHÖN, A. SCHRAMM, N.-C. GELLRICH, Computer-aided procedures in implantology, distraction and cranio-maxillofacial surgery. *Ann R Australas Coll Dent Surg* 16, (2003), pp. 46–49.
- [2] N.-C. GELLRICH, A. SCHRAMM, B. HAMMER, S. ROJAS, D. CUFI, W. LAGRÈZE, R. SCHMELZEISEN, Computer-assisted secondary reconstruction of unilateral posttraumatic orbital deformities. *Plast Reconstr Surg* 110, (2002), pp. 1417–1429.

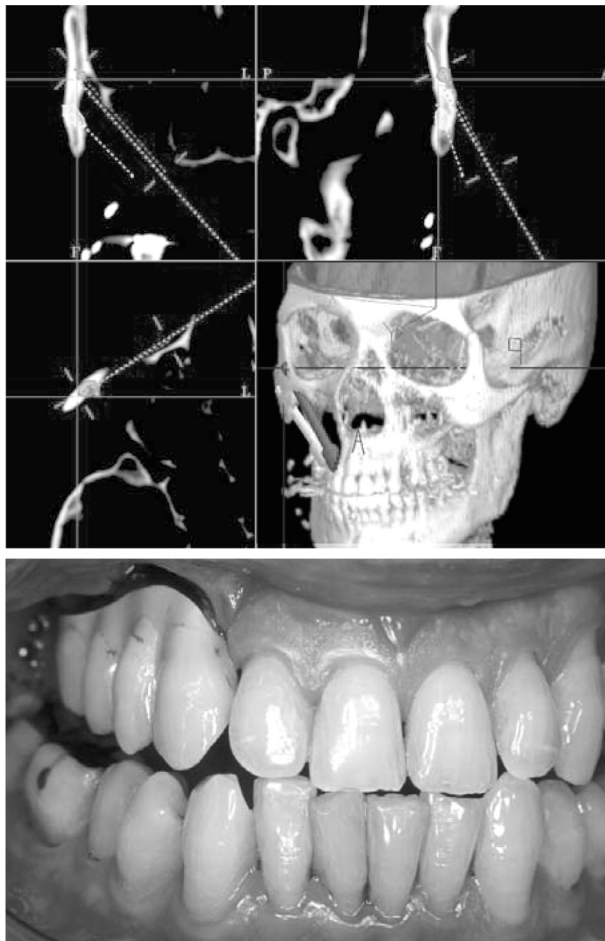


Fig. 7. Computer-assisted insertion of two zygomatic implants (intraoperative view). The center of the cross shows the tip of the drill, the dotted line shows the angulation of the drill. The clinical view after prosthodontic restoration demonstrates the sufficient esthetic result.

- [3] C. KLUG, K. SCHICHO, O. PLODER, K. YERIT, F. WATZINGER, R. EWERS, A. BAUMANN, A. WAGNER, Point-to-Point Computer-Assisted Navigation for Precise Transfer of Planned Zygoma Osteotomies from the Stereolithographic Model into Reality. *J Oral Maxillofac Surg* 64, (2006), pp. 550–559.
- [4] R. EWERS, K. SCHICHO, A. WAGNER, G. UNDT, R. SEEMANN, M. FIGL, M. TRUPPE, Seven years of clinical experience with teleconsultation in craniomaxillofacial surgery. *J Oral Maxillofac Surg* 10, (2005), pp. 1447–1454.
- [5] R. SCHMELZEISEN, N.-C. GELLRICH, R. SCHÖN, R. GUTWALD, C. ZIZELMANN, A. SCHRAMM, Navigation-aided reconstruction of medial orbital wall and floor contour in cranio-maxillofacial reconstruction. *Int J Oral Maxillofac Surg* 19, (2004), pp. 753–757.
- [6] J. HOFFMANN, C. WESTENDORFF, G. GOMEZ-ROMAN, S. REINERT, Accuracy of navigation-guided socket drilling before implant installation compared to the conventional free-hand method in a synthetic edentulous lower jaw model. *Clin Oral Implants Res* 16, (2005), pp. 609–614.
- [7] A. SCHRAMM, N.-C. GELLRICH, R. GUTWALD, J. SCHIPPER, H.G. BLOSS, H. HUSTEDT, R. SCHMELZEISEN, J.-E. OTTEN, Indications for computer-assisted treatment of cranio-maxillofacial tumors. *Comp Aided Surg* 5, (2000), pp. 343–352.
- [8] R. MARMULLA, H. HOPPE, J. MUHLING, G. EGGERS, An augmented reality system for image-guided surgery. *Int J Oral Maxillofac Surg* 34, (2005), pp. 594–596.

Received: January, 2006
Accepted: February, 2006

Contact address:

Alexander Schramm
Dept. of OMFS
Medical School Hannover
Carl-Neubergstrasse 1
D-30625 Hannover
Germany
e-mail: schramm.alexander@mh-hannover.de

ALEXANDER SCHRAMM is an associate professor and vice-chairman in the Oral and Maxillofacial Department of the Medical School in Hannover, Germany.

RALF SCHÖN is an assistant professor in the Oral and Maxillofacial department of the University Hospital Freiburg, Germany.

MARTIN RÜCKER is an assistant professor in the Oral and Maxillofacial department of the Medical School in Hannover, Germany.

ENNO-LUDWIG BARTH is a fellow in the Oral and Maxillofacial department of the Medical School in Hannover, Germany.

CHRISTOPH ZIZELMANN is a resident in the Oral and Maxillofacial department of the University Hospital Freiburg, Germany.

N.-C. GELLRICH is the chairman of the Oral and Maxillofacial department of the Medical School in Hannover, Germany.
