

Two neutrophilic dermatoses captured simultaneously on histology

Christina Wlodek¹, Nidhi Bhatt², Cameron Kennedy¹

¹ Department of Dermatology, Bristol Royal Infirmary, Bristol, UK

² Department of Pathology, Bristol Royal Infirmary, Bristol, UK

Key words: neutrophilic dermatosis, neutrophilic eccrine hidradenitis, Sweet's syndrome

Citation: Wlodek C, Bhatt N, Kennedy C. Two neutrophilic dermatoses captured simultaneously on histology. *Dermatol Pract Concept* 2016;6(3):11. doi: 10.5826/dpc.0603a11

Received: December 14, 2015; **Accepted:** May 27, 2016; **Published:** July 31, 2016

Copyright: ©2016 Wlodek et al. This is an open-access article distributed under the terms of the Creative Commons Attribution License, which permits unrestricted use, distribution, and reproduction in any medium, provided the original author and source are credited.

Funding: None.

Competing interests: The authors have no conflicts of interest to disclose.

All authors have contributed significantly to this publication.

Corresponding author: Christina Wlodek, BSc, MBBS, Bristol Royal Infirmary, Department of Dermatology, Upper Maudlin Street, Bristol BS2 8HW, United Kingdom. Tel. 0117 923 000; Fax. 0117 342 2845. Email: christina.wlodek@gmail.com

ABSTRACT A number of neutrophilic dermatoses are associated with malignancies and their treatment. These rarely occur together in the same patient.

A Caucasian 72-year-old male was treated for acute myeloid leukemia (AML) with chemotherapy including daunorubicin and cytarabine. Within 48 hours of commencing treatment, he developed pyrexia and, two days later, disseminated non-tender pink plaques on the limbs and trunk. A skin biopsy showed a dermal interstitial infiltrate of lymphocytes, histiocytoid cells and predominantly neutrophils. This extended into the subcutis, where a neutrophilic lobular panniculitis was seen. These findings are consistent with Sweet's syndrome. In addition, a neutrophilic and lymphocytic infiltrate was also present around eccrine coils and lower ducts. The eccrine epithelium showed squamous metaplasia with dyskeratosis and sloughing into the lumen. These latter findings are consistent with neutrophilic eccrine hidradenitis (NEH).

These two histologically distinct entities form part of the neutrophilic dermatoses that have been described in oncology patients with reports of concurrent or sequential occurrence of various neutrophilic dermatoses in the same patient. Ours, however, is only the second reported case of simultaneously captured Sweet's and NEH in the setting of AML. The most likely explanation is that of an epiphenomenon, whereby the neutrophilic infiltrate extended around the sweat glands in the context of the neutrophilic dermatosis.

Case presentation

A 72-year-old male with a recent diagnosis of acute myeloid leukemia (AML) had been commenced on chemotherapy—daunorubicin and cytarabine. He was also on ciprofloxacin, posaconazole and acyclovir for antimicrobial prophylaxis.

Within forty-eight hours of starting chemotherapy, he developed fever of 40°C and was commenced on piperacillin-tazobactam. On day 4 of chemotherapy a rash was noted. He was pancytopenic with an absolute neutrophil count of $0.34 \times 10^9/L$ and a platelet count of $20 \times 10^9/L$. C-reactive protein was raised at 322mg/L and a septic screen

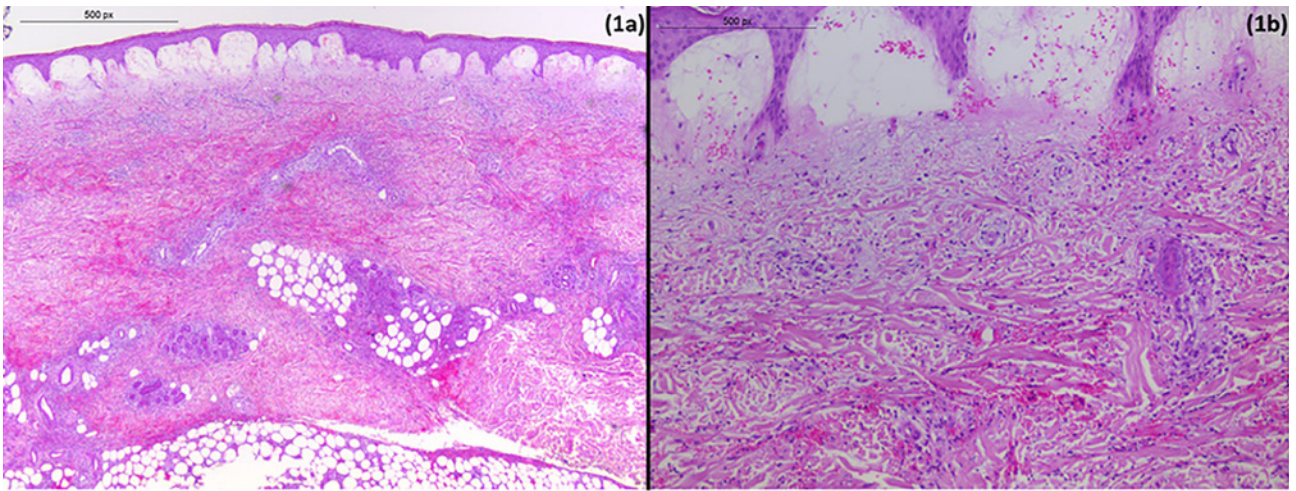


Figure 1. (a) A scanning power view showing subepidermal edema and a diffuse infiltrate throughout the dermis and subcutis. (b) High power view of neutrophils within the dermis. Note the absence of vasculitis. Hematoxylin and eosin, original magnification (a) x40 (b) x100. [Copyright: ©2016 Wlodek et al.]

was negative. Granulocyte-colony stimulating factor was not administered.

At the time of dermatology review, the patient had been pyrexial for four days. He had disseminated non-tender pink plaques on the limbs and trunk. Some lesions were imminently vesicular while others hemorrhagic. Since the rash was asymptomatic no treatment was felt necessary. An incisional biopsy was performed. Within 7 days the eruption resolved.

The skin biopsy showed subepidermal edema (Figure 1a), with no interface damage. There was extensive red cell extravasation in the dermis and an interstitial infiltrate of lymphocytes, histiocytoid cells and predominantly neutrophils. This extended into the subcutis, where a neutrophilic lobular panniculitis was seen. There was no evidence of vasculitis (Figure 1b). A second striking abnormality was centered around the eccrine coils and lower ducts (Figure 2a). The eccrine epithelium showed squamous metaplasia

(Figure 2b) with dyskeratosis and sloughing into the lumen. Surrounding these changes there was a neutrophilic and lymphocytic infiltrate. Fungal, bacterial and mycobacterial cultures were negative.

To our knowledge this is only the second reported case of concomitant Sweet-like neutrophilic dermatosis and neutrophilic eccrine hidradenitis (NEH) in the setting of AML.

Since the original description by R. D. Sweet in 1964, acute febrile neutrophilic dermatosis (Sweet's syndrome) is known to be associated with leukemia and in particular the acute myelomonocytic type [1]. Histology typically demonstrates a dense infiltrate of mature neutrophils in the upper half of the dermis but the location of the infiltrate can vary. Less commonly the neutrophils are perivascular. Neutrophils can also migrate into the epidermis or underlying adipose tissue [2]. To the best of our knowledge there are no literature reports of the neutrophilic infiltrate involving the eccrine glands.

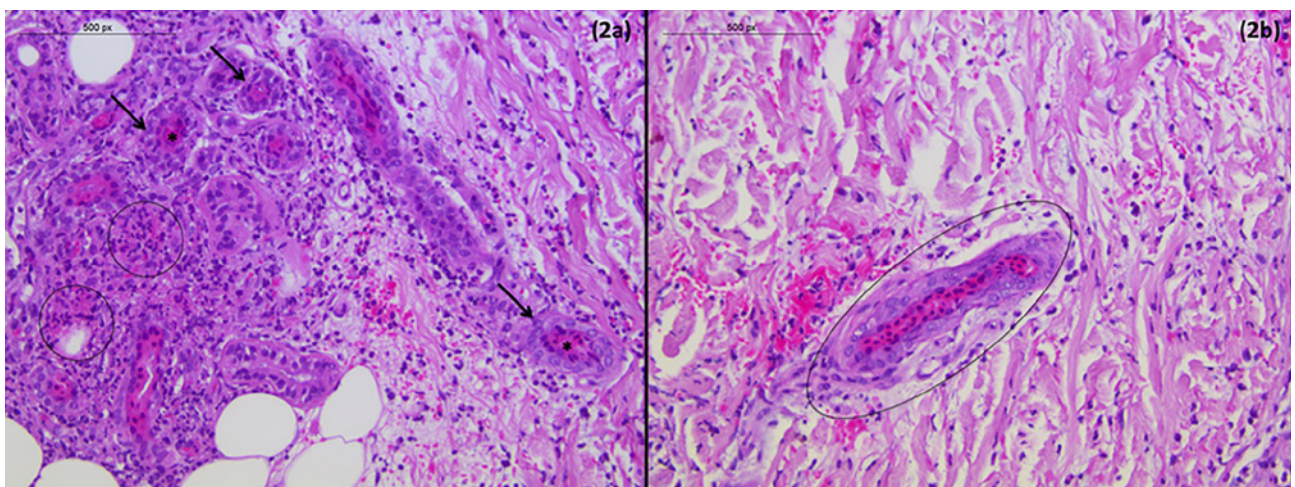


Figure 2. (a) High power view of neutrophilic infiltration of eccrine sweat glands (arrows) and epithelial necrosis (circled) together with intraluminal necrotic eosinophilic debris (*). (b) Upper part of eccrine duct showing squamous metaplasia (circled). Hematoxylin and eosin, original magnification (a) x200 (b) x300. [Copyright: ©2016 Wlodek et al.]

A few lymphocytes are typically present in older lesions, in a perivascular pattern. Vasculitis is usually absent [3], although a secondary leukocytoclastic vasculitis has been described in several cases [2].

NEH is a more recently characterized entity—first reported in a patient treated with cytarabine for AML [4]. Since then, other malignancies and chemotherapeutic agents have been implicated. The histological hallmark is a neutrophilic infiltrate around and within eccrine secretory coils often associated with vacuolar degeneration and even necrosis of the secretory epithelium. The NEH literature does not report any neutrophilic infiltrates away from the eccrine sweat glands. In the setting of neutropenia the infiltrate may be sparse [5]. Squamous metaplasia is occasionally seen.

The pathologic mechanism of NEH remains unclear. It was postulated to be linked to the high concentrations of chemotherapy drugs secreted into eccrine glands, however cases of NEH have been seen in the absence of chemotherapy and AML [6].

These two histologically distinct entities form part of the neutrophilic dermatoses that have been described in oncology patients. There are reports of concurrent or sequential occurrence of various neutrophilic dermatoses in the same patient [7]. However, ours is the second reported case of simultaneous Sweet-like neutrophilic dermatosis and NEH. There is a case similar to ours where there was a background of AML treated with chemotherapy, including cytarabine, in a patient with both Sweet's and NEH. The patient suffered a recurrence of the eruption when a relapse of the AML was treated with chemotherapy, but did not have a recurrence when consolidation chemotherapy was given during remission [8]. Our patient did have a recurrence of AML 8 weeks after completing his second cycle of chemotherapy. Since then he has been on azacitidine (an antimetabolite) to control disease progression. To date he has not experienced a recurrence of the cutaneous eruption. Another case of concomitant Sweet's plus NEH reported in the Tunisian literature appeared to be idiopathic [9].

Conclusion

Since Sweet's syndrome was initially recognized, the spectrum

of pathological changes described has expanded. There can be variability in the composition of the infiltrate as well as its depth. We could hypothesize that this case describes yet a further expansion of the pathological description. However, the occurrence of these two entities concurrently, in this same patient, is not entirely unexpected. The patient had a hematological malignancy well known to be associated with Sweet's syndrome and at the same time was receiving an agent, cytarabine, that has a well-established association with NEH. Thus we feel the most likely explanation is that of an epiphenomenon, where by the neutrophilic infiltrate has extended around the sweat glands in the context of the neutrophilic dermatosis.

References

1. Cohen PR. Sweet's syndrome—a comprehensive review of an acute febrile neutrophilic dermatosis. *Orphanet J Rare Dis* 2007;2(1):34. PMID: 17655751. DOI: 10.1186/1750-1172-2-34.
2. Cohen PR, Kurzrock R. Sweet's syndrome revisited: a review of disease concepts. *Int J Dermatol* 2003;42(10):761-78. PMID: 14521689. DOI: 10.1046/j.1365-4362.2003.01891.x.
3. Greer KE, Cooper PH. Sweet's syndrome (acute febrile neutrophilic dermatosis). *Clin Rheum Dis* 1982;8(2):427-41. PMID: 6754235.
4. Harrist TJ, Fine JD, Berman RS, Murphy GF, Mihm MC, Jr. Neutrophilic eccrine hidradenitis. A distinctive type of neutrophilic dermatosis associated with myelogenous leukemia and chemotherapy. *Arch Dermatol* 1982;118(4):263-6. PMID: 6950689. DOI: 10.1001/archderm.1982.01650160053024.
5. Allegue F, Soria C, Rocamora A, Munoz E, et al. Neutrophilic eccrine hidradenitis in two neutropenic patients. *J Am Acad Dermatol* 1990;23(6 Pt 1):1110-3. PMID: 2273110.
6. Kuttner BJ, Kurban RS. Neutrophilic eccrine hidradenitis in the absence of an underlying malignancy. *Cutis* 1988;41(6):403-5. PMID: 3391045.
7. Cohen PR. Neutrophilic dermatoses occurring in oncology patients. *Int J Dermatol* 2007;46(1):106-11. PMID: 17214733. DOI: 10.1111/j.1365-4632.2006.02605.x.
8. Gross PR, Margolis D. Neutrophilic dermatosis versus neutrophilic eccrine hidradenitis. *N Engl J Med* 1999;340(17):1371. PMID: 10223880. DOI: 10.1056/NEJM199904293401718.
9. Zehani A, Chelly I, Abdelmalek R, et al. [Adult idiopathic neutrophilic eccrine hidradenitis mimicking Sweet's syndrome]. *Tunis Med* 2013;91(5):366-7 PMID: 23716340.