

# Dermatoscopy: What is your diagnosis?

Philipp Tschandl, M.D.<sup>1</sup>

<sup>1</sup> Department of Dermatology, Division of General Dermatology, Medical University of Vienna, Austria

**Citation:** Tschandl P. Dermatoscopy: What is your diagnosis? *Dermatol Pract Conc*. 2012;2(3):9. <http://dx.doi.org/10.5826/dpc.0203a09>.

**Copyright:** ©2012 Tschandl. This is an open-access article distributed under the terms of the Creative Commons Attribution License, which permits unrestricted use, distribution, and reproduction in any medium, provided the original author and source are credited.

**Corresponding author:** Philipp Tschandl, M.D., Department of Dermatology, Division of General Dermatology, Medical University of Vienna, Währinger Gürtel 18-20, 1090 Vienna, Austria. Tel. +43.1.40400.7700; Fax: +43. 1.408.19.28. E-mail: philipp.tschandl@meduniwien.ac.at.

## Quiz

A 19-year-old male patient presented with a yellow nodular lesion on the scalp with dark eccentric pigmentation (Figure 1). Dermatoscopy reveals a structureless yellow area combined with serpentine branched vessels and a large blue clod (Figure 2). What is your diagnosis?

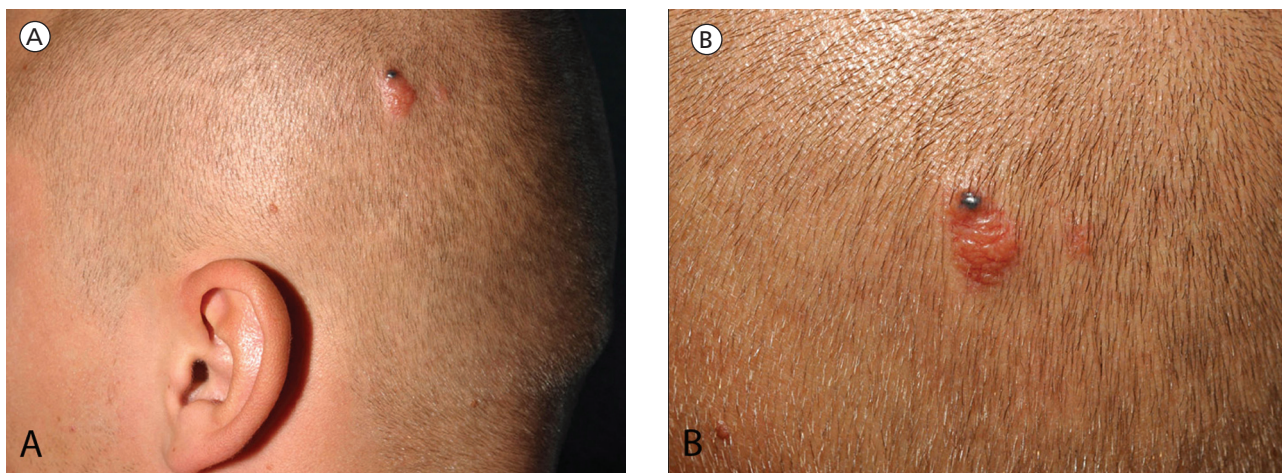


Figure 1. A—Clinical picture of a papular lesion on the scalp. B—Clinical closeup. [Copyright: ©2012 Tschandl.]

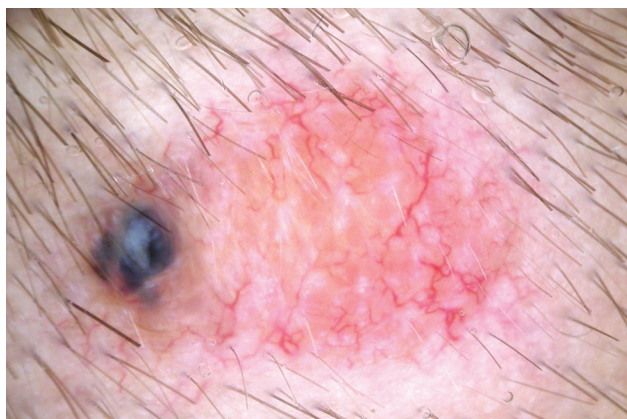


Figure 2. Dermatoscopy: A structureless yellow to orange area, a single blue clod, and serpentine branched vessels can be seen. [Copyright: ©2012 Tschandl.]

Please send your answer to [dpc@derm101.com](mailto:dpc@derm101.com). The first to respond with the correct answer will receive a complimentary copy of the book, *Dermoscopy: An Algorithmic Method Based on Pattern Analysis* [Facultas Verlag, 2011].

The case and the answer to the question will be presented in the next issue of *Dermatology Practical and Conceptual*.

## Answer to April 2012 quiz

The correct answer to the quiz in the April 2012 issue is **xanthogranuloma**.

Please see article 3 of this issue of *Dermatology Practical and Conceptual* for a detailed description of xanthogranuloma with dermatoscopic/dermatopathologic correlation [<http://dx.doi.org/10.5826/dpc.0203a03>].

Congratulations to Iara Trocoli Drakensjö, who was the first to send us the correct answer to this quiz!