

Dermatoscopy: What is your diagnosis?

Philipp Tschandl, M.D.¹

¹Department of Dermatology, Division of General Dermatology, Medical University of Vienna, Austria

Citation: Tschandl P. Dermatoscopy: What is your diagnosis? *Dermatol Pract Conc.* 2012;2(4):10. <http://dx.doi.org/10.5826/dpc.0204a10>.

Copyright: ©2012 Tschandl. This is an open-access article distributed under the terms of the Creative Commons Attribution License, which permits unrestricted use, distribution, and reproduction in any medium, provided the original author and source are credited.

Corresponding author: Philipp Tschandl, M.D., Department of Dermatology, Division of General Dermatology, Medical University of Vienna, Währinger Gürtel 18-20, 1090 Vienna, Austria. Tel. +43 1 40400 7700; Fax. +43 1 408 19 28. Email: philipp.tschandl@meduniwien.ac.at.

Quiz

A 30-year-old male patient presented with a small, brown papule on the calf (Figure 1). By dermatoscopy one can see radial lines in some segments at the periphery and skin-colored and pink structureless zones (Figure 2). What is your diagnosis?

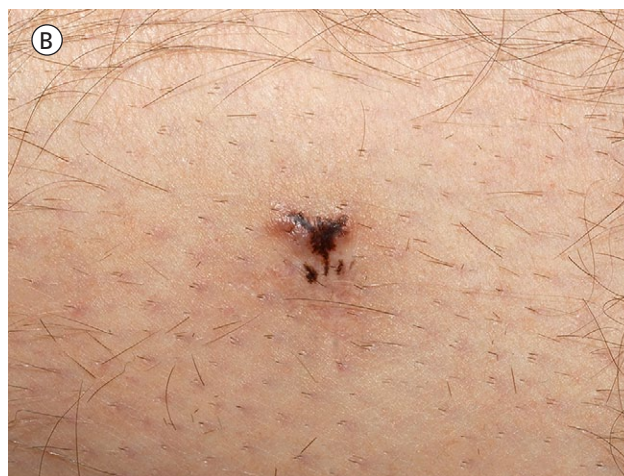
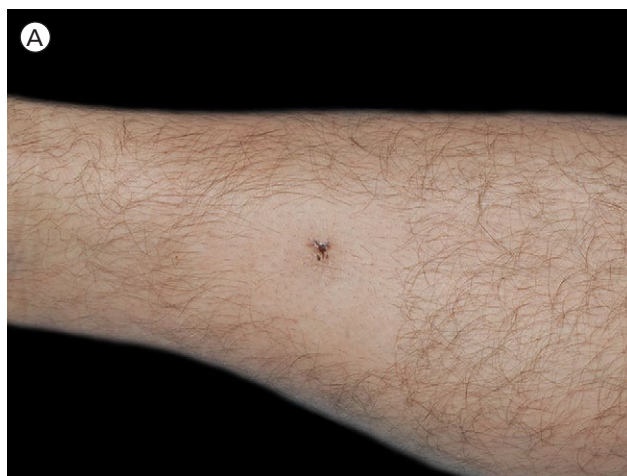
Figure 1. (A) Clinical picture of a small brown papule. (B) Clinical closeup. [Copyright: ©2012 Tschandl]

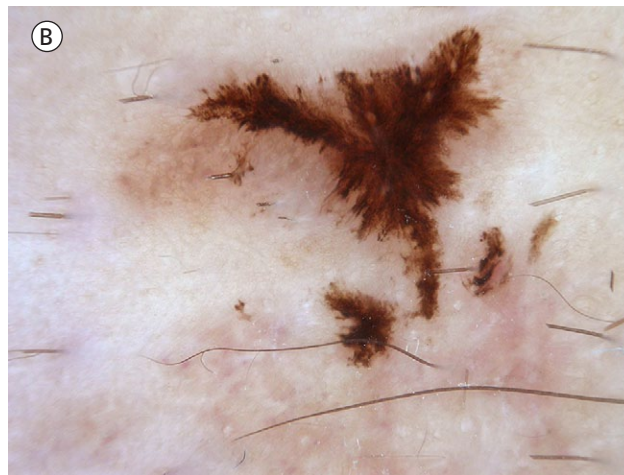
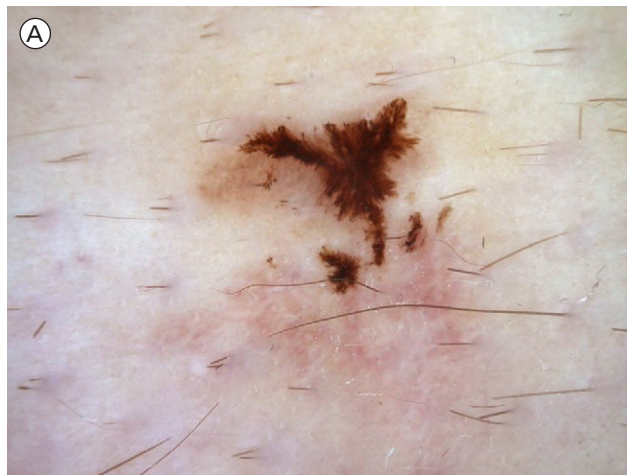


Figure 2. (A) Dermatoscopically, prominent radial lines can be seen at the periphery and skin-colored and pink structureless zones. (B) Dermatoscopic closeup. [Copyright: ©2012 Tschandl]

Please send your answer to dpc@derm101.com. The first correct answer will receive a complimentary copy of the book, *Dermatoscopy. An Algorithmic Method Based on Pattern Analysis* [Facultas Verlag, 2011].

The case and the answer to the question will be presented in the next issue of *Dermatology Practical and Conceptual*.

Answer to July 2012 quiz

The correct answer to the dermatoscopy quiz in the July 2012 issue is **spiradenoma**.

Please see article 9 of this issue of *Dermatology Practical and Conceptual* for a detailed description of this quiz case with dermatoscopic/dermatopathologic correlation (<http://dx.doi.org/10.5826/dpc.0204a09>).