

Golden Lady

Andrina Neff¹, Alexandra Valeska Matter¹, Isabel Kolm¹

¹ Department of Dermatology, University Hospital of Zurich, Switzerland

Key words: plane xanthoma, monoclonal gammopathy, lymphoproliferative disease, hyperlipidemia

Citation: Neff A, Matter AV, Kolm I. Golden lady. *Dermatol Pract Concept*. 2021;11(1):e2021134. DOI: <https://doi.org/10.5826/dpc.1101a134>

Accepted: August 2, 2020; **Published:** January 29, 2021

Copyright: ©2021 Neff et al. This is an open-access article distributed under the terms of the Creative Commons Attribution License BY-NC-4.0, which permits unrestricted noncommercial use, distribution, and reproduction in any medium, provided the original author and source are credited.

Funding: None.

Competing interests: The authors have no conflicts of interest to disclose.

Authorship: All authors have contributed significantly to this publication.

Corresponding author: Isabel Kolm-Djamei, MD, Department of Dermatology, University Hospital of Zurich, Gloriastrasse 31, 8091 Zurich, Switzerland. Email: Isabel.Kolm-Djamei@usz.ch

Case Presentation

A 93-year-old woman presented with confluent yellow plaques with an intense golden glow symmetrically on the neck and lateral face (Figure 1, A and B) mimicking a golden camou-

flage. The histopathology showed CD68-positive foamy macrophages in the papillary dermis (Figure 1, C and D), leading to the diagnosis of plane xanthoma. Our patient showed mild dyslipidemia (total cholesterol 6.4 mmol/l [<5.0 mmol/l]). Clinical stigmata for familial hyperlipidemia were not pres-

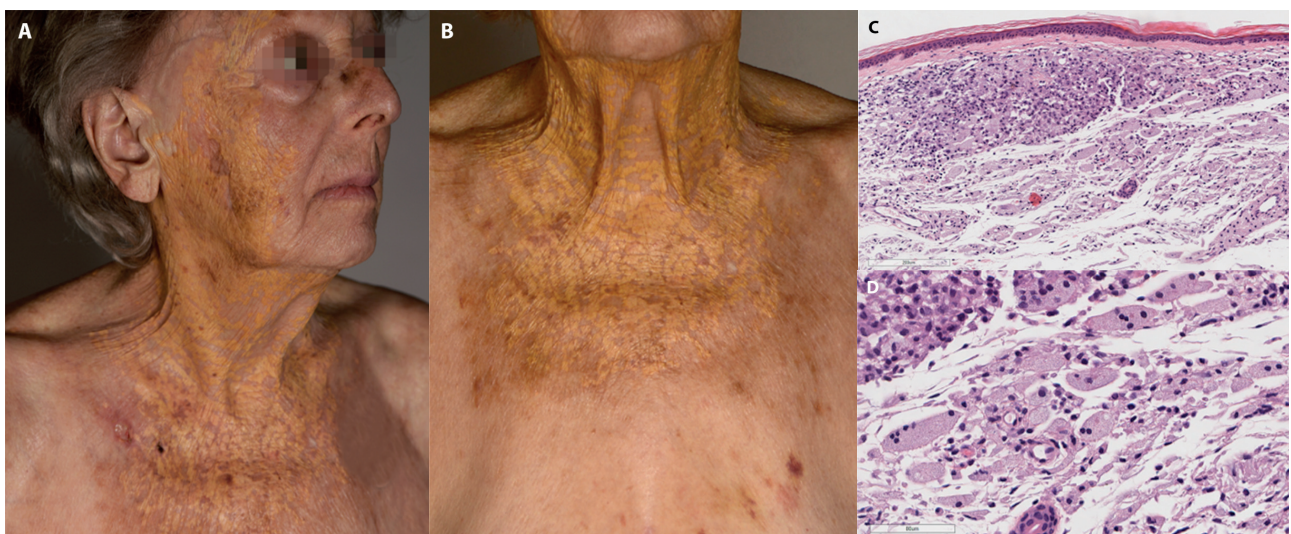


Figure 1. (A, B) Remarkable presentation of plane xanthoma on the neck and lateral face with a golden hue in a 93-year-old woman. (C, D) Histopathology of plane xanthoma with CD68-positive foamy macrophages in the papillary dermis.

ent. Due to the distribution pattern, underlying hematological disorders were ruled out.

Teaching Point

The location of plane xanthomas can serve as a clue to a particular underlying disease. Plane xanthomas in a normolipemic patient with favored distribution on the neck, upper trunk, and flexural folds should prompt a search of underlying hematological disorders such as monoclonal gammopathy or lymphoproliferative disease [1,2]. Plane xanthomas can

precede such disorders by several years; therefore, a regular follow-up is recommended.

References

1. Cohen YK, Elpern DJ. Diffuse normolipemic plane xanthoma associated with monoclonal gammopathy. *Dermatol Pract Concept*. 2015;5(4):65-67. DOI: 10.5826/dpc.0504a16. PMID:26693095.
2. Morsink LM, Nijhof IS. Diffuse plane normolipemic xanthomatosis as a manifestation of monoclonal gammopathy. *Br J Haematol*. 2019;187(4):411. DOI: 10.1111/bjh.16141. PMID:31407310.