

Evaluation of Diagnostic Accuracy and Therapeutic Approach of Dermatologists and Plastic Surgeons To Non-Melanocytic Skin Lesions By Using Telemedicine

Burcu Tugrul¹, Basak Yalici-Armagan², Hatice Gamze Demirdag³, Ozge Gunduz⁴

1. Ankara City Hospital, Department of Dermatology, Ankara, Turkey.
2. Hacettepe University, Faculty of Medicine, Department of Dermatology, Ankara, Turkey.
3. Private Practice, Hatice Gamze Demirdag Dermatology Clinic, Ankara, Turkey.
4. Midnorth Coast Dermatology, 31 Wyandra Crescent Port Macquarie 2444 NSW, Australia.

Key words: telemedicine, teledermatology, teledermoscopy, non-melanocytic skin lesion, diagnostic accuracy

Citation: Tugrul B, Yalici-Armagan B, Demirdag HG, Gunduz O. Evaluation of diagnostic accuracy and therapeutic approach of dermatologists and plastic surgeons to non-melanocytic skin lesions by using telemedicine. *Dermatol Pract Concept.* 2022;12(3):e2022124. DOI: <https://doi.org/10.5826/dpc.1203a124>

Accepted: November 1, 2021; **Published:** July 2022

Copyright: ©2022 Tugrul et al. This is an open-access article distributed under the terms of the Creative Commons Attribution-NonCommercial License (BY-NC-4.0), <https://creativecommons.org/licenses/by-nc/4.0/>, which permits unrestricted noncommercial use, distribution, and reproduction in any medium, provided the original authors and source are credited.

Funding: None.

Competing interests: None.

Authorship: All authors have contributed significantly to this publication.

Corresponding author: Burcu Tugrul, MD, Ankara City Hospital, Department of Dermatology, Bilkent, Çankaya, 06800, Ankara, Turkey, E-mail address: burcutugrul@yahoo.com

ABSTRACT Introduction: In the new circumstances of coronavirus disease 2019 pandemic, tele-dermatology and tele-dermoscopy have become more important in daily practice for departments for which visuality is at the forefront as dermatology and plastic and reconstructive surgery.

Objectives: This study was aimed to determine diagnostic accuracy and treatment approaches of non-melanocytic skin lesions between 2 clinics by store and forward tele-dermatology method and to evaluate the contribution of tele-dermoscopy to the diagnostic accuracy for dermatologists.

Methods: A total of 26 patients with non-melanocytic skin lesions were included in the study. Clinical images of the lesions were sent by email to 3 plastic surgeons and 3 dermatologists. The accuracy of the diagnoses was evaluated by comparing tele-dermatology with histopathology. Diagnosis and treatment approaches were recorded for both clinics. Dermatologists also defined their diagnosis with tele-dermoscopic images.

Results: The mean percentage of diagnostic accuracy among dermatologists was 74.3% and among plastic surgeons was 61.5%. There was no significant difference in diagnostic accuracy between departments ($P = 0.625$). There was a statistically significant difference between the departments for diagnostic and treatment approaches (P values respectively $P = 0.002$, $P < 0.001$). Plastic surgeons preferred to confirm their pre-diagnosis histopathologically more than dermatologists. Plastic surgeons recommended

surgical procedures for 25 lesions (96.2%) while dermatologists for 14 (53.8%) ones. Tele-dermoscopy increased the rate of diagnostic accuracy of dermatologists from 74.3% to 82.0% ($P = 0.02$).

Conclusions: Tele-dermatology is an effective method for non-melanocytic skin lesions with high diagnostic accuracy. Adding dermoscopy to tele-dermatology increases diagnostic accuracy of dermatologists on non-melanocytic skin lesions.

Introduction

Telemedicine (TM), defined as practicing medicine at a distance, has grown in popularity over the past ten years [1]. As social distancing becoming the new standard in the era of Coronavirus disease 2019 (COVID-19) pandemic, TM emerges as a key tool in medicine. It can be performed with live interaction technology via videoconferencing equipment or with store-and-forward methods via transmitting digital images or photographs of the lesions with patient clinical history [2,3].

TM has a particular value in specialties which have a strong visual aspect, such as dermatology and plastic and reconstructive surgery (PRS) [4]. TM applications among plastic surgeons was observed particularly in the management of various conditions such as acute trauma, burns, and postoperative monitoring [5-8]. Tele-dermatology (TD) has been used since 1995 as an example of TM [9]. TD is a useful alternative where specialized dermatological assistance is not available and has been used successfully to support health professionals worldwide, in either an asynchronous store-and-forward format or a real-time video conferencing format [10]. The majority of TD studies were related to skin cancers in the literature [11-14]. Dermoscopy is a non-invasive tool for originally developed for diagnosing and detecting skin cancer. It has been shown that dermoscopy can be used in the diagnosis of pigmented and non-pigmented skin lesions over time. Tele-dermoscopy (TDS) is a currently defined method that aims to increase diagnostic accuracy by adding dermoscopic images to TD [15]. Most of the research with TDS focuses on melanocytic skin lesions including melanoma and melanocytic nevus. There have been only a few reports with TD and TDS to diagnose non-melanocytic skin lesions (NMSLs) [2,11,15].

Face to face (FTF) comparisons of diagnostic accuracy and therapeutic approaches between dermatologists and plastic surgeons have controversial results [16-18]. To the best of our knowledge there is no study in English-language literature comparing the diagnostic accuracy and differences in treatment approach for NMSLs between dermatology and PRS departments by using TD.

Objectives

The aim of this study was to evaluate diagnostic accuracy rates and treatment approaches of dermatologists and plastic surgeons in NMSLs by using TM and the

contribution of the TDS method to the diagnostic accuracy of dermatologists.

Methods

Patients who applied to the dermatology unit of a tertiary oncology hospital in Turkey and were performed a diagnostic skin biopsy between April 2018 and March 2019 were included in the study. Patients who were under 18 years old, pregnant and not volunteers were not involved. Informed consent was taken from each patient and the protocol was approved by a local research and ethics review committee.

Lesions of the patients were examined and recorded by the same dermatologist (BT) who took clinical and dermoscopic pictures of the lesions by using her same mobile phone (iPhone 7s, Apple Inc) and dermoscopy device with connection kit (DermLite DL3N, 3Gen Inc). Lesions with clinical and dermatoscopic photographs which required histopathologic examination for differential diagnosis were included in the study. Histopathologic examination was accepted as gold standard for diagnostic accuracy in the present study. Age, gender, duration and localization of the lesions, clinical and histopathological diagnoses, clinical and dermoscopic images were recorded. The evaluation was performed using TD with SAF method. Clinical images and a brief clinical history were sent by email to 6 physicians, namely 3 plastic surgeons and 3 dermatologists. Each physician was 8 to 15 years experienced within his/her specialty. All dermatologists had completed a dermoscopy course before the study.

Physicians were asked to record their clinical diagnosis, which was then compared with the histopathological diagnosis. It was also questioned whether they need to confirm the diagnosis with histopathology and which treatment approaches such as excision, cryotherapy, electrotherapy or laser therapy would prefer. Excision was classified as a surgical procedure while other procedure were non-surgical ones. Plastic surgeons were asked if they request a dermatology consultation before treatment decision.

Accuracy was defined as the ability of a test to determine disease correctly by comparison with a reference/gold standard [11]. The accuracy of TD for diagnosis was established by comparison with histopathological examination. Physicians were asked to record their clinical diagnoses after the evaluation of the pictures and clinical information, and then clinical diagnoses were compared with the histological

diagnoses. TD diagnoses were accepted as correct if they were same with the histopathological diagnoses. The percentage of correct diagnosis was defined as the accuracy of TD. In order to determine the diagnostic accuracy between departments, at least two out of three physicians from the same department were required to make the correct diagnosis.

Dermatologists were asked if they requested to evaluate dermoscopic images of the lesions to confirm their clinical diagnosis made by TD. Regardless of the answer, to determine the effect of TDS on the diagnosis, dermatologists evaluated tele-dermoscopic images of all lesions after clinical images and were asked to make a diagnosis, too.

Statistical analyses were performed with the IBM SPSS for Windows Version 23.0. Numerical variables were summarized as mean \pm standard deviation or median (minimum-maximum). Categorical variables were given as frequencies and percentages. Categorical variables were compared by chi square or Fisher exact test. Diagnostic

accuracy of the physicians were compared by McNemar or Cochran Q test as appropriate. A P value less than 0.05 was considered as significant.

Results

The clinical characteristics of patients and duration, localization, and the histopathological diagnoses of lesions are summarized in Table 1. According to the diagnostic accuracy, there was no statistically significant difference within the physicians of the same department. The P value for dermatologists was 0.41 and for plastic surgeons was 0.07. The percentages of physicians diagnostic accuracy in the same department were demonstrated on Figure 1. The average percentage of diagnostic accuracy among dermatologists was 74.3% and among plastic surgeons was 61.5%. There was not statistically difference in diagnostic accuracy between departments ($P = 0.625$).

Table 1. Clinical characteristics of patients, features and histopathologic diagnoses of lesions

Clinical characteristics		N (%)
Age, years		
Median (min-max)	47 (18-83)	
Gender, N (%)		
Male	13 (50)	
Female	13 (50)	
Duration of lesions		
	Since childhood	3 (11.5)
	<1 month	3 (11.5)
	<1 year	5 (19)
	1-5 years	6 (23)
	>5 years	9 (35)
Localization of lesions		
	Scalp	13 (50)
	Face	1 (3.8)
	Upper extremity	4 (15.4)
	Lower extremity	1 (3.8)
	Torso	7 (27)
The histopathologic diagnoses		
	Seborrheic keratosis	3
	Verruca vulgaris	2
	Epidermal cyst	2
	Dermatofibroma	3
	Fibroma	3
	Sebaceous adenoma	1
	Bowen disease	1
	BCC	3
	SCC	3

Min = minimum; Max = maximum; BCC = basal cell carcinoma; SCC = squamous cell carcinoma

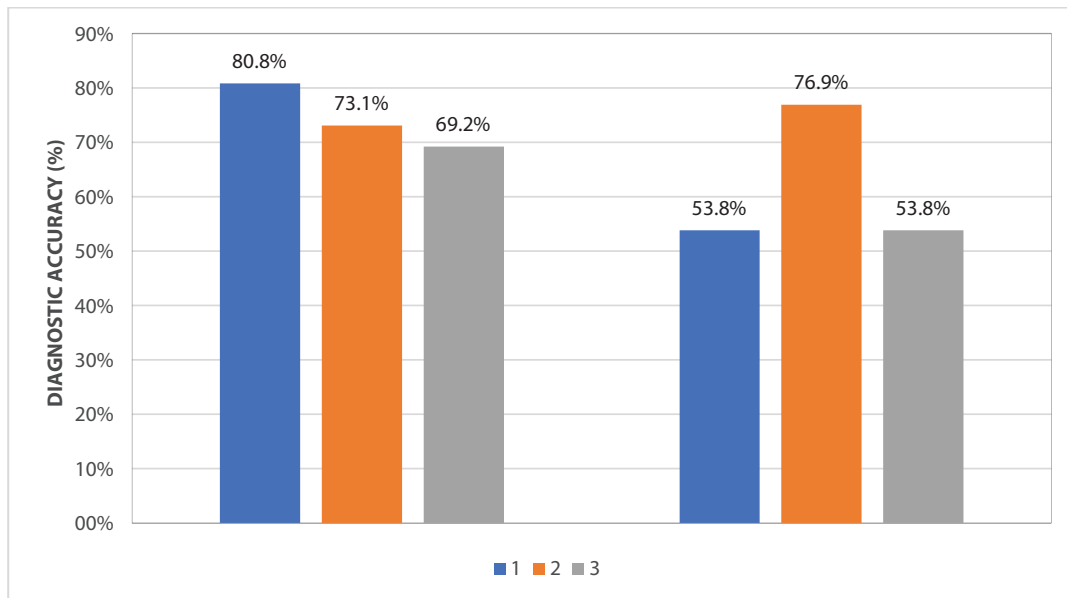


Figure 1. The frequencies of each dermatologist (the left columns) and plastic surgeon's (the right columns) diagnostic accuracy.

Dermatologists preferred surgical procedures for 14 (53.8%) lesions and nonsurgical procedures for 12 (46.2%) lesions. Plastic surgeons preferred nonsurgical procedures for one lesion (3.8%) whereas surgical procedures for 25 lesions (96.2%). There was a statistically significant difference between the departments for treatment approaches ($P < 0.001$) (Figure 2).

The need of dermoscopic images in addition to clinical pictures was an average of 80.7% of the lesions for dermatologists. Diagnostic accuracy of TDS was 82% for all lesions which were confirmed by histopathologically. TDS increased the rate of mean diagnostic accuracy of TD from 74,3% to 82% among dermatologists ($P = 0.02$) (Table 2).

Among plastic surgeons, the average percentage of requesting a dermatology consultation before treatment decision was 28.2% (Table 2).

Conclusions

In the current digital and locked-down world related to COVID-19 pandemic, TM helps physicians for diagnosis and management of the patients. The diagnostic accuracy and therapeutic approach to NMSLs by using TD was evaluated between dermatology and PRS departments in the current study. While there was no difference between the 2 departments in diagnostic accuracy, a significant difference was found in treatment approach in favor of the surgical approach among plastic surgeons.

Diagnostic reliability and accuracy of TM among dermatologists was found to vary from 47.7% to 88.0% in the literature [2,11,15,19,20]. Fabbrocini et al reported a correct diagnosis rate of 52.0% for dermatologists using TDS for difficult pink

lesions [2]. Similarly, in another study, the diagnostic rate of TD was found 59.0% for non-pigmented neoplasms [11]. Şenel et al reported that diagnostic accuracy of non-melanocytic skin tumors by TD was 85.0% and 88.0% for 2 different dermatologists [15]. Diagnostic agreement rates were reported to be between 47.7% to 87.3% for non-pigmented lesions by Warsaw et al [11], Giavina-Bianchi et al also studied diagnostic accuracy of TD for both pigmented and non-pigmented skin lesions. They reported accuracy rates of 75.0%, 71.0%, 64.0% and 50.0% for basal cell carcinoma, squamous cell carcinoma, cysts, and warts/seborrheic keratosis or lipomas, respectively [20].

Although there are studies which were performed with plastic surgeons about efficacy of TM in various conditions such as wound and burn management, trauma, free flap care, cleft lip/palate repair, there is not any report about diagnostic accuracy of NMSLs diagnosis with TM method [1]. FTF studies demonstrated that the overall diagnostic accuracy of skin lesions for plastic surgeons was around 60.0% to 89.0% [17,21-23]. Clinical diagnosis matched with the pathological diagnosis was considered as a correct diagnosis in these studies. Sönmez et al [17] reported correct diagnosis rate for PRS clinic as 61.4% and Matteucci et al [22] reported an overall diagnostic accuracy of malignant lesions of 83.0%. Basal cell carcinomas were diagnosed with the highest degree of accuracy with 89.0%, whereas squamous cell carcinomas were with a lower level of diagnostic accuracy with 33.0% [22]. The correct diagnostic rate for basal cell carcinoma was 68.0% in the study by Stone et al [21]. In Hallock study, overall diagnostic accuracy was 65% in 2000 excised skin tumors [23]. Our diagnostic accuracy rates for dermatologists and plastic surgeons in the diagnosis of NMSLs were compatible with previous studies.

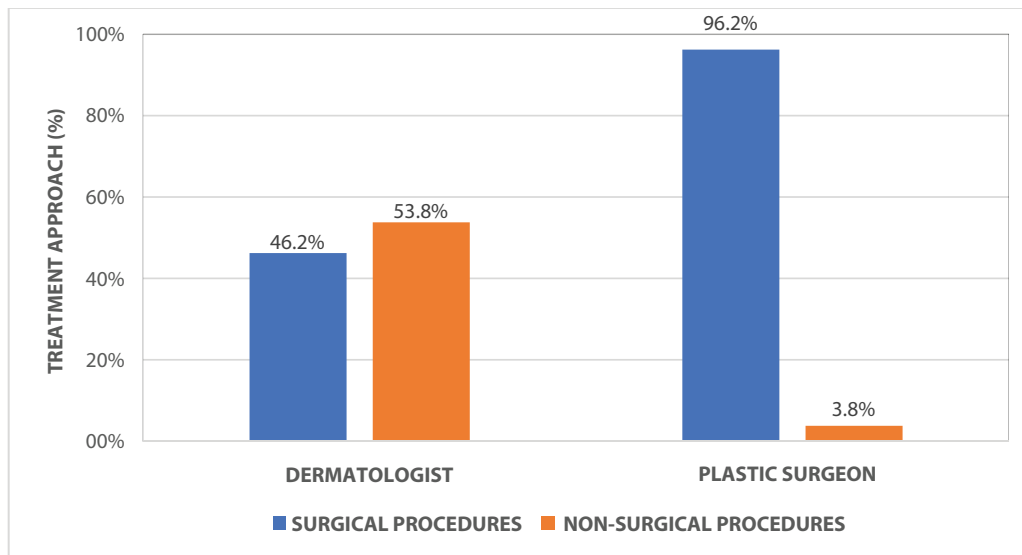


Figure 2. The frequencies of the treatment approaches of dermatologists and plastic surgeons ($p < 0.001$)

Table 2. The response rates of dermatologists and plastic surgeons

	D1 n/N (%)	D2 n/N (%)	D3 n/N (%)	Average %
In how many lesions did dermatologists request dermoscopic images to confirm their diagnosis?	24/26 (92.3)	26/26 (100)	13/26 (50)	80.7
In how many lesions was teledermoscopic pre-diagnosis histopathologically compatible? (Diagnostic accuracy of TDS)	23/26 (88.5)	21/26 (80.8)	20/26 (76.9)	82.0
	n/ND (%)	n/ND (%)	n/ND (%)	%
For how many lesions that required dermoscopic confirmation were also requested histopathological confirmation?	10/24 (41.7)	17/26 (65.4)	8/13 (61.5)	563
	P1 n (%)	P2 n (%)	P3 n (%)	Average %
Requesting dermatology consultation	2 (7.7)	11 (42.3)	9 (34.6)	28.2

D1 = Dermatologist-1; D2 = Dermatologist-2; D3 = Dermatologist-3; P1 = Plastic surgeon-1; P2 = Plastic surgeon-2; P3 = Plastic surgeon-3; N = Total number of lesions; ND = total number of lesions that required dermoscopic image; TDS = Tele-dermoscopy

Although there is no data comparing diagnostic accuracy for various skin lesions between dermatologists and plastic surgeons by using TM in the scientific literature, there are some reports with FTF methods [16-18,21]. Sellheyer and Bergfeld reported that dermatologists accurately diagnosed neoplastic and cystic skin lesions nearly 2 times more (75%) than non-dermatologist physicians (40%) or plastic surgeons (45%) [18]. Similarly, Stone et al reported higher positive predictive value for basal cell carcinoma (as one of malignant NMSLs) diagnosis of dermatologists (85%) than plastic surgeons (68%) [21]. In another study, similar diagnostic rates for basal cell carcinoma were reported among dermatologists and plastic surgeons which were higher than other physicians [16]. In a retrospective study by Sönmez

et al, which compared the diagnoses rates for various skin lesions for dermatology and PRS departments, overall correct diagnosis rate of biopsied skin lesions was 64.0% for the dermatology clinic and 61.4% for the PRS clinic and did not differ significantly between the 2 clinics [17]. Similar to the Sönmez et al study, the diagnostic accuracy rate did not differ between the 2 departments in the current study. Our findings suggest that the TM method has similar results to FTF in terms of comparing diagnostic accuracy for dermatology and PRS departments.

With the use of dermoscopy, correct clinical diagnosis especially for the pigmented lesions and benign neoplastic lesions increased in recent years [17]. The efficacy of contribution of dermoscopy to TD has been investigating recently.

A study evaluating 1000 lesions suggested that TD and TDS might be valid and reliable tools for the diagnosis of actinic keratosis [24]. Additionally, TDS was reported to be superior to FTF dermoscopy and to TD only for detecting early actinic keratoses [24]. Braun et al reported that diagnostic accuracy of NMSLs with TDS was higher than traditional dermoscopic approach with the exception of Kaposi sarcoma [25]. Senel et al reported that TD was a reliable technique for the diagnosis of nonmelanocytic skin tumors and TDS increased the reliability and the accuracy of TD. The accuracy of the diagnoses was significantly increased by the addition of dermoscopic images from 85% to 94% and from 88% to 95% for 2 different tele-dermatologists [15]. On the other hand, it is also reported that TDS had an advantage for only biopsied pigmented lesions [19]. Fabbrocini et al evaluated difficult pink lesions and reported lower correct diagnosis rate for TDS than FTF examination and they discussed that this result might be cause of the absence of typical criteria of pink lesions [2]. In the present study, dermatologists had agreed that TDS was helpful to confirm their clinical diagnoses in 80.7% of the images and TDS increased the mean diagnostic accuracy rate from 74.3% to 82.0% for dermatologists. TDS is known to improve diagnostic accuracy and to decrease the rate of unnecessary consultations in dermatology compared with TD alone. In a study about specialists-to-experts store-and-forward TDS, TDS improved diagnostic accuracy of pigmented skin lesions compared with solitary non-expert assessment [26]. Our findings suggest that dermoscopic examination is a frequently used method by dermatologists which increases their diagnostic accuracy on NMSLs diagnosis.

It is in the nature of the profession that surgeons are more prone to surgical approach for diagnosis or management of skin lesions [21,22]. However, some benign skin lesions could be managed non-surgically. Thus, treatment approach between departments was significantly different from each other in the present study, with surgeons more prone to surgical approaches. All these differences of treatment approaches can be related to differences in postgraduate specialization training, indeed.

With increasing technologic advancements, TM holds great potential to augment the dermatologist and plastic surgeon daily practice. Previous studies asserted that the clinical diagnostic accuracy had important outcomes for treatment selection and the prioritization of treatment [22]. Ferrandiz et al reported that teleconsultation before surgery could make an advantage for surgeon to plan the treatment procedure and surgical technique with high diagnostic accuracy rates [27]. Bilgili et al found that diagnostic accuracy was affected positively by a preoperative evaluation by a dermatologist [28]. Travato et al reported that e-consultation for selected plastic surgery patients was an accurate, cost-saving,

time-saving technique in the evaluation and management [19]. Matteucci et al emphasized the importance of specializing, especially in lesions with predicted as low malignancy risk [22]. Our results support the idea that e-consultation of the skin lesions to a dermatologist via TM may be an effective method to prevent unnecessary surgery for a plastic surgeon.

Our study had some limitations. There were no predetermined categories for clinical diagnosis of NMSLs and number of lesions was small. With higher number of physicians and different kinds of lesions, requirements of TD between clinics can be determined.

In conclusion, TM is an easy method for NMSLs diagnosis with up to 75% of diagnostic accuracy. Adding TDS to TD increases diagnostic accuracy for dermatologists on NMSLs diagnosis. The difference in treatment approach between departments can be reduced through the effective use of TD and TDS via e-consultation.

References

1. Vyas KS, Hambrick HR, Shakir A, et al. A systematic review of the use of telemedicine in plastic and reconstructive surgery and dermatology. *Ann Plast Surg.* 2017;78(6):736-768. DOI: 10.1097/SAP.0000000000001044. PMID: 28328635.
2. Fabbrocini G, Balato A, Rescigno O, Mariano M, Scalvenzi M, Brunetti B. Telediagnosis and face-to-face diagnosis reliability for melanocytic and non-melanocytic 'pink' lesions. *J Eur Acad Dermatol Venereol.* 2008;22(2):229-234. DOI: 10.1111/j.1468-3083.2007.02400.x PMID: 18211418
3. Trettel A, Eissing L and Augustin M. Telemedicine in dermatology: findings and experiences worldwide - a systematic literature review. *J Eur Acad Dermatol Venereol.* 2018;32(2):215-224. DOI: 10.1111/jdv.14341. PMID: 28516492.
4. Gardiner S and Hartzell TL. Telemedicine and plastic surgery: a review of its applications, limitations and legal pitfalls. *J Plast Reconstr Aesthet Surg.* 2012;65(3) e47-e53. DOI: 10.1016/j.bjps.2011.11.048. PMID: 22178033.
5. Fonseca AS, Goldenberg DC, Stocchero GF, Luiz AV, Gemperli R. Validation of videoconference with smartphones in telemedicine facial trauma care: analysis of concordance to on-site evaluation. *Ann Plast Surg.* 2016;77(4):433-437. DOI: 10.1097/SAP.0000000000000623. PMID: 26418788.
6. Holt B, Faraklas I, Theurer L, Cochran A, Saffle JR.. Telemedicine use among burn centers in the United States: a survey. *J Burn Care Res.* 2012;33(1):157-162. DOI: 10.1097/BCR.0b013e31823d0b68. PMID: 22105096.
7. Syed-Abdul S, Scholl J, Chen CC, Santos MD, Jian WS, Liou DM, Li YC. Telemedicine utilization to support the management of the burns treatment involving patient pathways in both developed and developing countries: a case study. *J Burn Care Res.* 2012;33(4):e207-e212. DOI: 10.1097/BCR.0b013e318241b6b7. PMID: 22249104.
8. Hee Hwang J and Mun GH. An evolution of communication in postoperative free flap monitoring: using a smartphone and mobile messenger application. *Plast Reconstr Surg.* 2012;130(1):125-129. DOI: 10.1097/PRS.0b013e318254b202. PMID: 22743879.

9. Perednia DA and Brown NA. Teledermatology: one application of telemedicine. *Bull Med Libr Assoc.* 1995;83(1):42-47. PMID: 7703938. PMCID: PMC225996.
10. Lee KJ, Finnane A, Soyer HP. Recent trends in teledermatology and teledermoscopy. *Dermatol Pract Concept.* 2018;8(3):214-223. DOI:10.5826/dpc.0803a13. PMID: 30116667.
11. Warshaw EM, Lederle FA, Grill JP, et al. Accuracy of teledermatology for nonpigmented neoplasms. *J Am Acad Dermatol.* 2009;60(4):579-588. DOI: 10.1016/j.jaad.2008.11.892. PMID: 19217689.
12. Whited JD, Mills BJ, Hall RP, Drugge RJ, Grichnik JM, Simel DL. A pilot trial of digital imaging in skin cancer. *J Telemed Telecare.* 1998;4(2):108-112. DOI: 10.1258/1357633981932046. PMID: 9744167.
13. Whited JD, Hall RP, Simel DL, et al. Reliability and accuracy of dermatologists' clinic based and digital image consultations. *J Am Acad Dermatol.* 1999;41(5 Pt 1):693-702. DOI: 10.1016/s0190-9622(99)70003-4. PMID: 10534630.
14. Barnard CM and Goldyne ME. Evaluation of an asynchronous teleconsultation system for diagnosis of skin cancer and other skin diseases. *Telemed J E Health.* 2000;6(4):379-384. DOI: 10.1089/15305620050503843. PMID: 11242545.
15. Şenel E, Baba M and Durdu M. The contribution of teledermatoscopy to the diagnosis and management of non-melanocytic skin tumours. *J Telemed Telecare.* 2013;19(1):60-63. DOI: 10.1177/1357633X12474961. PMID: 23422158.
16. Mohammad EA, Mansour M, Parichehr K, Farideh D, Amirhossein R, Ahmad SA. Assessment of clinical diagnostic accuracy compared with pathological diagnosis of basal cell carcinoma. *Indian Dermatol Online J.* 2015;6(4):258-262. DOI: 10.4103/2229-5178.160257. PMID: 26225330. PMCID: PMC4513405.
17. Sönmez A, Şatır T, Sav A. Diagnostic accuracy of biopsied skin lesions in dermatology and plastic surgery clinics. *Eur J Plast Surg.* 2007;29:313-316. DOI: 10.1007/s00238-007-0108-z.
18. Sellheyer K and Bergfeld WF. A retrospective biopsy study of the clinical diagnostic accuracy of common skin diseases by different specialties compared with dermatology. *J Am Acad Dermatol.* 2005;52(5):823-830. DOI: 10.1016/j.jaad.2004.11.072. PMID: 15858472.
19. Trovato MJ, Scholer AJ, Vallejo E, Buncke GM, Granick MS.. eConsultation in plastic and reconstructive surgery. *Eplasty.* 2011;11:e48. PMID: 22140594. PMCID: PMC3228577.
20. Giavina-Bianchi M, Azevedo MFD, Sousa R, Cordioli E.. Part II: Accuracy of teledermatology in skin neoplasms. *Front Med (Lausanne).* 2020;7:598903. DOI: 10.3389/fmed.2020.598903. PMID: 33330564.
21. Stone CA and Downs AMR. Diagnostic accuracy of skin lesions amongst plastic surgeons and a dermatologist. *J Eur Acad Dermatol Venereol.* 2017;31(12):e533-e534. DOI: 10.1111/jdv.14398. PMID: 28609605.
22. Matteucci P, Pinder R, Magdum A, Stanley P. Accuracy in skin lesion diagnosis and the exclusion of malignancy. *J Plast Reconstr Aesthet Surg.* 2011;64(11):1460-1465. DOI: 10.1016/j.bjps.2011.06.017. PMID: 21741335.
23. Hallock GG and Lutz DA. Prospective study of the accuracy of the surgeon's diagnosis in 2000 excised skin tumors. *Plast Reconstr Surg.* 1998;101(5):1255-1261. DOI: 10.1097/00006534-199804050-00014. PMID: 9529210.
24. Sola-Ortigosa J, Muñoz-Santos C, Masat-Ticó T, sidro-Ortega J, Guilabert A; Grup d'Estudi de Teledermatologia del Vallès Oriental.. The role of teledermatology and teledermoscopy in the diagnosis of actinic keratosis and field cancerization. *J Invest Dermatol.* 2020;140(10): 1976-1984. DOI: 10.1016/j.jid.2020.02.013. PMID: 32142799.
25. Braun RP, Meier ML, Pelloni F, et al. Teledermatoscopy in Switzerland: A preliminary evaluation. *J Am Acad Dermatol.* 2000;42(5 Pt 1):770-775. DOI: 10.1067/mjd.2000.103977. PMID: 10775852.
26. Marchetti A, Dalle S, Maucourt-Boulch D, et al. Diagnostic concordance in tertiary (dermatologists-to-experts) teledermoscopy: a final diagnosis-based study on 290 cases. *Dermatol Pract Concept.* 2020;10(3):e2020071. DOI: 10.5826/dpc.1003a71. PMID: 32642316.
27. Ferrandiz L, Moreno-Ramirez D, Nieto-Garcia, et al. Teledermatology-based presurgical management for nonmelanoma skin cancer: a pilot study. *Dermatol Surg.* 2007;33(9):1092-1098. DOI: 10.1111/j.1524-4725.2007.33223.x. PMID: 17760600.
28. Bilgili ME, Yildiz H, Cengiz BP, Saydam IM. Effect of preoperative evaluation by a dermatologist on diagnostic accuracy. *Dermatol Surg.* 2014;40(12):1402-1408. DOI: 10.1097/DSS.000000000000168. PMID: 25350124.