

Vesiculobullous Erythema Elevatum Diutinum: a Rare Variant With Epidermolysis Bullosa Acquisita-like Immunofluorescence Findings

Basak Yalici-Armagan¹, Deniz Ates-Ozdemir², Gökçe Yeter², Nilgun Atakan³

¹ Department of Dermatology and Venereology, Hacettepe University, Faculty of Medicine, Ankara, Turkey

² Department of Pathology, Hacettepe University, Faculty of Medicine, Ankara, Turkey

³ Dermatology and Venereology, Private Clinic, Ankara, Turkey

Key words: Direct immunofluorescence, Epidermolysis bullosa acquisita, Erythema elevatum diutinum, Salt-split skin test

Citation: Yalici-Armagan B, Ates-Ozdemir D, Yeter G, Atakan N. Vesiculobullous Erythema Elevatum Diutinum: A Rare Variant with Epidermolysis Bullosa Acquisita-like Immunofluorescence Findings. *Dermatol Pract Concept*. 2022;12(2):e2022077. DOI: <https://doi.org/10.5826/dpc.1202a77>

Accepted: October 4, 2021; **Published:** April 2022

Copyright: ©2022 Yalici-Armagan et al. This is an open-access article distributed under the terms of the Creative Commons Attribution-NonCommercial License (BY-NC-4.0), <https://creativecommons.org/licenses/by-nc/4.0/>, which permits unrestricted noncommercial use, distribution, and reproduction in any medium, provided the original authors and source are credited.

Funding: None.

Competing interests: None.

Authorship: All authors have contributed significantly to this publication.

Corresponding author: Basak Yalici-Armagan, MD, Department of Dermatology and Venereology, Hacettepe University, Faculty of Medicine, Ankara, Turkey. E-mail: basakarmagan@gmail.com

Introduction

Erythema elevatum diutinum (EED) is a rare, chronic dermatosis characterized by red-violet to red-brown papules, plaques, and nodules that favor extensor surfaces. Vesiculobullous variant is a rare form of EED [1]. Herein, we present a case of vesiculobullous EED with epidermolysis bullosa acquisita (EBA)-like with direct immunofluorescence (DIF) findings.

Case Presentation

A 65-year-old man presented with progressively increasing nodules on feet for 5 years, pruritic papules on knees and elbows for 1 year (Figure 1, A-E) and blisters on hands for 1 month. Dermatological examination revealed violaceous nodules on feet, erythematous flat-topped papules on elbows and knees with multiple tense blisters on palmar and

dorsal region of hands. Hematoxylin and eosin staining from 2 punch biopsies of the foot and knee showed nodular and diffuse inflammation rich in neutrophils under uninvolved epidermis (Figure 2A). Small vessels are damaged by neutrophil rich inflammation and leukocytoclastic debris, resulting in leukocytoclastic vasculitis (LCV) (Figure 2B) and storiform fibrosis at the dermis are consistent with EED. The biopsy of the hand dorsum demonstrated subepidermal separation with perivascular and interstitial inflammation rich in eosinophils with fibrin accumulation in the dermis (Figure 2, C and D). DIF from perilesional skin of the hand revealed linear deposition of immunoglobulins (IgG, IgA, IgM) and complement (C3) along the basal membrane zone (BMZ). Location of deposits were on the floor of the blister in salt-split skin test with IgG (Figure 2E). Full blood count showed iron deficiency anemia. Serology tests for HIV and hepatitis-B and C were negative. Dapsone was initiated 50 mg twice daily. At 5 weeks follow-up, a significant improvement

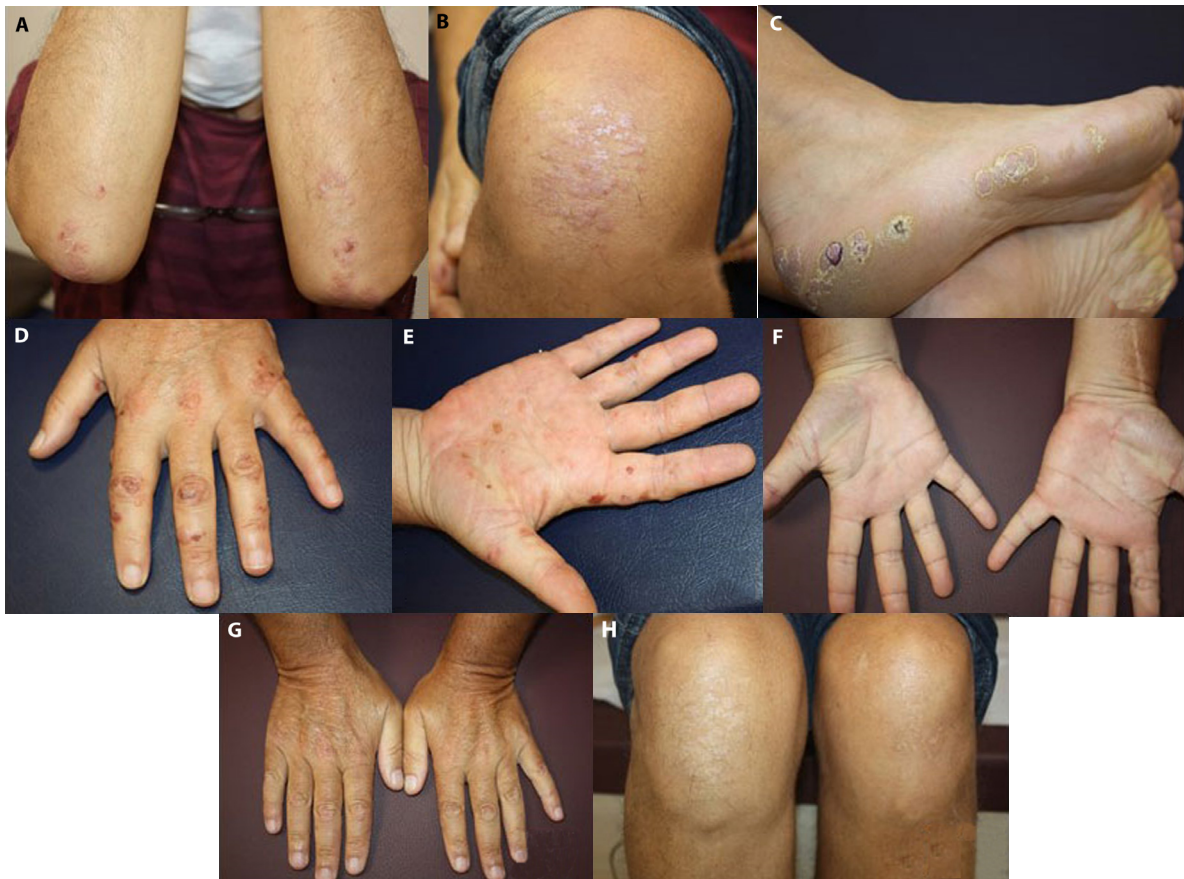

Figure 1. (A-E) Multiple tense blisters on palmar and dorsal region of hands (A,B); erythematous flat-topped papules on elbows and knees (C,D) and violaceous nodules on feet (E), improving of the vesiculobullous and papular lesions located on the hands (F,G) and knees (H).

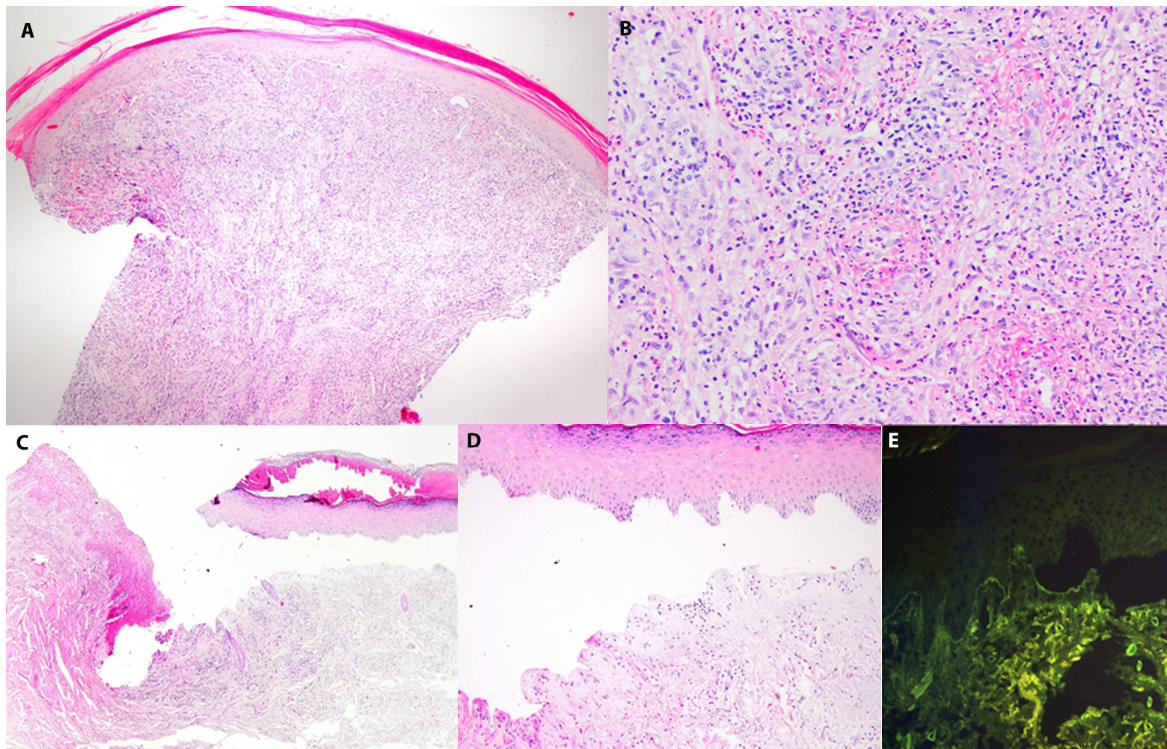


Figure 2. (A-E) Diffuse dense inflammation composed of predominantly neutrophils and dermal fibrosis are observed under uninvolved epidermis. (A) Fibrin deposition is present around dermal vessels (H&E, 40x magnification). (B) Endothelial swelling, leukocytoclastic debris and fibrin deposition are visible in dermal vessels (H&E, 200x magnification). (C) Subepidermal separation is seen with fibrin deposition and mild to moderate perivascular and interstitial dermal inflammation (H&E, 40x magnification). (D) Subepidermal separation and mild to moderate inflammation are present with eosinophils (H&E, 200x magnification). (E) Linear IgG deposition is observed at the base of the split cavity (direct immunofluorescence with Ig G in salt split skin, 200x magnification).

was observed in hands, knees and elbows (Figure 1, F-H), whereas there was a partial improvement in feet.

Discussion

EED is a rare skin disorder that is associated with a variety of systemic diseases. Histopathologically, it is characterized by early changes of LCV with an infiltrate of polymorphonuclear cells, occasionally eosinophils and deposition of fibrin which resolves with fibrosis. The association of EED and autoimmune bullous diseases, such as dermatitis herpetiformis (DH) has been described previously [2]. Recently, it is argued that these cases may be more compatible with vesiculobullous EED than with DH. Although, perivascular deposition of IgG, IgA, IgM, complement, and fibrin has been demonstrated in DIF examination of EED; granular IgA deposits with a pseudolinear pattern at BMZ was reported in a single case of vesiculobullous EED [1]. To our knowledge, this is the first case of vesiculobullous EED with linear IgA, IgG, IgM and C3 deposition in BMZ. The presence of the deposits in the base of the bulla in salt-split skin test was also a remarkable finding in the current case which could be a pitfall for EBA in the differential diagnosis. Histopathological findings of EBA include subepidermal blister formation

with none or little inflammation depending on the clinical subtype. While dapsone is an effective treatment option for EED, EBA is usually refractory to many systemic agents including dapsone.

Conclusions

Dermal inflammation with eosinophils and fibrin deposition in histopathologic examination and dramatic response to dapsone therapy suggested the diagnosis of vesiculobullous EED rather than EBA in the current case. The present novel DIF and salt-split skin test findings expand the clinicopathological spectrum of vesiculobullous EED.

References

1. Ossorio-García L, Jiménez-Gallo D, Arjona-Aguilera C, Salamanca-Sánchez M, Linares-Barrios M. Vesiculobullous variant of erythema elevatum diutinum. *Clin Exp Dermatol.* 2017;42(7):777-780. DOI: 10.1111/ced.13166.. PMID: 28639709.
2. Aftab MN, Dee A, Helm TN. Erythema elevatum diutinum arising in the setting of dermatitis herpetiformis. *Cutis.* 2006;78(2):129-132. PMID: 16983903.