

Clinical, Dermoscopic and Radiological Features of Heel Stick Calcinosis Cutis

Keshavmurthy A. Adya¹, Arun C. Inamadar¹

¹ Department of Dermatology, Venereology and Leprosy, Shri B M Patil Medical College Hospital and Research Centre, BLDE (Deemed to be University), Karnataka, India

Key words: calcinosis cutis, dystrophic calcification, dermoscopy, heel-stick injury

Citation: Adya KA, Inamadar AC. Clinical, dermoscopic and radiological features of heel stick calcinosis cutis. *Dermatol Pract Concept.* 2022;12(3):e2022108. DOI: <https://doi.org/10.5826/dpc.1203a108>

Accepted: November 8, 2021; **Published:** July 2022

Copyright: ©2022 Adya et al. This is an open-access article distributed under the terms of the Creative Commons Attribution License (BY-NC-4.0), <https://creativecommons.org/licenses/by-nc/4.0/> which permits unrestricted noncommercial use, distribution, and reproduction in any medium, provided the original authors and source are credited.

Funding: None.

Competing interests: None.

Authorship: All authors have contributed significantly to this publication.

Corresponding author: Arun C. Inamadar MD, Department of Dermatology, Venereology and Leprosy, Shri B M Patil Medical College Hospital and Research Centre, BLDE (Deemed to be University), Vijayapur 586101, Karnataka, India, E-mail: aruninamadar@gmail.com

Introduction

Heel-stick calcinosis is a common disorder of infants due to heel prick injury. Although the condition is benign and self-resolving, it may cause anxiety and concern to the parents. Dermoscopy allows non-invasive confirmation of the diagnosis and differentiates other disorders with similar morphology thus helping in reassuring the parents.

Case report

An 8-month-old male was brought to us with multiple whitish lesions on the soles of both the feet since the past 4 months. On enquiry, parents revealed multiple heel pricks done for blood tests in the past. Examination revealed multiple discrete porcelain-white papules and carateriform keratotic papules (Figure 1A). Polarized dermoscopy using handyscope (FotoFinder® systems GmbH) revealed 2 types of lesions - homogenous circumscribed white clods and keratotic lesions showing central amorphous yellow and white clods surrounded by thick concentric scales (Figure 1B). A diagnosis of calcinosis cutis secondary to heel stick injury

was made. Plain X-ray revealed multiple white opacities within the soft tissues of the heels (Figure 1C). One of the lesions was punctured and chalky white material was expressed out which was dissolved by hydrochloric acid suggesting that it was calcium hydroxyapatite (Figure 2, A-C). Laboratory tests for calcium, phosphorous and vitamin D were all normal. A final diagnosis of dystrophic calcinosis cutis following heel-stick injury was hence established. As the condition is self-limiting, the parents were reassured about the same.

Conclusions

Heel-stick calcinosis is a form of dystrophic calcification following heel pricks. Multiple pricks account for majority of the cases although cases following single prick have also been described. Release of alkaline phosphate by injured tissue elevates the local pH favoring calcium deposition. The lesions can be solitary, or multiple discrete yellow-white papules or nodules and keratotic lesions which may be seen extruding through the epidermis. The lesions usually regress within about 2-3 years of age [1].

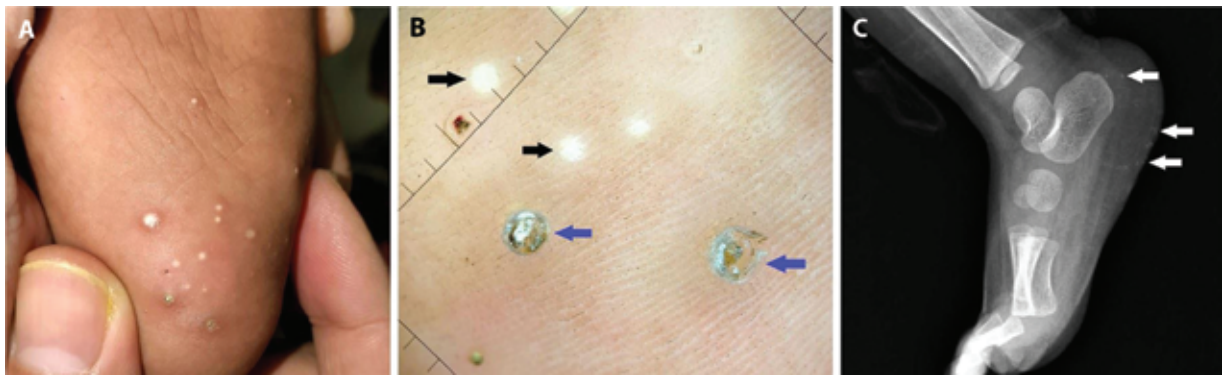


Figure 1. Dermoscopy: polarized, x20. (A) Multiple discrete white and keratotic papules on the heels. (B) Dermoscopy shows well-defined homogenous white dots (black arrows) and keratotic lesions with central yellow and white amorphous clods surrounded by concentric thick scales (blue arrows). (C) Plain X-ray shows circumscribed opaque densities along the margins of the heel




Figure 2. (A) Chalky-white material expressed out of a papule. (B) Material as observed under light microscope. (C) Complete dissolution of the material was seen on treatment with hydrochloric acid.

Dermoscopy of calcinosis cutis exhibits homogenous white areas as described above. The dermoscopy of keratotic lesions as described above highlights the process of trans-epidermal elimination of calcium deposits. Warts, callosities and corns can present as keratotic papules on the soles. Dermoscopically they show compact keratin, and the warts in addition show red or black dots surrounded by white halo. These lesions are rare in infants and do not show white homogenous material. Porokeratotic eccrine ostial and dermal duct nevus (PEODDN) presents with keratotic papules with collarette typically involving palms and soles and presenting at birth or in early childhood. The lesions are grouped and frequently along the Blaschko lines. Dermoscopy of PEODDN on palmar skin showing keratin filled pits has been described [2]. Hence, discrete lesions and presence of amorphous white substance centrally differentiates heel-stick calcinosis from PEODDN. Finally, milia-like calcinosis cutis exhibits similar dermoscopic features as

described above. It is mostly associated with Down syndrome characterized by discrete white papules involving hands and feet.

Although a fairly well-known entity and the diagnosis essentially clinical, application of dermoscopy in the diagnosis of heel stick calcinosis provides further support and refutes the need for biopsy and/or radiological imaging.

References

1. Braham SJ, Gilliam AE. Picture of the month: calcified nodule secondary to heel sticks. *Arch Pediatr Adolesc Med.* 2006;160(6):645. DOI: 10.1001/archpedi.160.6.645-a. PMID: 16754828.
2. Gupta AK, Agrawal A, Rambhiya K, Makhecha M. Generalized unilateral porokeratotic eccrine ostial and dermal duct nevus along the lines of blaschko: A rare entit. *Indian J Dermatopathol Diagn Dermatol.* 2019; 6:51-52. DOI: 10.4103/ijdpdd.ijdpdd_47_18.