

# Eosinophilic dermatosis of hematologic malignancy mimicking varicella zoster infection: report in a woman with chronic lymphocytic leukemia and review of the literature

Omar Bari<sup>1</sup>, Philip R. Cohen<sup>2</sup>

1 University of California San Diego School of Medicine, La Jolla, CA, USA

2 Department of Dermatology, University of California San Diego, La Jolla, CA, USA

**Key words:** chronic, dermatosis, eosinophilic, hematologic, infection, leukemia, lymphocytic, malignancy, varicella, zoster

**Citation:** Bari O, Cohen PR. Eosinophilic dermatosis of hematologic malignancy mimicking varicella zoster infection: report in a woman with chronic lymphocytic leukemia and review of the literature. *Dermatol Pract Concept* 2017;7(3):2. DOI: <https://doi.org/10.5826/dpc.0703a02>

**Received:** December 1, 2016; **Accepted:** April 29, 2017; **Published:** July 31, 2017

**Copyright:** ©2017 Bari et al. This is an open-access article distributed under the terms of the Creative Commons Attribution License, which permits unrestricted use, distribution, and reproduction in any medium, provided the original author and source are credited.

**Funding:** None.

**Competing interests:** The authors have no conflicts of interest to disclose.

All authors have contributed significantly to this publication.

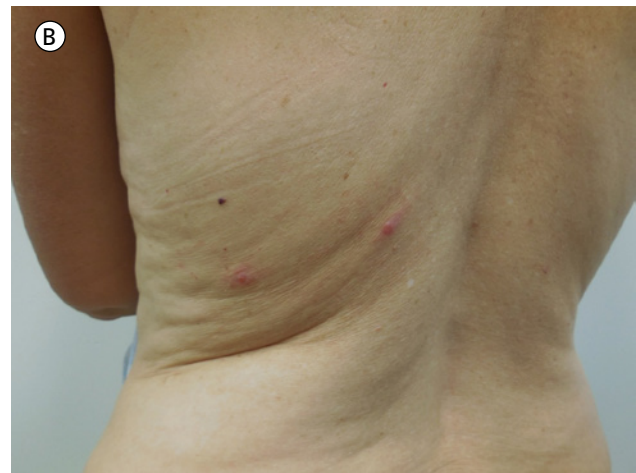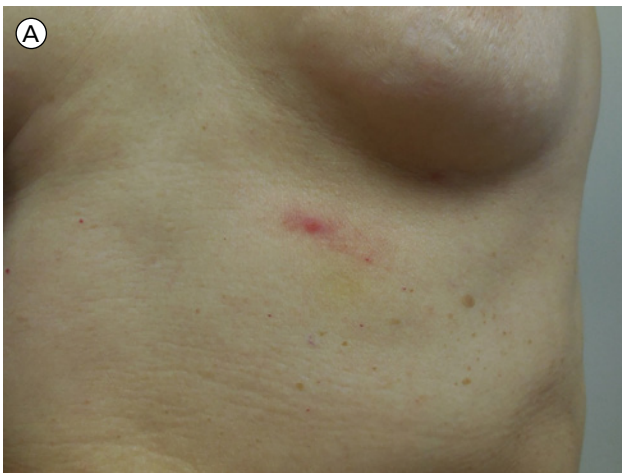**Corresponding author:** Philip R. Cohen, MD, Department of Dermatology, University of California San Diego, La Jolla, CA, USA. Email: [mitehead@gmail.com](mailto:mitehead@gmail.com)

**ABSTRACT** Eosinophilic dermatosis of hematologic malignancy is a rare papulovesicular eruption that presents in patients with hematoproliferative disorders, particularly chronic lymphocytic leukemia. A 59-year-old woman with chronic lymphocytic leukemia who developed eosinophilic dermatosis of hematologic malignancy mimicking varicella zoster infection is described. PubMed database was searched with the key words: chronic, dermatosis, eosinophilic, hematologic, infection, leukemia, lymphocytic, malignancy, varicella, zoster. The papers generated by the search and their references were reviewed. The patient presented, on more than 20 occasions, with a dermatomal vesicular eruption. Her oncologist, based on the clinical presentation, treated each episode as recurrent varicella zoster virus infection. A complete workup of the patient not only demonstrated negative viral studies but also revealed pathologic changes consistent with eosinophilic dermatosis of hematologic malignancy on lesional skin biopsy. The recurrence of the patient's dermatosis was less frequent when her malignancy was under better control. Eosinophilic dermatosis of hematologic malignancy may mimic other reactive dermatoses. The morphology of our patient's recurrent dermatosis resembled varicella zoster virus infection. Disseminated zoster virus infection with dermatomal and non-dermatomal distribution should be added to the clinical differential diagnosis of eosinophilic dermatosis of hematologic malignancy.

## Introduction

Eosinophilic dermatosis of hematologic malignancy was first reported in 1965 and thought to be a hypersensitivity reaction

to insect bites in patients with chronic lymphocytic leukemia (CLL) [1]. Subsequent reports noted that most patients failed to recall insect bites; thus, the term "insect bite-like reaction" was established [2]. Byrd et al. later dubbed the process



**Figure 1.** Distant views of vesicles on an erythematous base corresponding to the left T6 dermatome presenting below the breast (A), and extending to involve the upper abdomen and mid-back (B). [Copyright: ©2017 Bari et al.]

eosinophilic dermatosis of myeloproliferative disease [3], though Farber et al. favor the term eosinophilic dermatosis of hematologic malignancy to better encompass the numerous hematologic malignancies associated with this cutaneous eruption [4,5]. We describe a woman with CLL whose lesions resembled varicella zoster virus infection and review the literature on eosinophilic dermatosis of hematologic malignancy.

## Case Report

A 59-year-old woman with CLL presented for evaluation of vesicular eruptions thought to be recurrent varicella zoster virus infection. She was diagnosed with CLL in 2003 but experienced several recurrences of her leukemia. Shortly after the first recurrence of CLL in 2009, she developed skin lesions that appeared in a dermatomal distribution on her back. These lesions reappeared several times, and her oncologist treated her for presumptive herpes zoster virus infection with an appropriate dosage of acyclovir on more than 20 occasions. The patient had no definitive prior history of herpes zoster virus infection; varicella zoster virus infection had never been objectively confirmed with biopsy, viral culture, or PCR amplification. However, the patient did have several complete blood counts drawn. Eosinophil percentages ranged from 1-10%, though most frequently were 4-5% (normal range 0-7%); however, absolute eosinophil count never exceeded 500 cells per ml (normal range 0-500 cells per ml). Serum IgE level was assessed and found to be 2 International Units (IU) per ml (normal range 0-99 IU/ml). Her CLL therapy initially included fludarabine, cyclophosphamide, and rituximab but later included alemtuzumab, lenalidomide, venetoclax, and obinutuzumab.

She presented to the dermatologist for evaluation of a new onset of her skin lesions; these were similar to those that her oncologist had previously treated as varicella zoster virus

infection outbreaks. Cutaneous examination showed dermatomal (Figure 1) and non-dermatomal (Figure 2) lesions with similar morphology on her back and flanks. Vesicles ranging from 2 mm to 5 mm, within areas of erythema, were present. Initial evaluation included viral cultures for herpes simplex virus and varicella zoster virus; vesicular fluid was sent for direct fluorescent antibody to these viruses. In addition, biopsies were performed for both routine staining and direct immunofluorescence to rule out autoimmune bullous diseases.

The viral cultures and direct fluorescent antibody studies were negative. Microscopic examination of the skin biopsy showed an intraepidermal vesicle with eosinophils, eosinophilic spongiosis, and an accompanying diffuse and dense perivascular and periadnexal lymphocytic infiltrate with numerous eosinophils (Figure 3). Direct immunofluorescence and enzyme-linked immunosorbent assay (ELISA) studies were negative for bullous pemphigoid antigen-1 and bullous pemphigoid antigen-2.

Correlation of the clinical history, morphology, pathologic changes, and laboratory studies established the diagnosis of eosinophilic dermatosis of hematologic malignancy. Initial management included twice daily application of betamethasone dipropionate 0.05% cream, which provided relief and eventual resolution of the lesions. Two weeks later, the patient had recurrence of her lesions (Figure 4) and another skin biopsy showed similar pathologic changes. The patient was receiving investigational systemic therapy for her CLL; oral and other systemic therapies were prohibited. She continued her topical treatment.

The frequency of relapsing skin lesions was markedly reduced during periods in which the patient's hematologic malignancy was under better control. Recently, she had an exacerbation of her CLL and antineoplastic therapy was altered. Subsequently, she has had less frequent flares of her dermatosis after being placed on obinutuzumab.

## Discussion

Patients with CLL usually present with eosinophilic dermatosis of hematologic malignancy between 40 to 60 years of age [4]. Table 1 offers a review of this condition [1-25]. The eruption often occurs concurrently with or months to years after the diagnosis of the associated hematologic malignancy. However, the condition has also been reported to present prior to the cancer diagnosis [4].

Eosinophilic dermatosis of hematologic malignancy occurs most often with CLL. It has also been associated with acute lymphoblastic leukemia, acute monocytic leukemia, large cell lymphoma, mantle cell lymphoma, multiple myeloma, and myelofibrosis [4,6,7].

Eosinophilic dermatosis of hematologic malignancy has a polymorphic presentation. The condition may manifest as erythema, papules, nodules, urticaria, or vesicles [4,9]. The eruption is usually indurated and erythematous but can also be tender [4]. The clinical differential diagnosis includes arthropod assault, dermatitis herpetiformis, drug reaction, eosinophilic cellulitis, eosinophilic folliculitis, infection, leukemia cutis, papular urticaria, scabies, and urticarial stage of bullous pemphigoid [4,9].

Histologically, this condition displays a superficial and deep dense perivascular infiltrate of lymphocytes and eosinophils [2,4]. Vesicles or bullae may also present due to intraepidermal or subepidermal edema [4]. Flame figures in the dermis have also been reported [5].

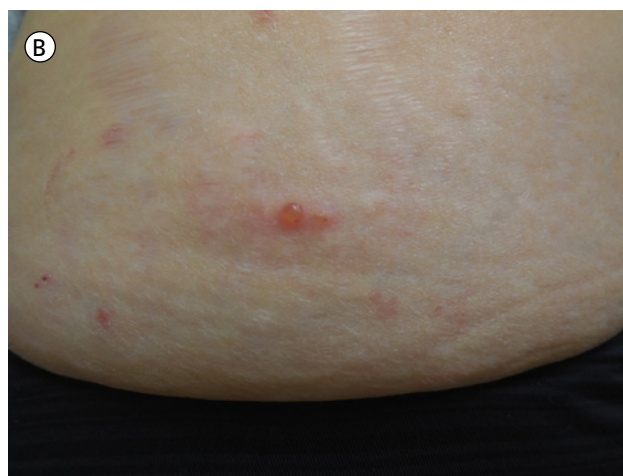
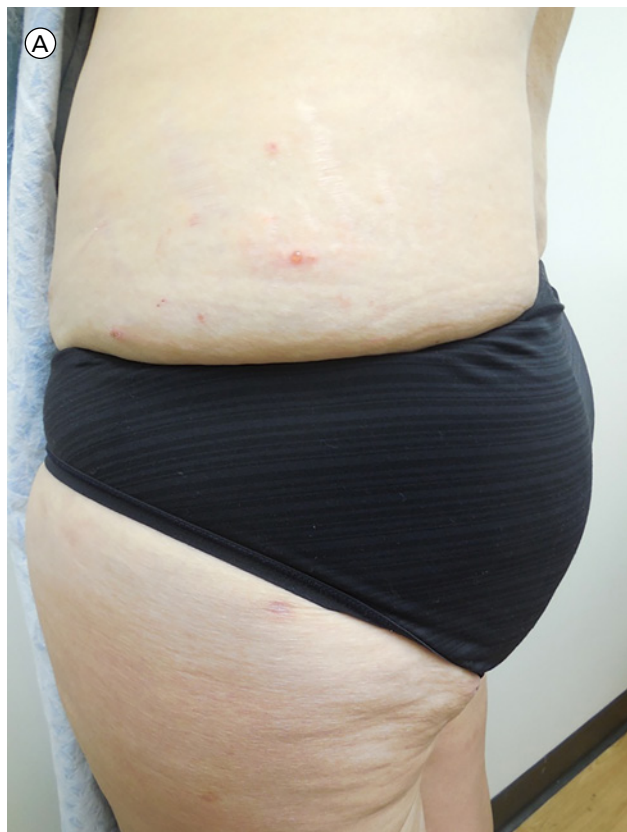
The pathogenesis of this condition is poorly understood [4]. It has been hypothesized that there is an excess of interleukin-4 and interleukin-5; this imbalance may lead to a proliferation of neoplastic B cells, which have been considered a major driver of the eruption [3,4,9]. This hypothesis is supported by the fact that interleukin-5 is the major eosinophil-recruiting cytokine [4]. Alternatively, it has been thought that neoplastic B cells drive a hypersensitivity reaction [3].

Several therapeutic options to treat eosinophilic dermatosis of hematologic malignancy have been reported. They include antibiotics, antihistamines, chemotherapy, dapsone, interferon alpha, intravenous immunoglobulin, phototherapy, and radiation [2,4,10]. Though some patients report favorable responses to therapy, overall the results have been disappointing [4]. The poor response underscores the lack of clarity of this condition's pathogenesis [4].

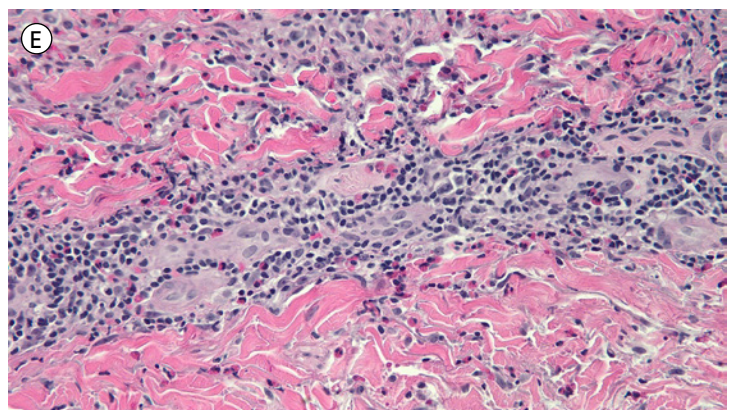
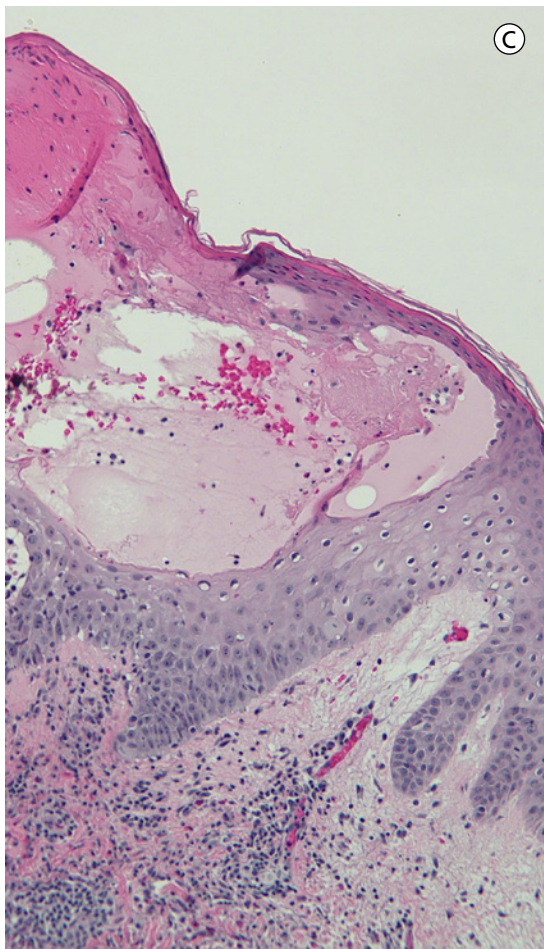
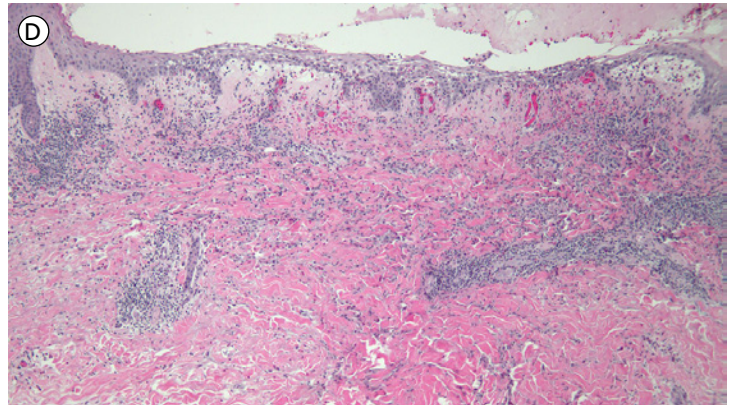
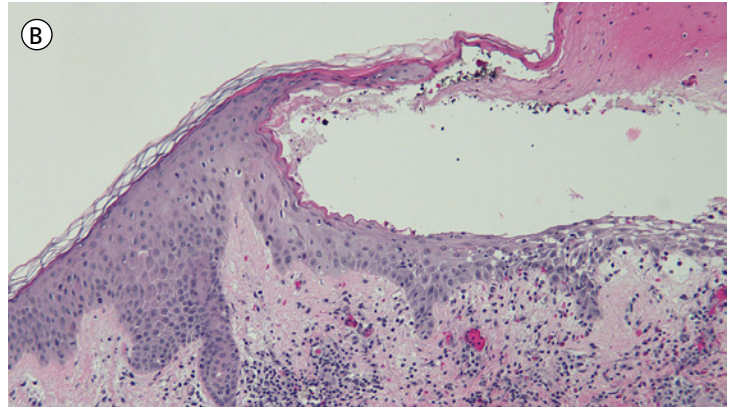
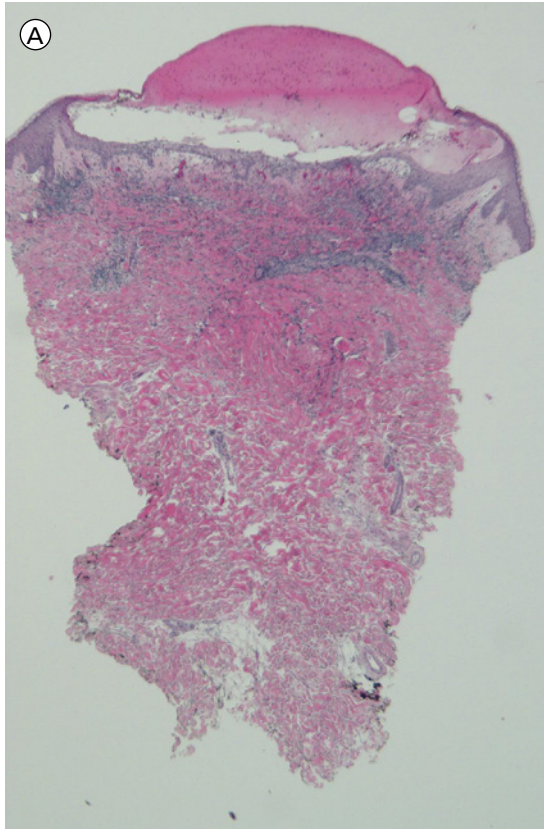
In regards to prognosis, eosinophilic dermatosis of hematologic malignancy may be associated with an aggressive course of CLL [4]; our patient lends support to this observation, given her repeat recurrences of CLL. Reported complications in patients with CLL and eosinophilic dermatosis of hematologic malignancy include Richter transformation and malignant clone expansion [2,10]. An underlying state of immunosuppression is postulated as the cause for these occurrences.

## Conclusion

Our patient's recurrent skin lesions of eosinophilic dermatosis of hematologic malignancy were clinically interpreted by her oncologist to be varicella zoster virus infection because they were frequently dermatomal. However, the likelihood of over 20 episodes of herpes zoster would be unique and unexpected; hence, we were prompted to evaluate her skin lesions and exclude the diagnosis of either a viral infection or

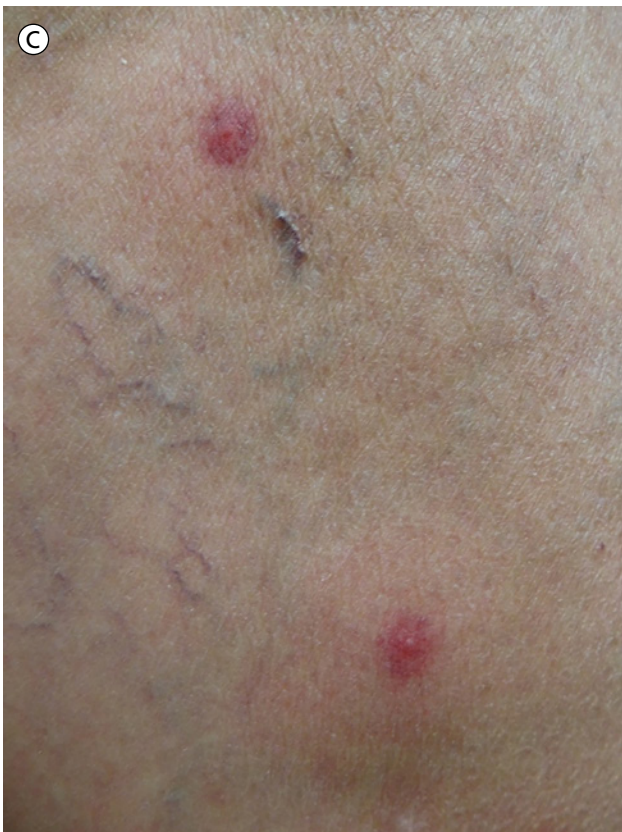
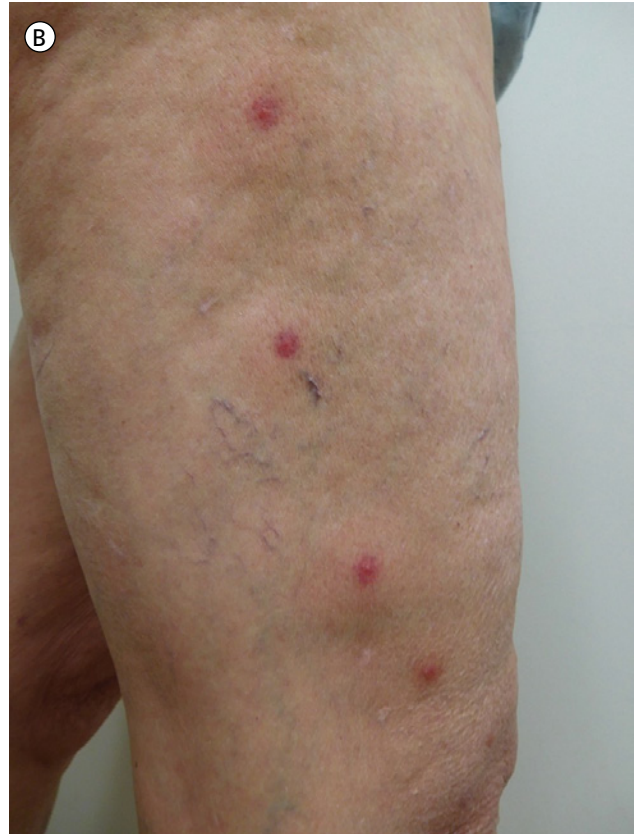
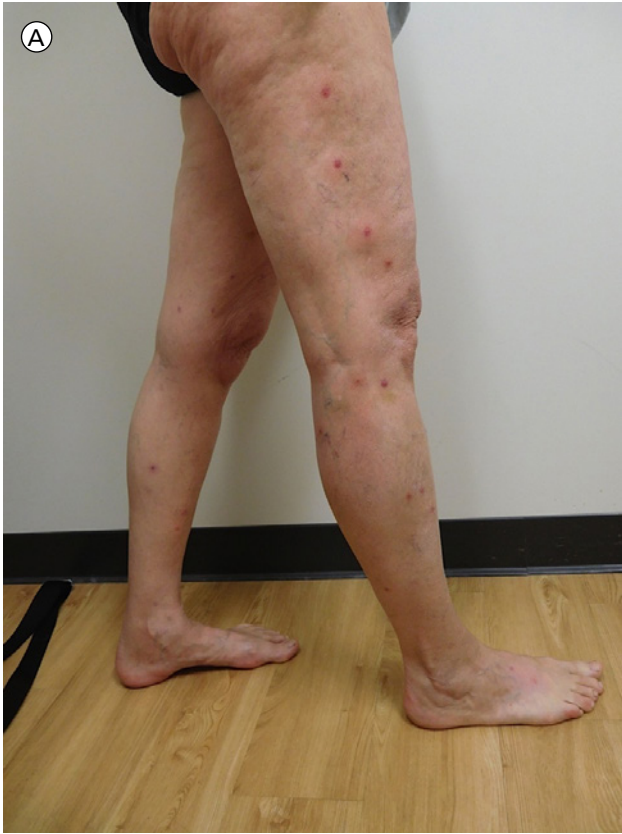**Figure 2.** Distant (A) and close (B) views of an isolated, non-dermatomal, erythematous-based vesicle appears on the lower left flank. [Copyright: ©2017 Bari et al.]



**Figure 3.** Microscopic examination of a low magnification view showing a large vesicle (A). Intermediate magnification views (B and C) of the lateral aspects of the vesicle demonstrating that it is intraepidermal and contains serosanguinous fluid with eosinophils. The base of the blister shows eosinophilic spongiosis (D); the spaces between keratinocytes are filled with eosinophils. In the underlying dermis, there is edema and a dense infiltrate that is not only diffuse but also perivascular and periadnexal; the infiltrate consists of lymphocytes and numerous eosinophils (D and E) (hematoxylin and eosin; a = x4; b = x20; c = x20; d = x20; and e = x40). [Copyright: ©2017 Bari et al.]

autoimmune bullous disease. It is conceivable that our patient may have initially had zoster sine herpette, which manifests as radicular pain without rash [26]. With a background of zoster sine herpette, the patient plausibly could have developed an immunocompromised zone and therefore displayed Wolf's isotopic response, in which a new skin disorder occurs at the site of a previously healed skin disease [27]. However, our investigation established the diagnosis of eosinophilic dermatosis of hematologic malignancy. Based on our patient's



**Figure 4.** Distant (A) and closer (B and C) views of a linear presentation of erythematous-based vesicles of eosinophilic dermatosis of hematologic malignancy corresponding to the left L4 dermatome. [Copyright: ©2017 Bari et al.]

morphologic presentation of eosinophilic dermatosis of hematologic malignancy, we add disseminated zoster infection with dermatomal and non-dermatomal distribution to the differential diagnosis of this condition.

**TABLE 1. Summary of eosinophilic dermatosis of hematologic malignancy [Copyright: ©2017 Bari et al.]**

Author, Year	Number of Cases	Associated Malignancy	Age; Sex	Clinical Manifestation	Histology	Management	EDHM Course	Ref
Weed, 1965	8	CLL	40-76; NR	Erythematous, indurated, and pruritic lesions in areas of recent mosquito bites or areas with central punctum	Subepidermal edema with dense dermal infiltrate of eosinophils and lymphocytes	CLL was treated with chlorambucil or prednisone in most patients	Lesions resolved spontaneously within weeks	1
Rosen, 1986	10	CLL	57-82; 7 M, 3 W	Erythematous and pruritic bullae, nodules, and papules at various locations	Superficial and deep, perivascular, periadnexal, and interstitial infiltrate of eosinophils and lymphocytes	Treatments for CLL included prednisone, vincristine, cyclophosphamide, and chlorambucil	NR	11
Kolbusz, 1989	1	CLL	51; W	Recurrent eruptions of erythematous urticarial patches on the extremities and trunk	Lymphohistiocytic infiltrate with eosinophils	Diphenhydramine for skin lesions	Initial outbreaks were self-limited with no treatment; later eruptions improved with diphenhydramine	12
Davis, 1998	8	CLL	51-69; 6 M, 2 W	Papular and vesiculobullous lesions in various locations	All biopsies revealed lymphohistiocytic infiltrate and eosinophils in the dermis	Chemotherapy, IVIG, and glucocorticoids	3 patients experienced improvement with chemotherapy for CLL; 1 patient improved with IVIG; 4 patients responded to oral glucocorticoids	10
Barzilai, 1999	8	ALL, AML, CLL (3 patients), MCL, LCL, MF	42-72; 4 M, 4 W	Recurrent erythematous, pruritic papules and plaques at various locations	Superficial and deep perivascular and interstitial infiltrate of eosinophils and lymphocytes	Topical antipruritic agents, topical and systemic corticosteroids, systemic antihistamines	No improvement with any agent except systemic corticosteroids, though lesions recurred when steroids were tapered	2
Blum, 2001	1	CLL	49; M	Admitted to the hospital after second cycle of chemotherapy with vesicles and hemorrhagic bullae on the extremities, face, and trunk	Superficial and deep perivascular dermatitis with interstitial eosinophils	Systemic corticosteroids	Lesions improved with steroids but recurred with tapered dose	13
Byrd, 2001	4	AML, CLL (2 patients), MDS	53-81; 4 M	Recurrent eruptions of erythematous, pruritic nodules and papules at various locations	Perivascular and periadnexal infiltrate with lymphocytes and eosinophils	Antibiotics, antifungals, antihistamines, colchicine, dapsone, hydroxyurea, hydroxychloroquine, isotretinoin, systemic and topical steroids, and UV-B phototherapy for skin lesions; chemotherapy started for malignancy	2 patients' lesions resolved during chemotherapy but recurred once it was complete, and chemotherapy was re-started to control skin lesions in these patients; 2 patients experienced improvement with phototherapy	3
Asakura, 2004	1	CLL	46; W	Pruritic, erythematous bullae on the extremities in the site of prior mosquito bites	NR	Cyclophosphamide and prednisolone for CLL	Skin lesions were self-limited	14
Cocuroccia, 2004	1	CLL	65; M	4-month history of recurrent pruritic bullae and papules on the extremities	Epidermal spongiosis, edema in papillary dermis, with superficial and deep, perivascular and interstitial infiltrate of eosinophils and neutrophils	Antihistamines and topical corticosteroids for skin lesions	Improvement after 10 days with mild recurrence after 2 weeks; no further lesions at 6-month follow-up	15

(Continued next page)

**TABLE 1. Summary of eosinophilic dermatosis of hematologic malignancy (continued)**

Author, Year	Number of Cases	Associated Malignancy	Age; Sex	Clinical Manifestation	Histology	Management	EDHM Course	Ref
Dodiuk-Gad, 2004	2	MCL	61, 64; 2 M	Patient 1 with 6-month duration of pruritic, erythematous nodules and papules on the extremities; Patient 2 with 2-year history of pruritic, erythematous nodules, papules, and plaques on the extremities	Patient 1 with epidermal spongiosis and microvesicles with eosinophils, along with an upper dermal infiltrate of eosinophils; Patient 2 with dense infiltrate of eosinophils and neutrophils in the dermis	Antipruritic agents, topical and oral steroids for skin lesions in Patient 1; Patient 2 started on CHOP and rituximab	Patient 1 improved with oral prednisone but lesions continued to recur; Patient 2 improved with chemotherapy	16
Khamaysi, 2005	6	CLL (3 patients) and MCL (3 patients)	56-74; 3 M, 3 W	Pruritic and erythematous nodules, papules, plaques, and vesicles	Superficial and deep perivascular and interstitial infiltrate with eosinophils and mononuclear cells	NR	NR	17
Vassallo, 2005	5	CLL (3 patients), NHL (2 patients)	NR; NR	Erythematous, pruritic bullae, papules, and plaques	Superficial and deep perivascular and interstitial infiltrate of eosinophils and lymphocytes	Antihistamines and systemic steroids for skin lesions	Improvement in skin lesions but flares continued to recur	18
Yoon, 2005	1	NMZL	46; M	6-year history of recurrent papulovesicular eruptions at various locations	Epidermal spongiosis with focal necrosis, edema in the papillary dermis, and perivascular, periadnexal, and interstitial infiltrate of eosinophils, lymphocytes, and neutrophils	6 courses of CHOP	Improvement in skin lesions with residual scar	19
Walker, 2007	1	CLL	69; W	18-month history of pruritic, erythematous plaques on the extremities	Spongiotic vesiculation and infiltrate of eosinophils in the papillary dermis	Antibiotics, fexofenadine, ibuprofen, oral prednisolone, promethazine, and topical betamethasone for skin lesions; rituximab for CLL	Poor response to all agents except ibuprofen and prednisolone, which reduced severity of outbreaks; once patient was switched to rituximab, she experienced less frequent flares	20
Rodríguez-Lojo, 2010	1	CLL	63; M	1-year history of recurrent urticarial nodules on the extremities and trunk	Infiltrate of eosinophils that involved fat lobules; later biopsies revealed dermal eosinophilic infiltrate with flame figures	Systemic steroids, topical steroids, and dapsone for skin lesions; CHOP for CLL	Recurrences were reduced with therapy for skin lesions; eruptions stopped when CLL was controlled	21
Bairey, 2012	48	CLL	33-82; 25 M, 23 F	Erythematous and pruritic macules, nodules, papules, and vesicles at various locations	Superficial and deep, interstitial and perivascular infiltrates of eosinophils and mononuclear cells	Antibiotics, antihistamines, dapsone, oral and topical steroids, phototherapy	60% of eruptions resolved with treatment, 24% improved, and 14% had no response to therapy	22
Farber, 2012	1	CLL	73; M	4-year history of recurrent erythematous, pruritic nodules and papules on the extremities, face, neck, scalp, and trunk	Dense superficial and deep perivascular infiltrate of eosinophils and lymphocytes	Doxycycline, hydroxyzine, and prednisone taper for skin lesions; chemotherapy started for CLL	Eruptions improved when chemotherapy started but recurred once it was completed; number of lesions and intensity of pruritus decreased but complete resolution was not achieved	4

(Continued next page)

**TABLE 1. Summary of eosinophilic dermatosis of hematologic malignancy (continued)**

Author, Year	Number of Cases	Associated Malignancy	Age; Sex	Clinical Manifestation	Histology	Management	EDHM Course	Ref
Mitteldorf, 2012	1	CLL	71; F	Pruritic, erythematous papulovesicular eruptions on the face and trunk	Focal epidermal spongiosis, edema within the papillary dermis, and superficial and deep perivascular and interstitial infiltrate of eosinophils and lymphocytes	Prednisolone for skin lesions; rituximab and bendamustine started for CLL	No cutaneous improvement from chemotherapy; steroids led to complete resolution of skin lesions	23
Qiao, 2013	1	CLL	67; W	9-month history of recurrent pruritic eruptions of bullae, papules, plaques, and vesicles on the extremities, face, and trunk	Prominent subepidermal blisters with diffuse infiltrate of eosinophils and flame figures in the dermis	Prednisone	Lesions improved within 10 days of prednisone but eruption recurred with steroid taper	5
Butzmann, 2014	1	CLL	60; W	6-month history of lesions on the extremities; presented with excoriated papules and vesicles	Intraepidermal vesicle with eosinophils; dermis with dense perivascular lymphocytic infiltrate with eosinophils	Topical corticosteroids and oral antihistamines	Reduced recurrence rate and intensity of new lesions	24
Two, 2014	1	MM	50; M	3-month history of pruritic vesicles on the extremities and trunk	Superficial and deep mixed perivascular infiltrate of eosinophils and lymphocytes	Topical corticosteroids for skin lesions; bortezomib, carfilzomib, and dexamethasone for MM	Vesicles disappeared at 6-week follow-up after stopping topical steroids though MM was undergoing continued therapy	6
Liu, 2015	1	CLL	45; W	5-year history of recurrent pruritic blisters, papules, and plaques on the extremities and face	Subepidermal edema with dense nodular and interstitial infiltrate of eosinophils and lymphocytes in the dermis and subcutaneous tissue	Prednisolone for 12 months	Lesions continued to recur	25
Penn, 2015	1	DLBCL	56; W	Pruritic papular eruptions on the extremities	Superficial and deep perivascular infiltrate of eosinophils and lymphocytes	Antihistamines, intralesional glucocorticoids, and topical glucocorticoids for skin lesions; rituximab and bendamustine for CLL	Eruptions improved with systemic therapy for malignancy along with regimen of antihistamines and steroids	7
Jayasekera, 2016	1	CLL	51; M	Several week history of papules and plaques on the extremities	Epidermal spongiosis and interstitial infiltrate of eosinophils	Topical betamethasone, dapsone, oral prednisolone with topical clobetasol; idelalisib and rituximab for CLL	Failed topical steroids; rash flared once oral prednisolone was tapered	9
Martires, 2016	1	CLL	68; W	5-month history of recurrent pruritic bullae on the extremities and face	Epidermal spongiosis with superficial and deep mixed infiltrate of eosinophils, lymphocytes, and neutrophils	Methylprednisolone, prednisone, and high-potency topical glucocorticoids for skin lesions	Rate of resolution increased but lesions continued to recur	8

*(Continued next page)*



**TABLE 1. Summary of eosinophilic dermatosis of hematologic malignancy (continued)**

Author, Year	Number of Cases	Associated Malignancy	Age; Sex	Clinical Manifestation	Histology	Management	EDHM Course	Ref
Bari and Cohen, 2017	1	CLL	59; W	5-year history of dermatomal and non-dermatomal distribution of vesicles on the back and flanks	Eosinophilic spongiosis, intraepidermal vesicle with eosinophils, and perivascular and periadnexal lymphocytic infiltrate with eosinophils	Acyclovir, topical betamethasone for skin lesions; CLL was treated with many agents but most recently the patient was started on obinutuzumab	Acyclovir was not efficacious, though topical betamethasone led to temporary resolution of skin lesions; patient experienced fewer recurrences after obinutuzumab was started	CR

Abbreviations: ALL, acute lymphocytic leukemia; AML, acute monocytic leukemia; CHOP, cyclophosphamide, hydroxydaunorubicin, oncovin, and prednisone; CLL, chronic lymphocytic leukemia; CR, current report; DLBCL, diffuse large B cell lymphoma; EDHM, eosinophilic dermatosis of hematologic malignancy; IVIG, intravenous immunoglobulin; LCL, large cell lymphoma; M, man; MCL, mantle cell lymphoma; MDS, myelodysplastic syndrome; MF, myelofibrosis; MM, multiple myeloma; NHL, non-Hodgkin lymphoma; NMZL, nodal marginal zone lymphoma; NR, not reported; Ref, reference; UV-B, ultraviolet-B phototherapy; W, woman

## References

- Weed RI. Exaggerated Delayed Hypersensitivity to Mosquito Bites in Chronic Lymphocytic Leukemia. *Blood*. 1965;26:257-268.
- Barzilai A, Shpiro D, Goldberg I, et al. Insect bite-like reaction in patients with hematologic malignant neoplasms. *Arch Dermatol*. 1999;135(12):1503-1507.
- Byrd JA, Scherschun L, Chaffins ML, Fivenson DP. Eosinophilic dermatosis of myeloproliferative disease: characterization of a unique eruption in patients with hematologic disorders. *Arch Dermatol*. 2001;137(10):1378-1380.
- Farber MJ, La forgia S, Sahu J, Lee JB. Eosinophilic dermatosis of hematologic malignancy. *J Cutan Pathol*. 2012;39(7):690-695.
- Qiao J, Sun CE, Zhu W, Zhu D, Fang H. Flame figures associated with eosinophilic dermatosis of hematologic malignancy: is it possible to distinguish the condition from eosinophilic cellulitis in patients with hematoproliferative disease? *Int J Clin Exp Pathol*. 2013;6(8):1683-1687.
- Two AM, Li C, Hata T. A case of eosinophilic dermatosis of hematologic malignancy in a patient with multiple myeloma. *Dermatol Online J*. 2014;20(1):21256.
- Penn L, Ahern I, Mir A, Meehan SA. Eosinophilic dermatitis of hematologic malignancy. *Dermatol Online J*. 2015;21(12).
- Martires K, Callahan S, Terushkin V, Brinster N, Leger M, Soter N. Eosinophilic dermatosis of hematologic malignancy. *Dermatol Online J*. 2016;22(12).
- Jayasekera PS, Bakshi A, Al-sharqi A. Eosinophilic dermatosis of haematological malignancy. *Clin Exp Dermatol*. 2016;41(6):692-695.
- Davis MD, Perniciaro C, Dahl PR, Randle HW, Mcevoy MT, Leiferman KM. Exaggerated arthropod-bite lesions in patients with chronic lymphocytic leukemia: a clinical, histopathologic, and immunopathologic study of eight patients. *J Am Acad Dermatol*. 1998;39(1):27-35.
- Rosen LB, Frank BL, Rywlin AM. A characteristic vesiculobullous eruption in patients with chronic lymphocytic leukemia. *J Am Acad Dermatol*. 1986;15(5 Pt 1):943-950.
- Kolbusz RV, Micetich K, Armin AR, Massa MC. Exaggerated response to insect bites. An unusual cutaneous manifestation of chronic lymphocytic leukemia. *Int J Dermatol*. 1989;28(3):186-187.
- Blum RR, Phelps RG, Wei H. Arthropod bites manifesting as recurrent bullae in a patient with chronic lymphocytic leukemia. *J Cutan Med Surg*. 2001;5(4):312-314.
- Asakura K, Kizaki M, Ikeda Y. Exaggerated cutaneous response to mosquito bites in a patient with chronic lymphocytic leukemia. *Int J Hematol*. 2004;80(1):59-61.
- Cocuroccia B, Gisondi P, Gubinelli E, Girolomoni G. An itchy vesiculobullous eruption in a patient with chronic lymphocytic leukaemia. *Int J Clin Pract*. 2004;58(12):1177-1179.
- Dodiuk-Gad RP, Dann EJ, Bergman R. Insect bite-like reaction associated with mantle cell lymphoma: a report of two cases and review of the literature. *Int J Dermatol*. 2004;43(10):754-758.
- Khamaysi Z, Dodiuk-gad RP, Weltfriend S, et al. Insect bite-like reaction associated with mantle cell lymphoma: clinicopathological, immunopathological, and molecular studies. *Am J Dermatopathol*. 2005;27(4):290-295.
- Vassallo C, Passamonti F, Cananzi R, et al. Exaggerated insect bite-like reaction in patients affected by oncohaematological diseases. *Acta Derm Venereol*. 2005;85(1):76-77.
- Yoon TY, Kim YG, Kim JW, Kim MK. Nodal marginal zone lymphoma in association with hydroa vacciniforme-like papulovesicular eruption, hypersensitivity to mosquito bites and insect bite-like reaction. *Br J Dermatol*. 2005;153(1):210-212.
- Walker P, Long D, James C, Marshman G. Exaggerated insect bite reaction exacerbated by a pyogenic infection in a patient with chronic lymphocytic leukaemia. *Australas J Dermatol*. 2007;48(3):165-169.
- Rodríguez-Lojo R, Almagro M, Piñeyro F, et al. Eosinophilic panniculitis and insect bite-like eruption in a patient with chronic lymphocytic leukaemia: a spectrum of the same entity. *Dermatol Res Pract*. 2010;2010:263827.
- Bairey O, Goldschmidt N, Ruchlemer R, et al. Insect-bite-like reaction in patients with chronic lymphocytic leukemia: a study from the Israeli Chronic Lymphocytic Leukemia Study Group. *Eur J Haematol*. 2012;89(6):491-496.
- Mitteldorf C, Tronnier M, Merz H, et al. Insect bite-like reactions in a patient with B-cell chronic lymphocytic leukaemia: fluorescence in situ hybridization analysis revealed neoplastic B cells within the skin infiltrate. *Br J Dermatol*. 2012;167(4):944-946.

24. Butzmann CM, Kern JS, Stanislawski G, Meiss F. Insect bite-like reaction in a patient with chronic lymphocytic leukemia. *J Dtsch Dermatol Ges.* 2014;12(8):734-737.
25. Liu KC, Hsu CK, Lee JY. Insect bite-like reaction in association with chronic lymphocytic leukemia. *Int J Dermatol.* 2015;54(10):1191-1193.
26. Gildea D, Cohrs RJ, Mahalingam R, Nagel MA. Neurological disease produced by varicella zoster virus reactivation without rash. *Curr Top Microbiol Immunol.* 2010;342:243-253.
27. Wolf R, Wolf D, Ruocco E, Brunetti G, Ruocco V. Wolf's isotopic response. *Clin Dermatol.* 2011;29(2):237-240.