

## Eosinophilic Pustular Folliculitis in the Setting of Solid Organ Transplant Immunosuppression

Jeffrey Chen<sup>1</sup>, Colleen J Beatty<sup>2</sup>, Lauryn M Falcone<sup>3</sup>, Joseph C English III<sup>3</sup>,  
Viktoryia Kazlouskaya<sup>2</sup>

<sup>1</sup> University of Pittsburgh School of Medicine, Pittsburgh, Pennsylvania, United States

<sup>2</sup> University of Pittsburgh Department of Dermatology/Dermatopathology, Pittsburgh, Pennsylvania, United States

<sup>3</sup> University of Pittsburgh Department of Dermatology, Pittsburgh, Pennsylvania, United States

**Key words:** Eosinophilic pustular folliculitis, Ofuji disease, hematopoietic stem cell transplantation, immunosuppression, immune reconstitution inflammatory syndrome

**Citation:** Chen J, Beatty CJ, Falcone LM, English JC, Kazlouskaya V. Eosinophilic Pustular Folliculitis in the Setting of Solid Organ Transplant Immunosuppression. *Dermatol Pract Concept.* 2023;13(2):e2023078. DOI: <https://doi.org/10.5826/dpc.1302a78>

**Accepted:** June 20, 2023; **Published:** April 2023

**Copyright:** ©2023 Chen et al. This is an open-access article distributed under the terms of the Creative Commons Attribution-NonCommercial License (BY-NC-4.0), <https://creativecommons.org/licenses/by-nc/4.0/>, which permits unrestricted noncommercial use, distribution, and reproduction in any medium, provided the original authors and source are credited.

**Funding:** None.

**Competing interests:** None.

**Authorship:** All authors have contributed significantly to this publication.

**Corresponding author:** Viktoryia Kazlouskaya, MD, PhD, University of Pittsburgh, Department of Dermatology and Dermatopathology, Medical Arts Building, 3708 5<sup>th</sup> Avenue, Suite 500.68, Pittsburgh, Pennsylvania 15213 E-mail: [viktoriakozlovskaya@yahoo.com](mailto:viktoriakozlovskaya@yahoo.com)

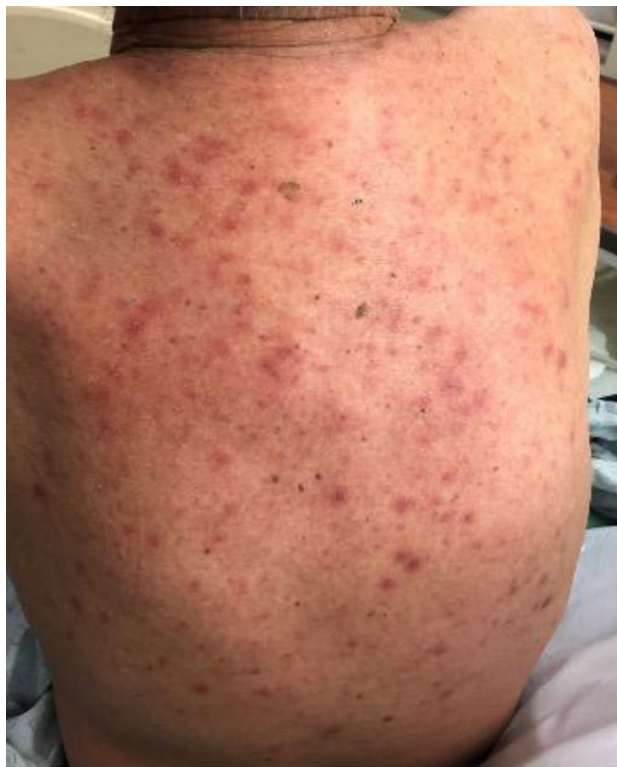### Introduction

Eosinophilic pustular folliculitis (EPF) is an inflammatory dermatosis that presents as follicular papulopustules with pronounced eosinophils. Subtypes include classic EPF, infancy-associated EPF, and immunosuppression-associated EPF (IS-EPF). IS-EPF can be sub-divided into HIV-associated (IS/HIV) and non-HIV-associated (IS/non-HIV), with the latter associated with hematologic malignancy, particularly after hematopoietic stem cell transplantation (HSCT) [1]. Herein, we describe a case of IS-EPF in the setting of chronic immunosuppression due to cardiac transplantation. This is the second reported case of IS-EPF associated with solid organ transplant, with the first reported case in 2014 by Kim et al [2].

### Case Presentation

A 69-year-old male on long-term immunosuppression for cardiac transplantation secondary to non-ischemic cardiomyopathy was evaluated for a diffuse pruritic rash that began several weeks after switching medications from tacrolimus to sirolimus. Skin examination revealed multiple erythematous to purpuric papules involving the torso, upper back, and upper extremities (Figure 1). Exanthematous drug eruption was favored as the initial diagnosis due to temporal correlation, but graft-versus-host disease, neutrophilic dermatitis, and infectious process were also considered.

Histopathological examination revealed mid-dermal perifollicular collections of lymphocytes, histiocytes, and



**Figure 1.** Erythematous swollen papulopustules on the back.

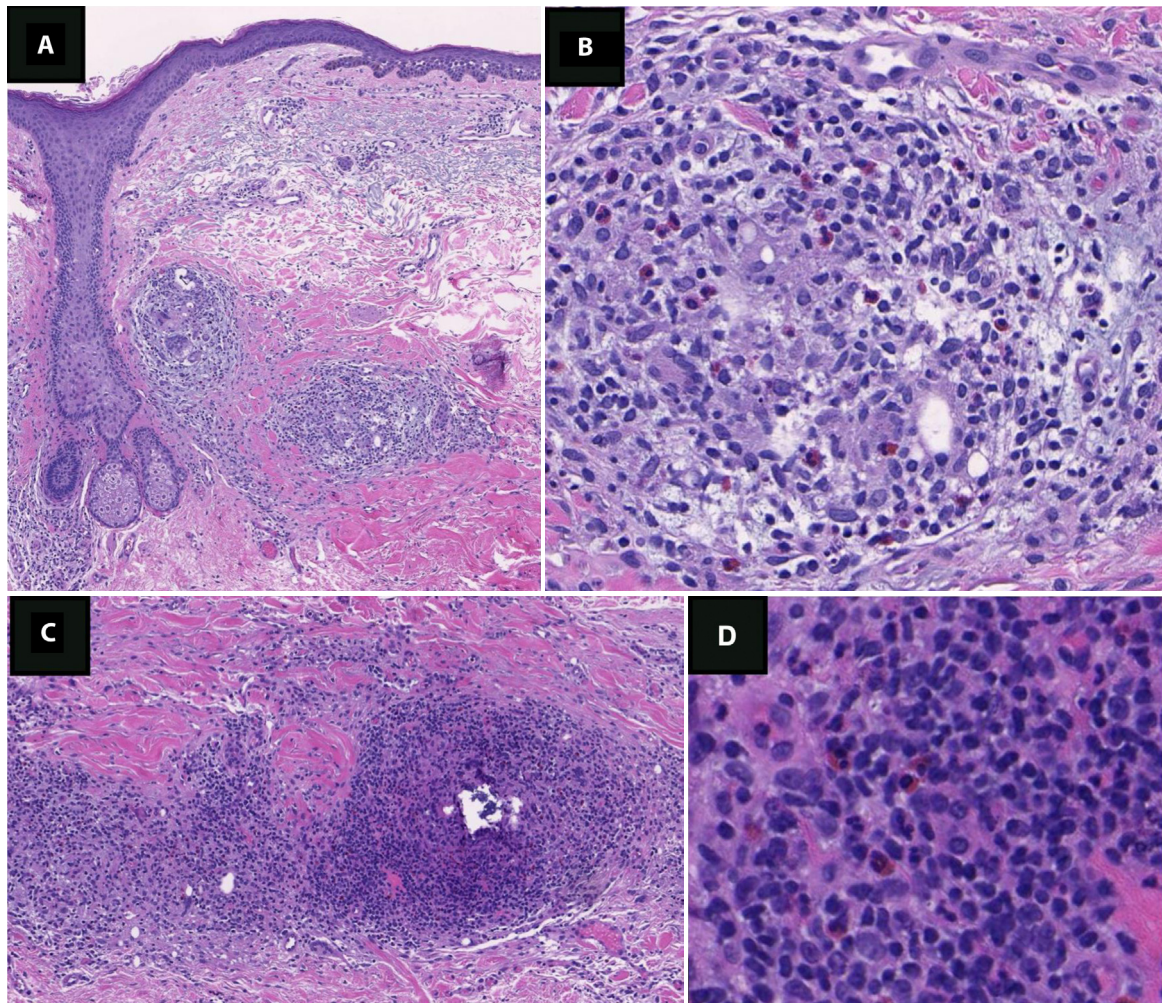
prominent eosinophils (Figure 2). GMS, Gram, AFB, and PAS stains were negative. Biopsy findings were consistent with EPF, likely associated with the patient's immunosuppression. The patient was treated with triamcinolone acetone cream and showed gradual resolution.

## Conclusions

While the pathophysiology of EPF is unknown, prostaglandin D2 (PGD2) and the IL-36 cytokine family are speculated to be involved in the folliculotropic infiltration of eosinophils [3,4]. Increases in PGD2 production in EPF have been demonstrated to increase mRNA expression of eotaxin-3, which is an eosinophilic chemotactic factor produced by sebocytes [3]. IL36 $\alpha$ , IL-36 $\beta$ , IL-36 $\gamma$ , and IL36Ra are known modulators of the cutaneous inflammatory response involved in eosinophil recruitment. Previous studies showed that IL-36 $\beta$ , IL-36 $\gamma$ , and IL36Ra are upregulated in EPF. Interestingly, the expression of IL36Ra was negatively correlated with IL-36 $\beta$  and IL-36 $\gamma$  in normal skin, suggesting

that the expression patterns of IL-36 $\beta$ , IL-36 $\gamma$ , and IL36Ra contribute partially to the eosinophil migration in EPF [4].

Unlike classic EPF, the lesions observed in IS-EPF are less strongly associated with the formation of pustules and do not show the same predilection for the face, as they tend to affect the upper body and extremities [1]. Moreover, IS-EPF responds more favorably to topical or systemic steroids compared to classic EPF suggesting different pathogenesis [5]. The clinicopathological features of this case are similar to those observed in IS/non-HIV patients, specifically, cases of IS-EPF that developed after HSCT. A study by Sasaki et al likened the lesions of IS-EPF following HSCT to the development of IS-EPF in HIV patients caused by immune reconstitution inflammatory syndrome (IRIS) [6]. In our case, the patient developed EPF after his tacrolimus was switched to sirolimus, which is a decrease in immunosuppression and a step closer to immune reconstitution. Accordingly, this case provides preliminary evidence to suggest a relationship between IRIS and IS-EPF in the setting of solid organ transplant immunosuppression, however, further accumulation of cases is needed to investigate this potential association.



**Figure 2.** (A) Perifollicular granulomatous inflammation (H&E, x200). (B) High power demonstrating numerous eosinophils in the infiltrate (H&E stain, x400). (C) Another focus with keratin remnants surrounded by granulomatous inflammation (H&E stain, x200). (D) High power demonstrating numerous eosinophils in the infiltrate (H&E stain, x400).

## References

1. Katoh M, Nomura T, Miyachi Y, Kabashima K. Eosinophilic pustular folliculitis: A review of the Japanese published works. *J Dermatol.* 2013;40(1):15-20. DOI: 10.1111/1346-8138.12008. PMID: 23083212.
2. Kim BW, Lee JH, Won CH, et al. Eosinophilic Pustular Folliculitis: Association with Long-Term Immunosuppressant Use in a Solid Organ Transplant Recipient. *Ann Dermatol.* 2014;26(4):520-521. DOI: 10.5021/ad.2014.26.4.520. PMID: 25143686. PMCID: PMC4135112.
3. Nakahigashi K, Doi H, Otsuka A, et al. PGD2 induces eotaxin-3 via PPAR $\gamma$  from sebocytes: a possible pathogenesis of eosinophilic pustular folliculitis. *J Allergy Clin Immunol.* 2012;129(2):536-543. DOI: 10.1016/j.jaci.2011.11.034. PMID: 22206772.
4. Sato S, Chiba T, Nakahara T, Furue M. Upregulation of IL-36 cytokines in folliculitis and eosinophilic pustular folliculitis. *Australas J Dermatol.* 2020;61(1):e39-e45. DOI: 10.1111/ajd.13143. PMID: 31424098.
5. Nomura T, Katoh M, Yamamoto Y, Miyachi Y, Kabashima K. Eosinophilic pustular folliculitis: A published work-based comprehensive analysis of therapeutic responsiveness. *J Dermatol.* 2016;43(8):919-927. DOI: 10.1111/1346-8138.13287. PMID: 26875627.
6. Sasaki Y, Kishi A, Takagi S, Uchida N, Hayashi N. Eosinophilic pustular folliculitis after hematopoietic stem cell transplantation: A study of 11 cases. *J Dermatol.* 2021;48(5):e231-e233. DOI: 10.1111/1346-8138.15846. PMID: 33715192. PMCID: PMC8251622.