

Laugier-Hunziker syndrome: a case of asymptomatic mucosal and acral hyperpigmentation

Elizabeth H. Cusick¹, Ashfaq A. Marghoob², Ralph P. Braun³

¹ Stony Brook University School of Medicine, Stony Brook, NY, USA

² Memorial Sloan Kettering Skin Cancer Center, New York, NY, USA

³ Department of Dermatology, University Hospital Zurich, Zurich Switzerland

Key words: Laugier-Hunziker, mucosal and acral hyperpigmentation, mucocutaneous hyperpigmentation

Citation: Cusick EH, Marghoob AA, Braun RP. Laugier-Hunziker syndrome: a case of asymptomatic mucosal and acral hyperpigmentation. *Dermatol Pract Concept.* 2017;7(2):5. DOI: <https://doi.org/10.5826/dpc.0702a05>

Received: January 3, 2017; **Accepted:** January 14, 2017; **Published:** April 30, 2017

Copyright: ©2017 Cusick et al. This is an open-access article distributed under the terms of the Creative Commons Attribution License, which permits unrestricted use, distribution, and reproduction in any medium, provided the original author and source are credited.

Funding: None.

Competing interests: The authors have no conflicts of interest to disclose.

All authors have contributed significantly to this publication.

Corresponding author: Elizabeth H. Cusick, BS, Stony Brook University School of Medicine, 101 Nicolls Road, Stony Brook, NY 11794, USA. Tel. 718-354-5936. Email: Elizabeth.cusick@stonybrookmedicine.edu

ABSTRACT Laugier-Hunziker syndrome (LHS) is a rare condition characterized by acquired hyperpigmentation involving the lips, oral mucosa, acral surfaces, nails and perineum. While patients with LHS may manifest pigmentation in all of the aforementioned areas, most present with pigmentation localized to only a few of these anatomical sites. We herein report a patient exhibiting the characteristic pigment distribution pattern associated with LHS. Since LHS is a diagnosis based on exclusion, we discuss the differential diagnosis of mucocutaneous hyperpigmentation. Due to the benign nature of the disease, it is critical to differentiate this disorder from conditions with similar mucocutaneous pigmentary changes with somatic abnormalities that require medical management. We also explore potential mechanisms that may explain the pathogenesis of LHS.

Introduction

Laugier-Hunziker syndrome (LHS) is a benign pigmentary condition characterized by hyperpigmented mucocutaneous macules progressively arising during adulthood. The asymptomatic melanotic macules most commonly involve the lips, oral mucosa, and acral surfaces, with occasional nail involvement. While LHS is a rare disorder of unknown etiology, it is important to differentiate it from conditions with similar pigmentary changes with somatic abnormalities that necessitate further investigation and treatment. In this case, we present the history, clinical findings, and histopathology of

a patient exhibiting the pigmentary features consistent with LHS in order to highlight the critical differential diagnosis of asymptomatic mucosal and acral hyperpigmentation and to explore the potential pathogenesis of LHS.

Case Presentation

A man in his 50s presented with multiple pigmented macules of the lips, palate, and fingers. Over the course of one year, the patient noted the gradual onset and progression in the number of lesions and degree of pigmentation. The lesions were asymptomatic and the patient felt otherwise well. The

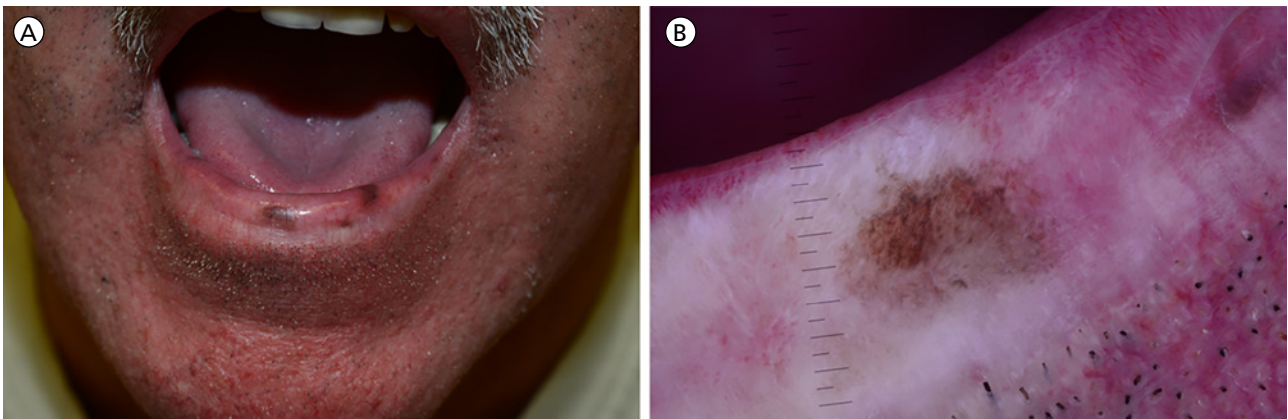


Figure 1. (A) Clinical manifestations of the pigmented macules of the lower lips, (B) dermoscopic examination of the pigmented lesions reveals a fish scale-like pattern. [Copyright: ©2017 Cusick et al.]

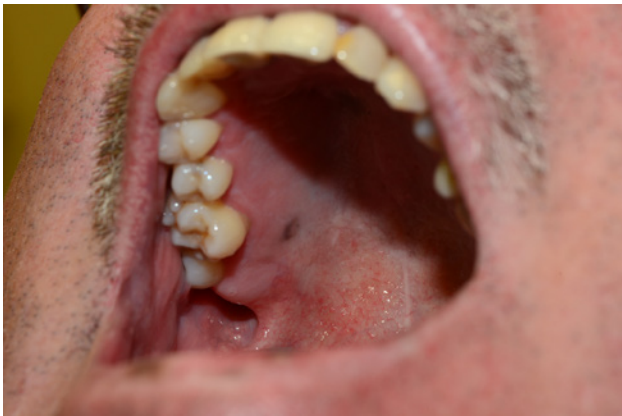

Figure 2. Clinical manifestations of the pigmented macules located on the hard palate. [Copyright: ©2017 Cusick et al.]

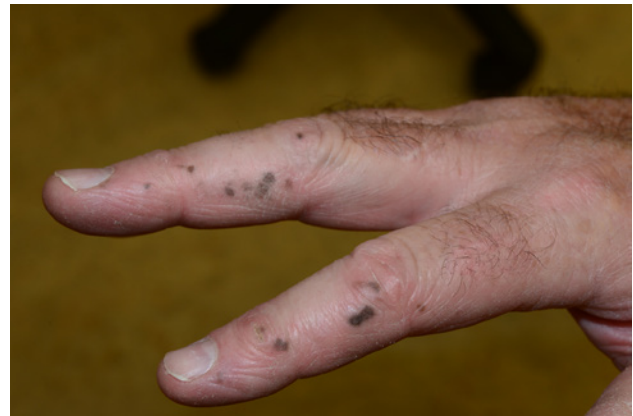

Figure 3. Clinical manifestations of the pigmented macules of the lateral aspects of the second and third right finger. [Copyright: ©2017 Cusick et al.]

patient's history was significant for melanoma in situ which was treated five years prior to the onset of the pigmentation of his lips and fingers. The patient was a non-smoker and he had no other relevant medication history. The patient denied a history of trauma or exposures to heavy metals. There was no familial history of pigmentary disorders and digestive polyposis or tumors.

Physical examination revealed multiple 2 to 5 mm brown to grayish macules on the lower lip (Figure 1A) and two grayish macules on the hard palate (Figure 2). On dermoscopy the macules on the lip revealed a fish scale-like dermoscopy pattern (Figure 1B). There were several brown to grayish-brown macules on the lateral aspect of his right index, thumb, and middle fingers (Figure 3), accompanied by similar appearing macules on his left thumb. Dermoscopy revealed pigmented macules with a brown to grayish homogeneous pattern (Figure 4A, B). There were no pigmented lesions noted on the palms, soles, nails, perineum, or conjunctiva. No axillary or inguinal lymphadenopathy was found.

A biopsy of a representative lesion on the lower lip was performed. Histopathologic examination revealed hyperpigmentation of the stratum basalis. There was hyperparakeratosis and acanthosis of the epithelium, with elongated rete ridges, as well as a few melanophages in the dermis.

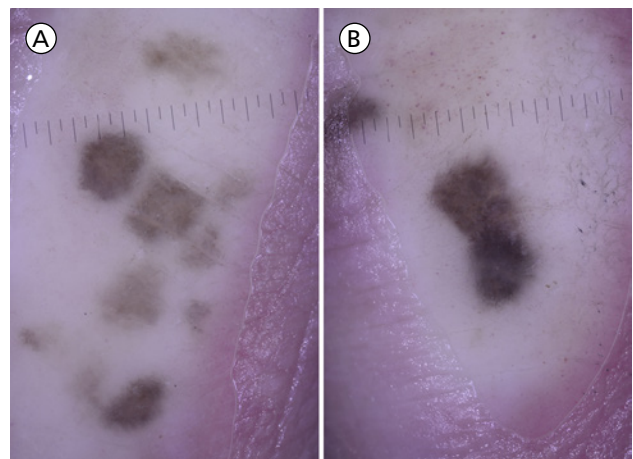


Figure 4. (A, B) Dermoscopic examination of the pigmented lesions reveal homogeneous brownish to grayish pattern. [Copyright: ©2017 Cusick et al.]

Given the morphology and distribution of the pigmented macules on the palate, lower lip, and fingers, and based on the fact that the patient had no exposure to heavy metals, no signs of Addison's disease, or Peutz-Jeghers syndrome, leads one to conclude that the patient has LHS.

Discussion

Laugier and Hunziker first reported an uncommon condition characterized by acquired melanotic hyperpigmented macules of the oral mucosa, lips, fingers, with occasional nail involvement, in otherwise asymptomatic patients [1]. LHS typically arises during adulthood and follows a chronic course without remission. The lesions are most commonly located on the lips and oral cavity, including the buccal mucosa, soft palate, hard palate, and gingiva [2]. Longitudinal melanonychia is evident in about half the cases. Pigmentation may spread from the proximal nail fold into the surrounding skin [3].

Histopathologic features of the pigmented macules described by Laugier and Hunziker demonstrated intraepidermal melanosis without melanocytosis [1]. The majority of subsequent reports of melanotic macules from LHS demonstrate normal numbers and normal morphologic appearance of melanocytes with increased basal pigmentation due to melanin deposition without hyperplasia of melanocytes [3]. However, there have been some publications reporting increased numbers of intraepidermal melanocytes distributed in a lentiginous pattern [4,5]. Due to the rarity of this condition, there are no long-term studies to determine risk for malignant degeneration. With that said, there is one reported case of mucosal melanoma of the upper lip in a patient affected by the long-standing melanocytic hyperplasia of LHS [6].

Although the etiology of LHS is unknown, the pathogenesis is thought to be due to an alteration of melanocytes, resulting in an increased synthesis of melanosomes and their transport to the basal cell layers, resulting in the accumulation of melanin in the basal keratinocytes of the epidermis [4].

To our knowledge, no prior studies have examined the significance of the distribution of the lesions in LHS. Localization of this condition primarily to mucosal and acral surfaces may provide a clue into the mechanism of action of this disease. Advancements in our understanding of mucosal and acral melanoma have revealed the type III tyrosine kinase receptor c-Kit (CD117) as a key player in the oncogenic alterations involved in some acral and mucosal melanomas [7]. This is supported by evidence of successful use of c-Kit inhibitors, such as imatinib, in achieving remission for patients with metastatic melanomas from acral and mucosal sites with c-Kit aberrations [8,9].

Gain-of-function mutations in the Kit oncogene, encoding c-Kit, are associated with chronic myeloid leukemia and gastrointestinal stromal tumor (GIST) development [10]. Interestingly, there are reported cases of germline mutation of c-Kit demonstrated in a patient with numerous lentiginos and GISTs [10]. It is possible that the gain-of-function mutation of c-Kit pathway may activate the downstream pathways and promote proliferation of melanocytes, leading to the melano-

cytic hyperplasia involved in formation of mucosal and acral macules of LHS. It has been shown that at the site of the ligand stem cell factor (SCF) injection (used for promoting hematopoiesis), there is an increased number of melanocytes, melanocytic dendrite extension and melanin [11]. With the xenografts of normal human skin, SCF stimulation resulted in hyperplasia of melanocytes, causing the increased size and number of melanocytes and expression of melanocyte differentiation antigen, while inhibition of Kit resulted in decreased antigen expression, and size and number of melanocytes [11].

Several differential diagnoses must be considered in an adult patient presenting with multiple mucocutaneous pigmented macules. Due to the benign nature of the disease, it is critical to differentiate this disorder from conditions with similar mucocutaneous pigmentary changes with somatic abnormalities that require medical attention [12]. The differential diagnosis considered for this adult patient with hyperpigmentation of fingers and lips included medication-induced, exposures to heavy metals, Addison's disease, and rare genetic syndromes such as Peutz-Jeghers syndrome (PJS).

Drug-induced pigmentation, most commonly associated with phenytoin, anti-malarial, and HIV medications, will usually occur after months or years of chronic use of drugs and resolves once the drug is discontinued [3]. Anti-malarial drug administration may cause asymptomatic hyperpigmented macules on the oral mucosa and pretibial shin [2]. Exogenous brown to black pigmentation may also result from exposure to tar, dirt, tobacco, and potassium permanganate [3]. For example, cigarette smoking may result in oral mucosal pigmentation in the anterior gingiva [13].

Addison's disease, an endocrine disease caused by insufficient cortisol and aldosterone production, is characterized by hyperpigmentation of the skin and mucosal membranes, with increased level of circulating adrenocorticotrophic hormone (ACTH). In Addison's disease, longitudinal pigmented bands may appear on the nails and diffuse pigmentation may appear on mucosal surfaces, especially the buccal mucosa, gums, and tongue [3]. The well-circumscribed macules of LHS are distinctive from the more diffuse pigmentation of Addison's disease. Negative systemic symptoms, such as fatigue and weight loss, and normal plasma levels of cortisol and ACTH rule out this possibility [14].

Peutz-Jeghers syndrome (PJS), an autosomal dominant genodermatosis due to mutations in the gene encoding serine/threonine kinase 11 (STK11), is notable for mucocutaneous lentiginos and intestinal polyposis [2]. Patients with PJS present with hyperpigmented macules of oral and acral skin arising in the first few years of life. A histologic examination of these lesions shows increased melanin in the stratum basalis, and melanin is concentrated at the tips of the rete ridges [2]. Overlapping clinical features in both LHS and PJS may cause diagnostic confusion. In PJS, hyperpigmented macules of the

oral mucosa and acral skin may be present at birth or appear in early life, in contrast to the lesions in LHS, which usually occur in adulthood. Unlike LHS, lesions of PJS typically do not involve the tongue, palate, or fingernails. Lastly, PJS is associated with hamartomatous polyps of the gastrointestinal tract, whereas LHS is not [3].

Although rare, Bandler syndrome presents as hyperpigmented macules on the hands, nails, and oral mucosa and is associated with intestinal vascular malformation developing in infancy [3]. LAMB syndrome is characterized by pigmentation of the skin mucosa, atrial and mucocutaneous melanomas, and multiple blue nevi [2]. LEOPARD syndrome is manifested by numerous lentigines, electrocardiographic abnormalities, occasional hypertelorism, pulmonic stenosis, abnormalities of genitalia, retardation of growth, and deafness [2].

Given that our patient's pigmented macules of the lips and oral mucosa appeared late in life, in the absence of other somatic abnormalities and without a relevant family history of findings typical of PJS, our diagnosis was most consistent with LHS. In conclusion, LHS is an important consideration with a patient presenting with otherwise asymptomatic mucosal and acral hyperpigmentation. Despite the low prevalence of the LHS, the prompt clinical recognition avoids the need for excessive and invasive procedures and workup.

References

1. Laugier P, Hunziker N. Pigmentation melanique lenticulaire, essentielle de la muqueuse jugale et des levres. *Arch Belges Dermatol Syphiligr*. 1970;26(3):391-399.
2. Nikitakis NG, Koumaki D. Laugier–Hunziker syndrome: case report and review of the literature. *Oral Surg Oral Med Oral Pathol Oral*. 2013;116(1):e52-8.
3. Rangwala S, Doherty CB, Katta R. Laugier-Hunziker syndrome: A case report and review of the literature. *Dermatol Online J*. 2010 Dec 1;16(12).
4. Moore RT, Chae KM, Rhodes AR. Laugier and Hunziker pigmentation: a lentiginous proliferation of melanocytes. *J Am Acad Dermatol*. 2004;50(5):70-74.
5. Koch SE, LeBoit PE, Odom RB. Laugier-Hunziker syndrome. *J Am Acad Dermatol*. 1987;16(2):431-434.
6. Simionescu O, Dumitrescu D, Costache M, Blum A. Dermatoscopy of an invasive melanoma on the upper lip shows possible association with Laugier–Hunziker syndrome. *J Am Acad Dermatol*. 2008;59(5):S105-S108.
7. Tacastacas JD, Bray J, Cohen YK, et al. Update on primary mucosal melanoma. *J Am Acad Dermatol*. 2014;71(2):366-375.
8. Posch C, Moslehi H, Sanlorenzo M, et al. Pharmacological inhibitors of c-KIT block mutant c-KIT mediated migration of melanocytes and melanoma cells in vitro and in vivo. *Oncotarget*. 2016;7(29):45916-45925.
9. Alexis JB, Martinez AE, Lutzky J. An immunohistochemical evaluation of c-kit (CD-117) expression in malignant melanoma, and results of imatinib mesylate (Gleevec) therapy in three patients. *Melanoma Res*. 2005;15(4):283-5.
10. Shibusawa Y, Tamura A, Mochiki E, Kamisaka K, Kimura H, Ishikawa O. c-kit Mutation in generalized lentigines associated with gastrointestinal stromal tumor. *Dermatology*. 2004; 208(3):217-220.
11. Costa JJ, Demetri GD, Harnett T, et al. Recombinant human stem cell factor (kit ligand) promotes human mast cell and melanocyte hyperplasia and functional activation in vivo. *J Exper Med*. 1996;183(6):2681-2686.
12. Vachiramon V, McMichael AJ. Approaches to the evaluation of lip hyperpigmentation. *Int J Dermatol*. 2012;51(7):761-770.
13. Wang WM, Wang X, Duan N, Jiang HL, Huang XF. Laugier–Hunziker syndrome: a report of three cases and literature review. *Int J Oral Sci*. 2013;4(4):226-230.
14. Lema B, Najarian DJ, Lee M, Miller C. Numerous hyperpigmented macules of the oral mucosa. *J Am Acad Dermatol*. 2010;62 (1):171-173.