

Dermoscopic Features of Granular Cell Tumor

Lluís Corbella-Bagot¹, Jaime Piquero-Casals², Daniel Morgado-Carrasco¹

¹ Department of Dermatology, Hospital Clínic de Barcelona, University of Barcelona, Barcelona, Spain

² Dermik, Clínica Dermatológica Multidisciplinar, Barcelona, Spain

Citation: Corbella-Bagot L, Piquero-Casals J, Morgado-Carrasco D. Dermoscopic Features of Granular Cell Tumor. *Dermatol Pract Concept.* 2023;13(2):e2023084. DOI: <https://doi.org/10.5826/dpc.1302a84>

Accepted: August 22, 2022; **Published:** April 2023

Copyright: ©2023 Corbella-Bagot et al. This is an open-access article distributed under the terms of the Creative Commons Attribution-NonCommercial License (BY-NC-4.0), <https://creativecommons.org/licenses/by-nc/4.0/>, which permits unrestricted noncommercial use, distribution, and reproduction in any medium, provided the original authors and source are credited.

Funding: None.

Competing Interests: None.

Authorship: All authors have contributed significantly to this publication.

Corresponding Author: Daniel Morgado-Carrasco, Dermatology Department, Hospital Clínic de Barcelona, C/ Villarroel, 170, 08036, Barcelona, Spain. Tel: (+34) 93 227 54 00; Fax: (+34) 932275438 E-mail: morgadodaniel8@gmail.com

Case Presentation

An otherwise healthy 35-year-old male presented with a tender and fast-growing nodule on the flank, of one year of evolution. Clinical examination showed a 2 cm firm and shiny pigmented nodule. Dermoscopy revealed brown radial lines and perifollicular scaling, together with coiled and twisted hairs. Structureless pale areas were also observed (Figure 1). Histologic evaluation confirmed the diagnosis of a benign form of a granular cell tumor (GCT).

Teaching Point

GCT is an infrequent tumor usually presenting as a firm, sometimes pigmented nodule on mucosae or on the skin of the head or neck. GCT seems to originate from Schwann cells, which is supported by the expression of S-100 and myelin proteins upon immunohistochemical staining. Dermal

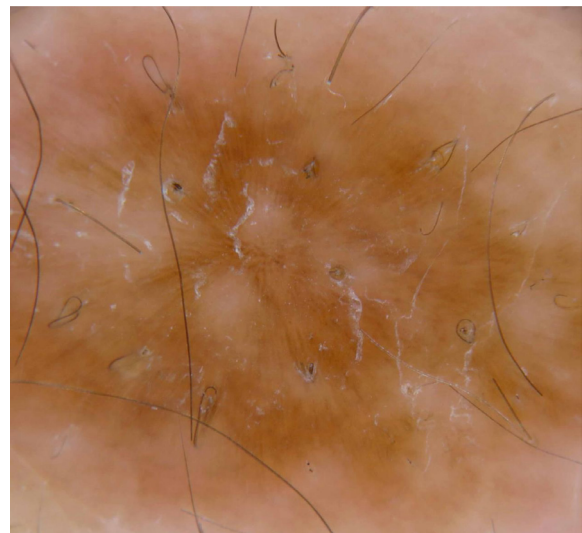


Figure 1. Dermoscopic image showing a pigmented tumor with large, radial brown lines. Perifollicular scaling, together with coiled and twisted hairs is also observed, as well as structureless pale areas.

collagen, small nerves and adnexal structures are commonly infiltrated by tumoral cells, even though only 1%-2% of GCT are malignant. Surgical excision is the recommended treatment. Very few dermoscopic reports are found in the literature. Dermoscopy of GCT can show a yellowish center (with or without hypopigmented lines), surrounded by thin brown reticular lines. Small pale circles have also been described [1,2]. Differential diagnosis of tumors presenting with brown reticular lines is broad and includes melanocytic and non-melanocytic lesions such as dermatofibroma, seborrheic keratosis, solar lentigo, cutaneous mastocytosis, supernumerary accessory nipple and syringoma [1]. We present new dermoscopic features of GCT: large, radial brown lines, and the presence of follicular involvement.

Differential diagnosis of pigmented lesions can be challenging. Dermoscopy may help to confirm suspected GCT.

A written consent form signed by the patient has been obtained.

References

1. Popadić M. Dermoscopy of cutaneous Abrikossoff tumor (granular cell tumor) in a pediatric patient. *J Am Acad Dermatol.* 2015;73(4):e137-e138. DOI: 10.1016/j.jaad.2015.06.056. PMID: 26369852.
2. Alaoui A, Douhi Z, Elloudi S, Baybay H, Mernissi F. Abrikossoff's tumor: Clinical and dermoscopic features. *J Dermatol Cosmetol.* 2019;3(5):130 DOI: 10.15406/jdc.2019.03.00129