

# Pale halo surrounding a homogeneous bluish-purplish central area: dermoscopic clue for eccrine hidrocystoma

Nilay Duman<sup>1</sup>, Deniz Duman<sup>2</sup>, Sedef Sahin<sup>2</sup>

<sup>1</sup> Afyon Kocatepe University, School of Medicine, Department of Dermatology, Afyonkarahisar, Turkey

<sup>2</sup> Acibadem University, School of Medicine, Department of Dermatology, Istanbul, Turkey

**Key words:** eccrine hidrocystoma, dermoscopy

**Citation:** Duman N, Duman D, Sahin S. Pale halo surrounding a homogenous bluish-purplish central area: dermoscopic clue for eccrine hidrocystoma. *Dermatol Pract Concept* 2015;5(4):11. doi: 10.5826/dpc.0504a11

**Received:** May 28, 2015; **Accepted:** July 13, 2015; **Published:** October 31, 2015

**Copyright:** ©2015 Duman et al. This is an open-access article distributed under the terms of the Creative Commons Attribution License, which permits unrestricted use, distribution, and reproduction in any medium, provided the original author and source are credited.

**Funding:** None.

**Competing interests:** The authors have no conflicts of interest to disclose.

All authors have contributed significantly to this publication.

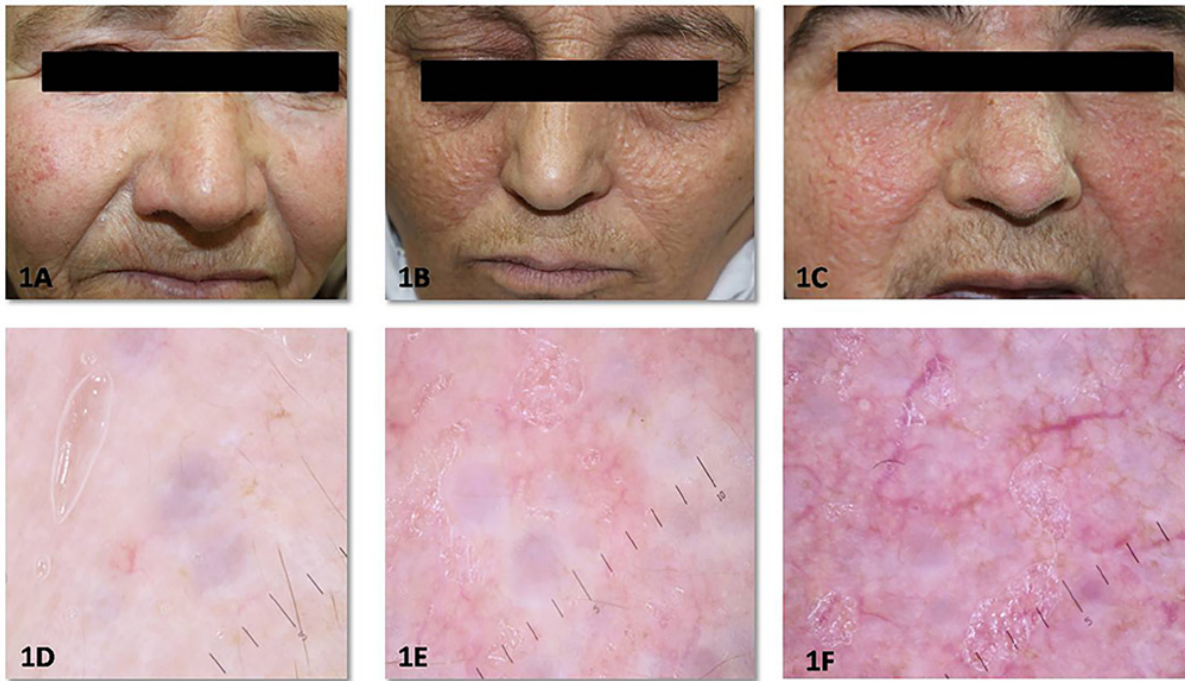
**Corresponding author:** Nilay Duman, MD, Assistant Professor, Afyon Kocatepe, University, School of Medicine, Department of Dermatology, Ali Çetinkaya Kampusü, İzmir Karayolu 7. Km, Afyonkarahisar, Turkey. Tel. +902724440304; Fax. +902722463322. Email: nilybayram@hotmail.com

**ABSTRACT** Eccrine hidrocystomas are benign tumors of the sweat glands that arise from cystic dilatation of the excretory sweat duct. Exact diagnosis requires biopsy and histopathologic examination, from which arises risk of scarring. Dermoscopy could be a useful tool in diagnosing eccrine hidrocystomas. Herein we aim to present dermoscopic features in three female patients with multiple lesions on the face consistent with eccrine hidrocystomas.

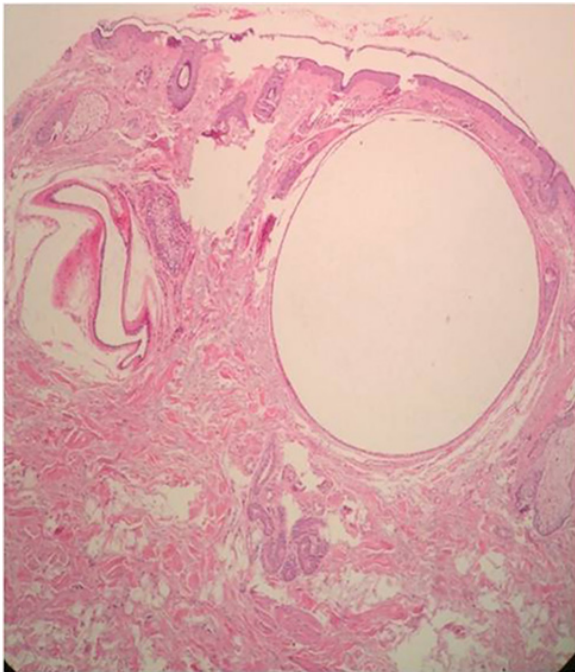
## Case presentation

Three female patients (62, 64 and 63 years old) presented with similar chronic multiple facial papules. The patients stated that the lesions aggravated in summer and upon physical exertion and regressed in cold weather. Dermatological examination revealed multiple cystic bluish-skin colored papules on bilateral cheeks (Figure 1A-C).

Non-polarized dermoscopic examination revealed well-demarcated papules characterized by a homogeneous bluish-purplish central area surrounded by a pale halo (Figure 1D-F). Histopathological examination revealed dermal cysts containing clear fluid, lined by two layers of cuboidal epithelium, which was consistent with the diagnosis of eccrine hidrocystoma (Figure 2).



**Figure 1.** Multiple eccrine hidrocystomas. Cystic bluish-skin colored papules on the face (A-C) characterized with well demarcated homogeneous bluish-purple central areas surrounded by pale halo on dermoscopy (D-F) using a Heine Delta 20 plus nonpolarized dermatoscope (Heine Optotechnik, Herrsching, Germany; original magnification:  $\times 10$ ). [Copyright: ©2015 Duman et al.]



**Figure 2.** Eccrine hidrocystoma. Dermal cysts containing clear fluid, lined by two layers of cuboidal epithelium (hematoxylin & eosin  $\times 40$ ). [Copyright: ©2015 Duman et al.]

## Conclusion

Eccrine hidrocystomas are benign tumors of the sweat glands that arise from cystic dilatation of the excretory sweat duct [1]. They typically present as multiple skin-colored to bluish cystic papules in the centrop facial area and are most commonly seen in middle-aged women [1]. Aggravation in summer, in humid environments, during exercise and other conditions that involve intense sweating is characteristic for eccrine hidrocystomas [1]. Exact diagnosis requires biopsy and histopathologic examination, from which arises risk of scarring. Considering that the patient is usually female and the localization is the central face, this is of great cosmetic concern to the patient.

The number of publications about dermoscopic features of hidrocystomas is limited in literature. Previously, Zaballos et al. reported that a skin-colored, pink, yellow or blue homogeneous area that occupies the whole lesion with arborizing vessels is the most common dermoscopic pattern associated with apocrine hidrocystomas [2]. Correia et al. defined dermoscopic features of eccrine hidrocystomas as well-demarcated, vessel-free cystic lesions [1]. In our cases, dermoscopic examination showed well-demarcated lesions with a homogeneous bluish-purple central area surrounded by a characteristic pale halo.

The primary differential diagnosis of multiple eccrine hidrocystomas on the face includes eruptive vellus hair cysts, comedonal acne, eruptive syringomas, multiple pilomatrixo-

mas and basal cell carcinomas [3,4]. Dermoscopy of vellus cysts exhibits well-demarcated round lesions characterized by light yellow-white center and erythematous halo with few irregular radiating capillaries in the periphery [3]. Dermoscopic features of comedonal acne include numerous light- and dark-brown homogenous areas with prominent keratin plugs [5]. Dermoscopy of eruptive syringomas exhibits yellowish-brownish structureless background and scarce fine linear vessels [4]. The most common dermoscopic features of pilomatricomas are irregular white and/or yellow structures, white streaks, reddish homogenous areas, linear vessels, ulceration and blue-gray areas [4,6]. Furthermore, the most common dermoscopic features of basal cell carcinomas are ulceration, multiple blue/gray globules, leaflike areas, large blue/gray ovoid nests, spoke-wheel areas, and arborizing telangiectasia [7].

In conclusion, characteristic dermoscopic features presented herein can help differentiate eccrine hidrocystoma from other clinically similar lesions located on face.

## References

1. Correia O, Duarte AF, Barros AM, et al. Multiple eccrine hidrocystomas—from diagnosis to treatment: the role of dermoscopy and botulinum toxin. *Dermatology*. 2009;219:77-9.
2. Zaballos P, Bañuls J, Medina C, et al. Dermoscopy of apocrine hidrocystomas: a morphological study. *J Eur Acad Dermatol Venereol*. 2014;28:378-81.
3. Alfaro-Castellón P, Mejía-Rodríguez SA, Valencia-Herrera A, et al. Dermoscopy distinction of eruptive vellus hair cysts with molluscum contagiosum and acne lesions. *Pediatr Dermatol*. 2012;29:772-3.
4. Lallas A, Moscarella E, Argenziano G, et al. Dermoscopy of uncommon skin tumours. *Australas J Dermatol*. 2014;55:53-62.
5. Kamińska-Winciorek G, Spiewak R. Dermoscopy on nevus comedonicus: a case report and review of the literature. *Postepy Dermatol Alergol*. 2013;30:252-4.
6. Zaballos P, Llambrich A, Puig S, et al. Dermoscopic findings of pilomatricomas. *Dermatology*. 2008; 217:225–30.
7. Altamura D, Menzies SW, Argenziano G, et al. Dermoscopy of basal cell carcinoma: morphologic variability of global and local features and accuracy of diagnosis. *J Am Acad Dermatol*. 2010;62:67-75.