



## Terra firma-forme dermatosis: A report of ten individuals with Duncan's dirty dermatosis and literature review

Tanya Greywal<sup>1</sup>, Philip R. Cohen<sup>2</sup>

<sup>1</sup> School of Medicine, University of California, San Diego, CA, USA

<sup>2</sup> Department of Dermatology, University of California, San Diego, CA, USA

**Key words:** dermatosis, Duncan's dirty dermatosis, isopropyl alcohol, terra firma, terra firma-forme

**Citation:** Greywal T, Cohen PR. Terra firma-forme dermatosis: A report of ten individuals with Duncan's dirty dermatosis and literature review. *Dermatol Pract Concept* 2015;5(3):8. doi: 10.5826/dpc.0503a08

**Received:** March 27, 2015; **Accepted:** April 9, 2015; **Published:** July 31, 2015

**Copyright:** ©2015 Greywal et al. This is an open-access article distributed under the terms of the Creative Commons Attribution License, which permits unrestricted use, distribution, and reproduction in any medium, provided the original author and source are credited.

**Funding:** None.

**Competing interests:** The authors have no conflicts of interest to disclose.

All authors have contributed significantly to this publication.

**Corresponding author:** Philip R. Cohen, MD. Email: mitehead@gmail.com

**ABSTRACT** **Background:** Terra-firma forme dermatosis, also known as Duncan's dirty dermatosis, is a benign skin condition that presents as dirt-like plaques in patients of all ages.

**Purpose:** We describe a series of ten patients that presented with terra-firma forme dermatosis.

**Methods and Materials:** We reviewed PubMed for the following terms: dermatosis, Duncan's dirty dermatosis, isopropyl alcohol, terra firma, and terra firma-forme dermatosis. We also reviewed papers containing these terms and their references.

**Results:** The diagnosis of terra firma-forme dermatosis was confirmed in all patients who had complete resolution of each lesion after the application of 70% isopropyl alcohol.

**Conclusions:** Terra-firma forme dermatosis is easily diagnosed and treated with 70% isopropyl alcohol. It is important to recognize this benign dermatologic condition since it can be confused with other cutaneous disorders. Therefore, in order to avoid unnecessary referrals, biopsies, blood tests, and medications, we suggest a trial of wiping the skin lesion with 70% isopropyl alcohol pads when the diagnosis of terra-firma forme dermatosis is considered.

### Introduction

Terra-firma forme dermatosis is a benign condition with a characteristic clinical appearance of brown or black hyperkeratotic plaques or papules. The application of 70% isopropyl alcohol is both diagnostic and therapeutic for this disorder. We describe ten patients who presented with terra-

firma forme dermatosis that usually affected skin creases and that resolved after wiping with 70% isopropyl alcohol pads.

### Case series

Terra-firma forme dermatosis was diagnosed in ten Caucasian patients whose clinical characteristics are summarized

**TABLE 1. Clinical characteristics of ten patients with terra firma-forme dermatosis [1,2]**

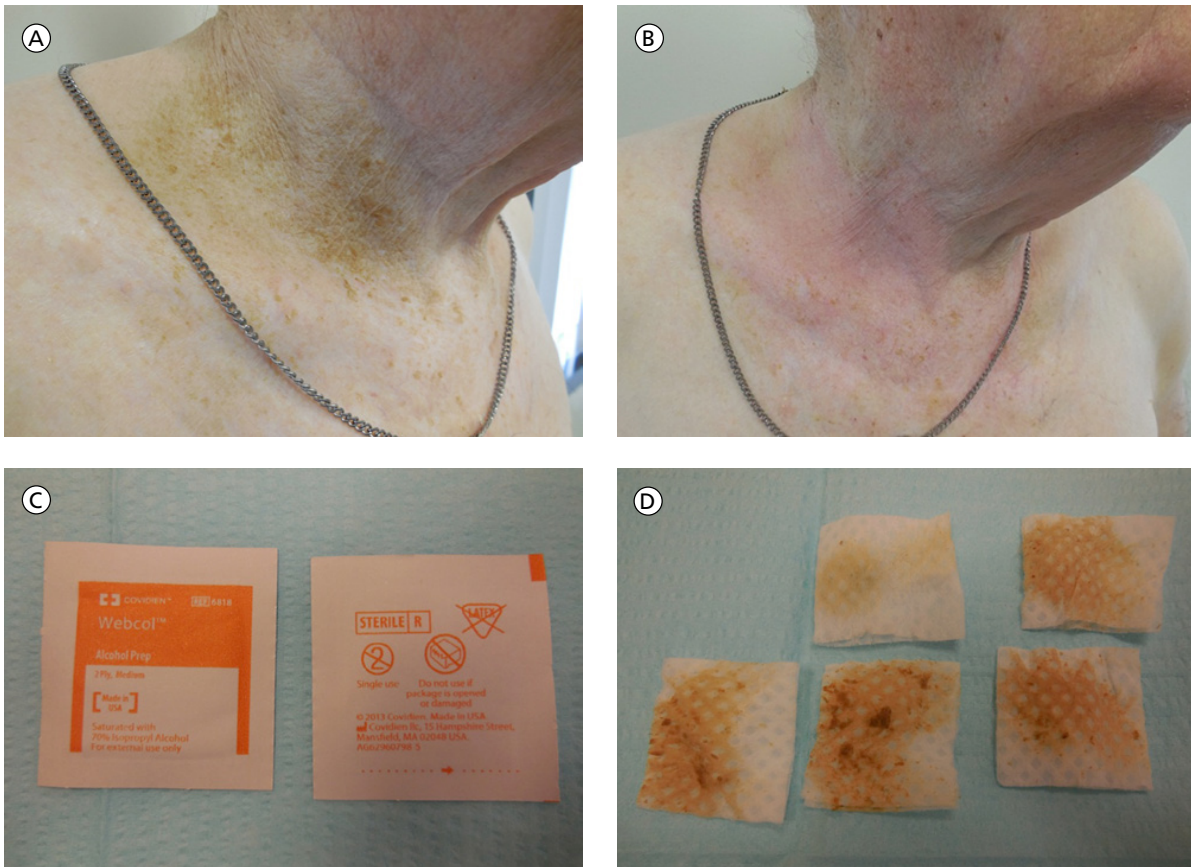
Case	Age (yrs)	Race	Sex	Location	Hx of NMSC	Other Medical Conditions
1	54	C	M	Right and left inguinal folds Right suprapubic region	No	None
2	58	C	M	All interspaces between the first through fourth toes on both feet	No	<ul style="list-style-type: none"> <li>• Addison disease</li> <li>• Chronic lymphocytic leukemia</li> <li>• Chronic inflammatory demyelinating polyneuropathy</li> <li>• Hypothyroidism</li> </ul>
3	61	C	M	Skin folds on the anterior neck	Yes: SCC	<ul style="list-style-type: none"> <li>• Atrial fibrillation</li> <li>• Coronary artery disease</li> <li>• Depression</li> <li>• Generalized anxiety disorder</li> <li>• Hypertension</li> </ul>
4	66	C	M	Concha of right ear	Yes: SCC	<ul style="list-style-type: none"> <li>• Depression</li> <li>• Hyperlipidemia</li> <li>• Hypertension</li> <li>• Narcolepsy</li> <li>• Prostate cancer</li> <li>• Urge urinary incontinence</li> <li>• Vocal cord palsy</li> </ul>
5	66	C	M	Central chest	Yes: BCC, SCC	<ul style="list-style-type: none"> <li>• Anxiety</li> <li>• Gout</li> <li>• Hypercholesterolemia</li> <li>• Hypertension</li> <li>• Insomnia</li> <li>• Macular puckering of retina</li> </ul>
6	73	C	M	Occipital scalp	No	<ul style="list-style-type: none"> <li>• Meningioma</li> </ul>
7	82	C	M	Right distal neck fold Right and central chest Left inguinal fold	Yes: BCC, SCC	<ul style="list-style-type: none"> <li>• Benign prostatic hyperplasia</li> <li>• Chronic lymphocytic leukemia</li> <li>• Hypertension</li> <li>• Obstructive sleep apnea</li> </ul>
8	82	C	M	Right and left inguinal folds	Yes: BCC	<ul style="list-style-type: none"> <li>• Coronary artery disease</li> <li>• Diverticulosis</li> <li>• Hypertension</li> <li>• Prostate cancer</li> </ul>
9	86	C	M	Right and left subclavicular chest	Yes: BCC	<ul style="list-style-type: none"> <li>• Melanoma</li> </ul>
10	59	C	W	Right chest, skin fold beneath the right breast	No	<ul style="list-style-type: none"> <li>• Anxiety</li> <li>• Asthma</li> <li>• Breast cancer</li> <li>• Hypertension</li> <li>• Hypothyroidism</li> <li>• Insomnia</li> <li>• Osteoporosis</li> </ul>

1. Abbreviations: BCC, basal cell carcinoma; C, Caucasian; Hx, history; M, man; NMSC, nonmelanoma skin cancer; SCC, squamous cell carcinoma; W, woman; yrs, years

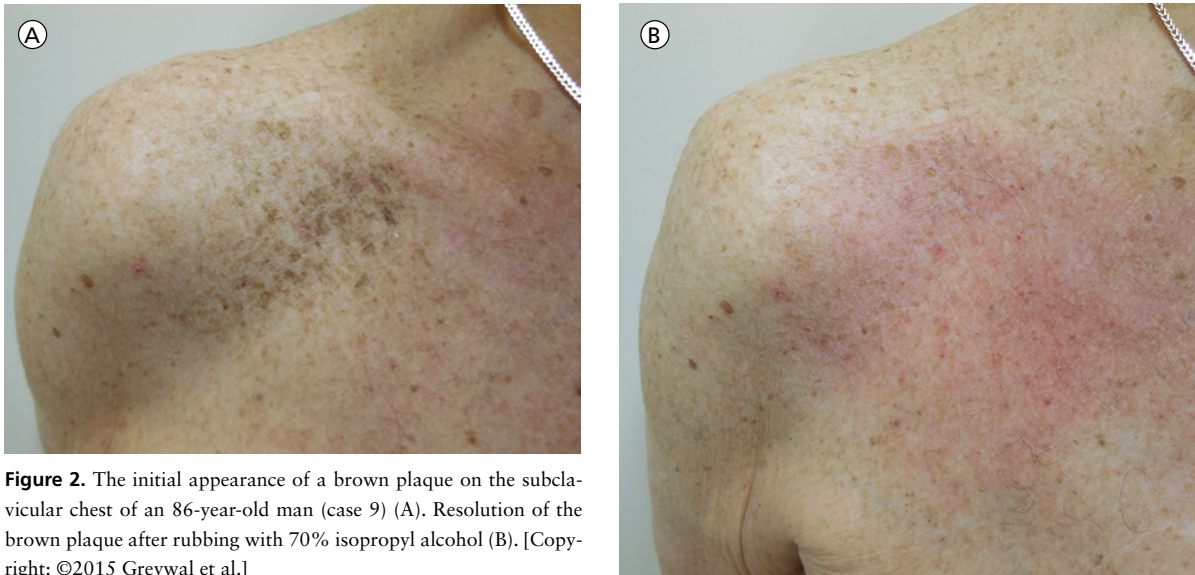2. The morphology of all lesions was similar, consisting of brown or black plaques or papules. All lesions resolved with firm application of 70% isopropyl alcohol

in Table 1. The morphology of each lesion was similar and consistent with terra-firma forme dermatosis: brown and/or black plaques or papules or both. Final diagnosis was confirmed with the resolution of each lesion after firm rubbing

with 70% isopropyl alcohol pads. Our patients included nine men and one woman. The men's ages ranged from 54 to 86 years, with a mean age of 70 years. The woman was 59 years of age. Most of the patients were unaware of their asymp-



**Figure 1.** Terra firma-forme dermatosis in an 82-year-old man (case 7). A brown plaque is present on the concave skin of the right distal neck (A). Resolution of the brown plaque after rubbing with several 70% isopropyl alcohol pads (B). The isopropyl alcohol pads before (C) and after (D) use, showing evidence of the brown pigmentation that was removed. [Copyright: ©2015 Greywal et al.]

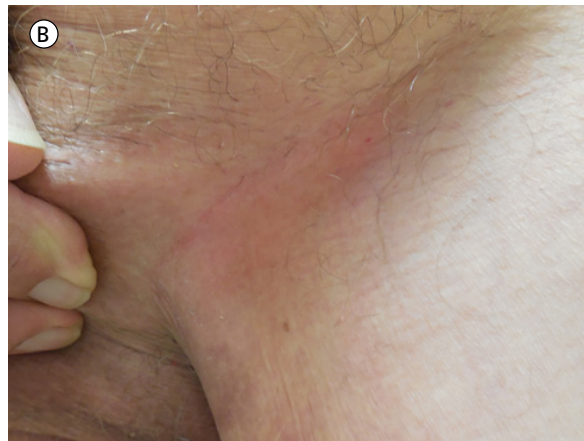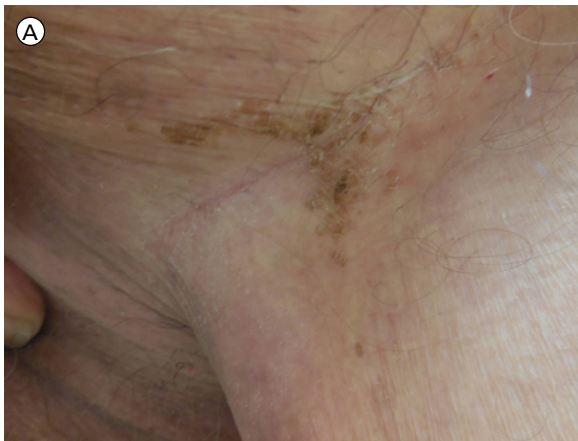


**Figure 2.** The initial appearance of a brown plaque on the subclavicular chest of an 86-year-old man (case 9) (A). Resolution of the brown plaque after rubbing with 70% isopropyl alcohol (B). [Copyright: ©2015 Greywal et al.]

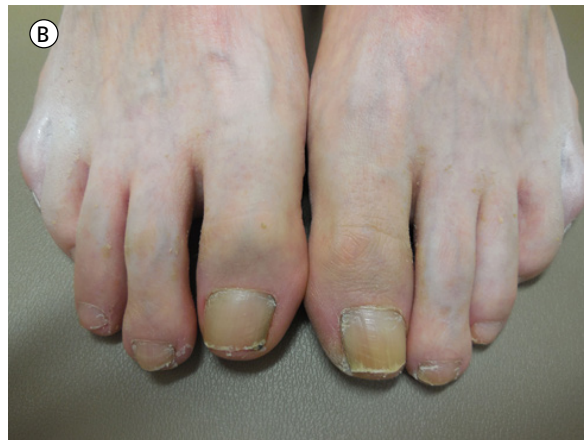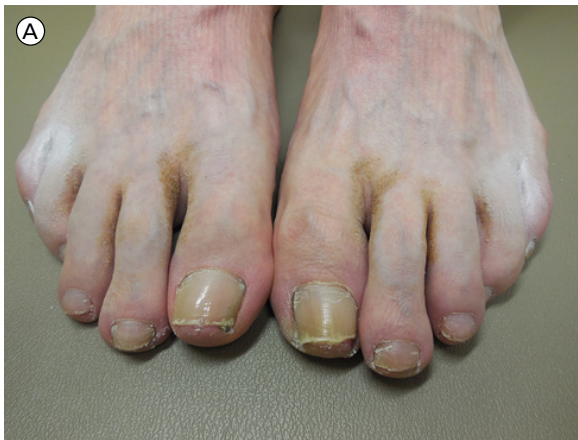tomatic dermatosis. All patients practiced good hygiene and showered a minimum of every other day or daily. In addition, with the exception of one patient (case 4), all were capable of reaching the affected locations while showering. Most of the lesions (except case 6) were located on concave sites (Figures

1 and 2) or flexor areas or skin folds (Figure 3); less common locations included in-between the toes (case 2) (Figure 4), the right ear concha (case 4) (Figure 5), and the occipital scalp (case 6). Only one patient had involvement of two distant sites, the chest and the groin (case 7). In addition, most of

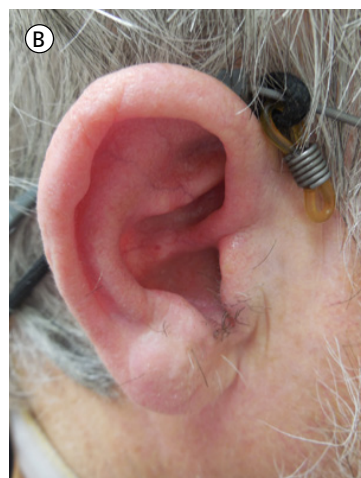
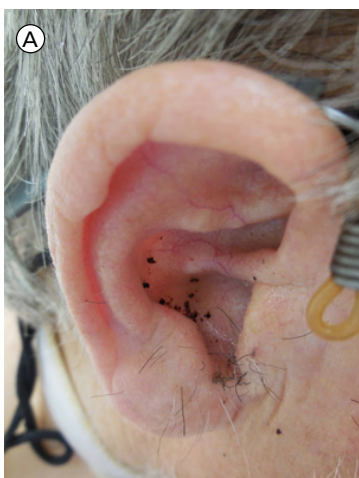


**Figure 3.** An 82-year-old man (case 8) with a hyperkeratotic brown plaque in the inguinal fold, as seen on initial presentation (A). Clearing of the lesion in the inguinal fold after aggressive wiping with 70% isopropyl alcohol pads (B). [Copyright: ©2015 Greywal et al.]



**Figure 4.** Clinical presentation of terra firma-forme dermatosis in a 58-year-old man (case 2). Brown plaques affecting the interspaces between the first through fourth toes, bilaterally (A). Clearing of terra firma-forme dermatosis after wiping with 70% isopropyl alcohol pads (B). [Copyright: ©2015 Greywal et al.]



**Figure 5.** Terra firma-forme dermatosis in a 66-year-old man (case 4). Initial presentation of black and brown papules and plaques on the concha of the right ear (A). Resolution of all pigmentation after the application of 70% isopropyl alcohol (B). [Copyright: ©2015 Greywal et al.]

the patients had other medical conditions that were most likely a reflection of their age and not a predisposing factor to terra-firma forme dermatosis. Several patients had a history of non-melanoma skin cancer (cases 3, 4, 5, 7, 8, and 9), while only one patient had a history of melanoma (case 9).

## Discussion

Terra firma-forme dermatosis is a benign condition of acquired dirt-like plaques. The name, “terra firma,” is derived from the Latin words meaning “solid land” [1,2]. It has also been referred to as Duncan’s dirty dermatosis since the condition was first described by Duncan, Tschén, and Knox in 1987 [3]. This condition affects people of all ages, with some reports of a higher incidence in children and young adults [1,3-7]. Terra firma-forme dermatosis does not

have a predilection for any particular gender, although our patients were predominantly men [4,6]. It is also unrelated to any known genetic condition or familial inheritance [8].

Terra firma-forme dermatosis usually presents as asymptomatic black or brown, dirt-like plaques [1,4,6,9,10]. It may also have a papillomatous, verrucous, or reticulate appearance [6,11]. Lesions are typically located on the neck, face, trunk, and ankles, although they may involve any area of the body [1,2,4,5,7-9]. One study observed that terra firma-forme dermatosis had a predilection for heavier patients and concave skin areas, which is consistent with the majority of our patients' presentations [12]. The distribution of terra firma-forme dermatosis varies; it can be localized, generalized, bilateral, or unilateral [4,7-9]. Lesions appear in patients with normal hygiene, yet are resistant to scrubbing with soap and water [1,3,10,11]. In addition, investigators have suggested that terra firma-forme dermatosis most often presents during the warmer months of the year [3,4].

The diagnosis of terra firma-forme dermatosis is classically based upon clinical presentation and subsequent lesion resolution after the application of 70% isopropyl alcohol [1-4,6,9,11]. Aggressive rubbing with 70% isopropyl alcohol pads is sometimes required to achieve the appropriate shearing forces to remove all pigmentation [2]. Biopsies are not frequently performed. If tissue is obtained, hematoxylin and eosin staining will show lamellar hyperkeratosis with compact orthokeratotic whorls and an absence of parakeratosis, acanthosis, papillomatosis, keratotic material between the papillae, and melanin deposition not only within the basal layer but also in the hyperkeratotic areas [1-6,8,10,11]. Numerous keratin globules can also be visualized throughout the stratum corneum with toluidine blue staining [1,2,5].

The differential diagnosis for terra firma-forme dermatosis includes acanthosis nigricans, confluent and reticulate papillomatosis, dermatosis neglecta, dirty neck syndrome of atopic dermatitis, epidermal nevi, epidermolytic hyperkeratosis, granular parakeratosis, ichthyosis, idiopathic deciduous skin, omphalith, pseudoacanthosis nigricans, seborrheic keratosis, and tinea versicolor [1-6,8-11].

The etiology of terra firma-forme dermatosis is unclear [1-5,11]. Many believe this condition is caused by delayed keratinocyte maturation, which leads to the retention of keratinocytes and melanin within the epidermis [3,4,6,8,10]. This disordered keratinocyte buildup and compaction with surrounding sebum and dirt may ultimately explain the hyperkeratosis and hyperpigmentation clinically seen in terra firma-forme dermatosis [3,8,10].

The treatment of terra firma-forme dermatosis consists of the application of 70% isopropyl alcohol; it is both diagnostic and therapeutic [1,3-5,10,11]. Occasionally, lesions may recur after the initial complete removal of all hyperpigmentation; indeed, one of our patients (case 7) developed easily treated

new lesions on his subclavicular chest within three months after the original lesions had been completely removed [2]. In this situation, additional wiping with isopropyl alcohol is recommended [2,8]. Some patients may require weekly application of isopropyl alcohol to maintain resolution or for prophylaxis [2,8]. Consistent moisturizing to the effected skin is important to prevent xerosis after regular treatments with isopropyl alcohol.

## Conclusion

Terra firma-forme dermatosis presents as asymptomatic, brown, dirt-like plaques. All of our patients presented with this typical morphology, and their lesions successfully resolved after the application of 70% isopropyl alcohol. While terra firma-forme dermatosis typically presents on the neck, face, trunk, and ankles, our patients' lesions predominantly involved skin folds. It is important to consider the possibility of this benign dermatologic condition and the many locations in which it can present since it can readily mimic other cutaneous disorders. Therefore, in order to avoid unnecessary referrals, biopsies, blood tests, and medications, we suggest a trial of wiping the skin lesion with 70% isopropyl alcohol pads when the diagnosis of terra firma-forme dermatosis is entertained.

## References

1. Akkash L, Badran D, Al-Omari AQ. Terra firma-forme dermatosis. Case series and review of the literature. *J Dtsch Dermatol Ges* 2009;7:102-7.
2. Ozturk F, Kocabas E, Ertan P, Ermertcan AT. Terra firma-forme dermatosis. *Cutan Ocul Toxicol* 2010;29:303-5.
3. Duncan WC, Tschen JA, Knox JM. Terra firma-forme dermatosis. *Arch Dermatol* 1987;123:567-9.
4. Guarneri C, Guarneri F, Cannavo SP. Terra firma-forme dermatosis. *Int J Dermatol* 2008;47:482-4.
5. Pavlovic MD, Dragos V, Potocnik M, Adamic M. Terra firma-forme dermatosis in a child. *Acta Dermatovenereol Alp Pannonica Adriat* 2008;17:41-2.
6. Berk DR, Bruckner AL. Terra firma-forme dermatosis in a 4-month-old girl. *Pediatr Dermatol* 2011;28:79-81.
7. Ratcliffe A, Williamson D, Hesselting M. Terra firma-forme dermatosis: it's easy when you know it. *Arch Dis Child* 2013;98:520.
8. Erkek E, Sahin S, Cetin ED, Sezer E. Terra firma-forme dermatosis. *Indian J Dermatol Venereol Leprol* 2012;78:358-60.
9. Berk DR. Terra firma-forme dermatosis: a retrospective review of 31 patients. *Pediatr Dermatol* 2011;29:297-300.
10. Thomas RS, Collins J, Young RJ, Bohlke A. Atypical presentations of terra firma-forme dermatosis [published online ahead of print January 30 2015]. *Pediatr Dermatol* 2015. doi: 10.1111/pde.12505.
11. Tavli YU, Mevlitoglu PI, Toy H, Unal M. Terra firma forme disease. *J Paediatr Child Health* 2012;48:1046-7.
12. Berk DR, Mutizwa MM. Comment regarding the histopathology of terra firma-forme dermatosis. *J Cutan Pathol* 2012;39:300-1.