

# Feily's method as new mode of hair grafting in prevention of scalp necrosis even in dense hair transplantation

Amir Feily<sup>1</sup>, Fatemeh Moeineddin<sup>2</sup>

<sup>1</sup> Department of Dermatology, Jahrom University of Medical Sciences, Jahrom, Iran

<sup>2</sup> Skin and Stem Cell Research Center, Tehran University of Medical Sciences, Tehran, Iran

**Key words:** scalp necrosis, hair grafting, dense hair transplantation, Feily's method

**Citation:** Feily A, Moeineddin F. Feily's method as a new mode of hair grafting in prevention of scalp necrosis even in dense hair transplantation *Dermatol Pract Concept* 2015;5(3):10. doi: 10.5826/dpc.0503a10

**Received:** February 11, 2015; **Accepted:** April 20, 2015; **Published:** July 31, 2015

**Copyright:** ©2015 Feily et al. This is an open-access article distributed under the terms of the Creative Commons Attribution License, which permits unrestricted use, distribution, and reproduction in any medium, provided the original author and source are credited.

**Funding:** This study was supported by a grant from Jahrom University of Medical Sciences, Jahrom, Iran.

**Competing interests:** The authors have no conflicts of interest to disclose.

All authors have contributed significantly to this publication.

**Corresponding author:** Amir Feily, MD, Department of Dermatology, Honari Clinic, Motahari Street, Jahrom, Iran. Email: dr.feily@yahoo.com

**ABSTRACT** Hair restoration is a safe procedure and most of its associated complications are preventable by the surgeon and/or the patient. Recipient area necrosis is rare but arises when an increased number of recipient grafts are utilized and de-vascularization of the scalp occurs. The aim of this study was to investigate and compare all cases and pictures reported in main search engines and Iranian centers of hair transplant to find the dangerous zone of necrosis and to provide a new method for prevention of necrosis. Pictorial analysis of this study revealed that the majority of necrosis (14 of 18) occurs in central region of the scalp and is inclined, particularly, to the right parietal aspect of the scalp. Accordingly, a case series was done and a new method for prevention of scalp necrosis even in dense packing transplantation was discussed.

## Introduction

Hair restoration is a safe procedure and most of its associated complications are preventable; however, they usually arise from variables that are directly controlled by the surgeon and/or the patient. Donor site adverse reactions include: scarring, keloid formation, wound dehiscence, necrosis, donor site depletion, hypoesthesia, neuralgia, arteriovenous fistula formation, telogen effluvium, infection, hiccups, pyogenic granuloma formation, and hematoma formation [1]. Recipient

site adverse reactions include poor hairline restoration, hair color mismatch, chronic folliculitis, in-grown hairs, cysts, and necrosis [1,2]. Recipient area necrosis is a rare but dangerous complication that arises when an increased number of recipient grafts are utilized and de-vascularization of the scalp occurs as a result of dense splitting of recipient skin that results in large wound areas. Although in the literature it has been mentioned that this complication is rare [1], our survey in Iran determined that many hair transplant centers face this complication but do not officially report these cases. Accord-

ingly, after describing the standard methods of prevention of scalp skin necrosis used so far, we decided to locate these cases from the literature and Iranian hair transplant centers to determine the dangerous zone in an effort to develop a method for prevention of scalp necrosis in dense packing transplantation.

**Predisposing factors of skin necrosis:** Recipient-site necrosis is a result of vascular compromise. Predisposing influence composed of patient's factors and technical factors are as follows:

- **Patient's factors:** Smoking, atrophic skin damage, diabetes mellitus, scarring of the recipient site or a history of scalp surgery [3].
- **Technical factors:** Dense packing, megasessions, large openings, use of solutions with high epinephrine concentration, and deep recipient incisions [3].

**Methods of hair grafting / hair transplantation techniques and the risk of the recipient site skin necrosis:**

- **Follicular Unit Transplantation (FUT):** The donor strip can be harvested with a knife, after the strip has been harvested, the gap can be closed either with staples or sutures. The grafts are placed into the recipient slits/holes using fine-angled forceps [4].
- **Follicular unit extraction (FUE):** FUE is a type of hair transplantation in which the method of extraction is different but implantation is the same as FUT. It is a sutureless method of hair restoration in which hair follicles are extracted from the back of the head under local anesthesia with the help of special micropunches that are then implanted in the bald area [5].
- **Automated FUE hair transplantation or S.A.F.E.R [Suction Assisted Follicular Extraction and Reimplantation]:** The FUE Matic machine (Medicamat; Malakoff, France) is an automated hair transplant machine that seeks to assist the doctor in performing a hair transplant using the FUE technique [5,6]. It claims a faster extraction rate of grafts in a limited time. However, there is greater pulling and twisting of grafts, which puts the graft at risk of damage, resulting in greater transection [5].

Notably these techniques have almost the same graft insertion but with a different donor harvesting process, and all of them have the same risk of donor site necrosis according to the above-mentioned risk factors.

## Material and methods

Our study was composed of two parts:

1. Comparing all case reports in the literature, from search engines and from hair transplant centers in Iran to determine the danger zone of the scalp.
2. Performing a case series to identify a method to decrease scalp necrosis in dense packing transplantation.

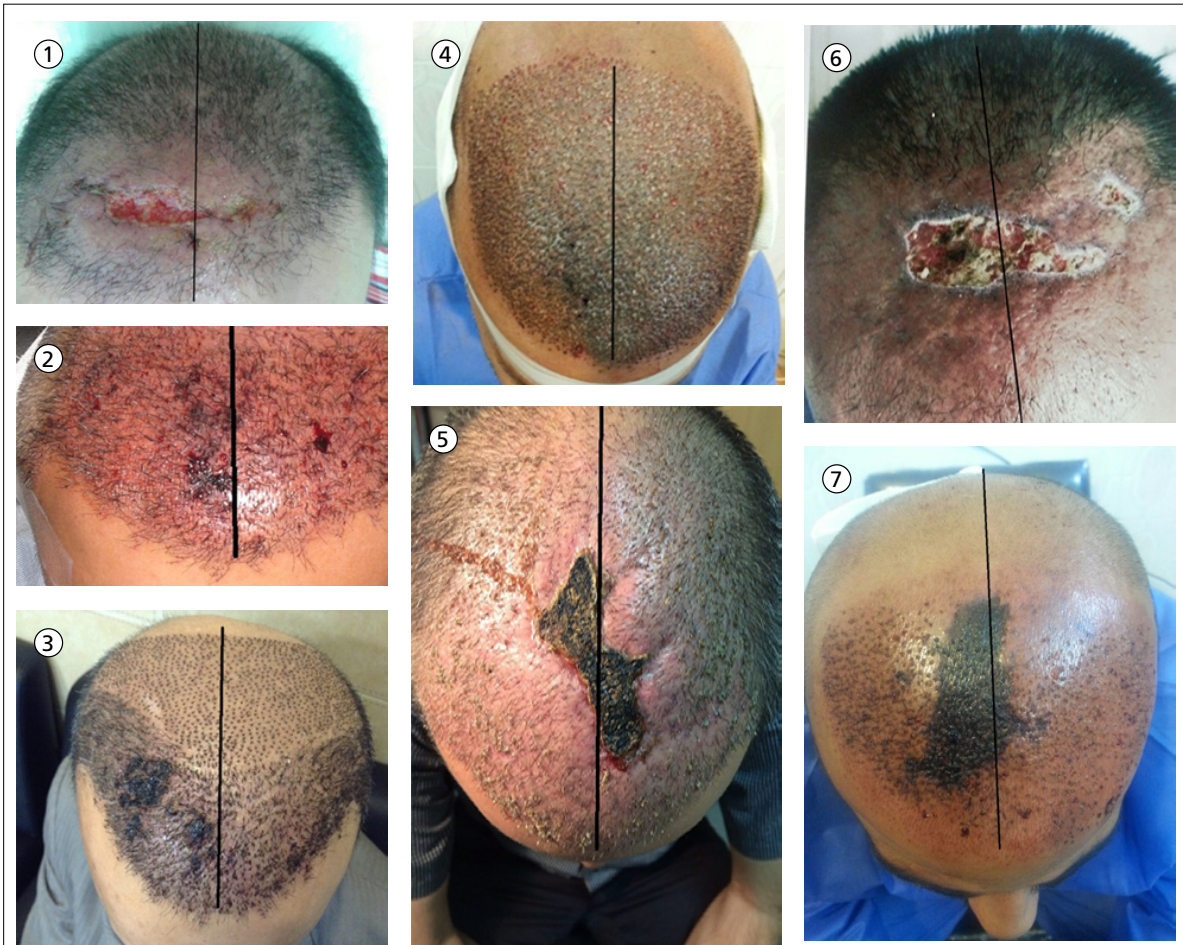
## Part 1: Determining the danger zone

The "danger zone" of scalp necrosis is the area on the scalp most vulnerable to necrosis. Interestingly there were many unofficial pictures of recipient scalp necrosis on Google and from Iranian hair transplant centers; however, we could not find even one formal case report in literature. Accordingly, we decided to determine the "danger zone" based on informal reported pictures from Google and from Iranian hair transplant centers.

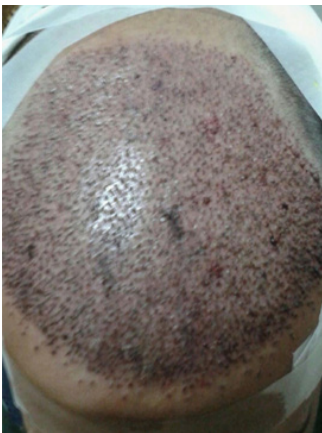An extensive literature and Google search was carried out to find out the likely sites of recipient area necrosis [7]. Eighteen pictures were found and examined, but due to copyright restrictions, we only present pictures from the Iranian hair transplant centers in this manuscript (Figures 1-9). We drew a straight line on all of the pictures from the nose to the vertex and decided to draw a line from the back of one ear to the back of the other ear allowing the scalp to be divided into four equal regions. Due to poor picture quality, we could not draw the second line on most pictures. Necrosis was compared in all of the identified pictures in which vertical division of scalp from the nose to the vertex of the scalp was conducted. Pictorial analysis revealed that most of the necrosis (14 of 18) occurred in central region of the scalp and was inclined to the right parietal region of the scalp (Figures 1-7 and 10). From others two cases occurred in central scalp without any inclination (Figure 8) and two cases occurred in central of scalp and was inclined to the left parietal region (Figure 9). Because mean velocities of blood flow do not differ significantly between the left and right hemisphere [8], it is not clear why the most of recipient scalp necrosis in our survey occurred on the right part of the central scalp region.

## Part 2

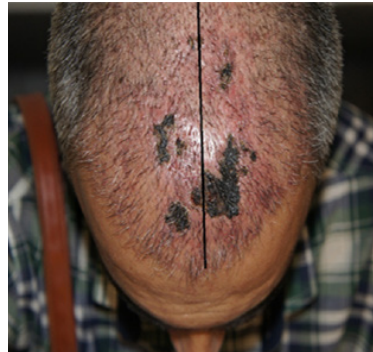We noticed that after slitting, some patients were troubled by dark areas on some parts of the recipient site. We hypothesize that the darkness can be a predisposing factor for scalp necrosis and may outline potential danger zones. Based on this information, a prospective case series was designed in which 16 consecutive patients undergoing dense slit hair transplant procedures were troubled by dark areas on the recipient site after slitting. On the first day all 16 patients underwent dense slitting in the recipient zone resulting in dark areas on the some part of scalp. In Patient 1 we put dense grafts in one dark zone and zero grafts in the other dark zone (Figure 11 A-C). After one day necrosis was evident in the region where grafts were placed but no necrosis in the non-transplanted region (Figure 12). Of note, transplantation in Patient 1 composed of slitting and hair grafting in both dangerous and non-dangerous regions on the first day with subsequent engrafting of the remaining slits on the second day (Figures 11, 12). However, in the other 15 patients,



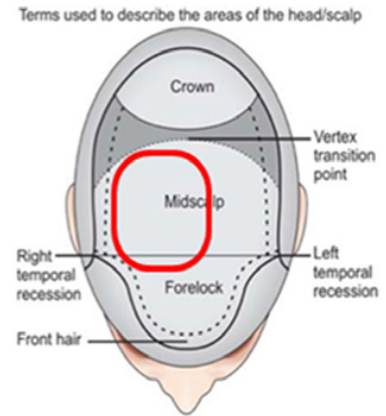
**Figures 1-7.** In the majority, necrosis occurred in the central region and was inclined to the right parietal region of the scalp. [Copyright: ©2015 Feily et al.]



**Figure 8.** Necrosis occurred in central region without any inclination. [Copyright: ©2015 Feily et al.]



**Figure 9.** Necrosis occurred central of the scalp and was inclined to the left parietal region. [Copyright: ©2015 Feily et al.]

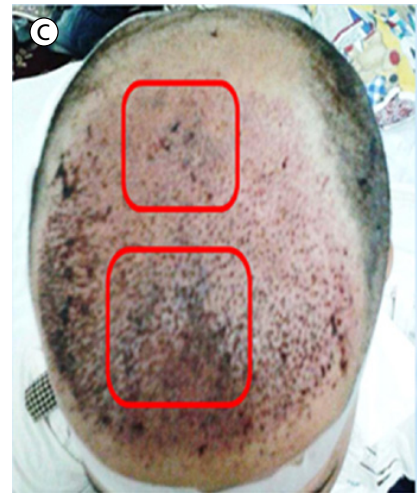
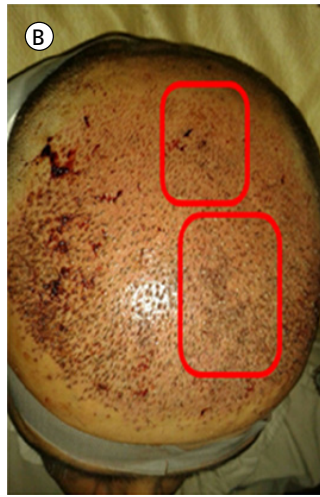
**Figure 10.** Necrosis occurred in central region and is inclined to the right parietal region of the scalp. [Copyright: ©2015 Feily et al.]

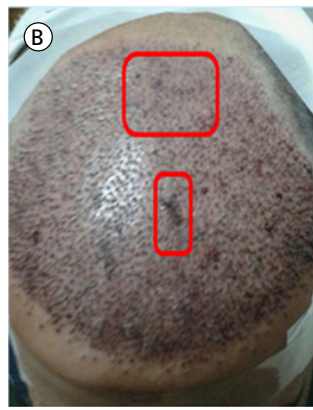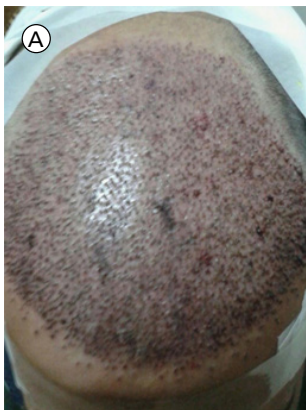transplantation on the first day composed of just slitting of the entire scalp and engraftment in the non-dangerous area in a horseshoe-shaped pattern in which the left arm was wider than the right with subsequent graft insertion of remaining slits on the second day (Figures 13-19).

## Results

Pictorial analysis in part one of this study revealed that the majority of necrosis (14 of 18) occurred in the central region of the scalp and was inclined, particularly, to the right parietal aspect of the scalp. Our experimental study determined

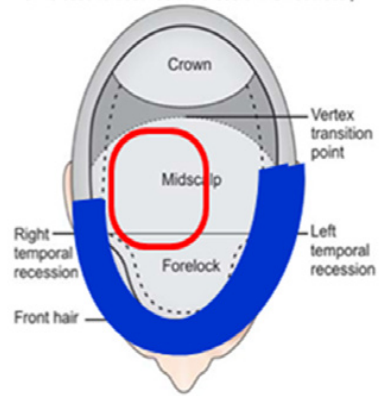


**Figure 11A-C.** putting dense grafts in one dark zone and zero grafts in the other dark zone. We enhanced the dark area for better evaluation. [Copyright: ©2015 Feily et al.]

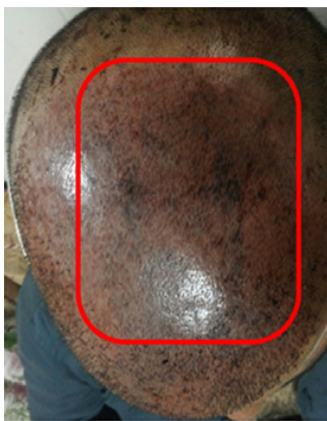

**Figure 12.** After one day necrosis was evident in the region grafts were placed with no necrosis in the non-transplanted region. [Copyright: ©2015 Feily et al.]

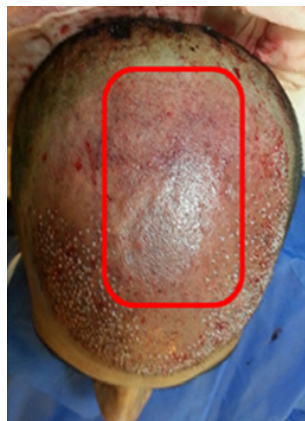Terms used to describe the areas of the head/scalp



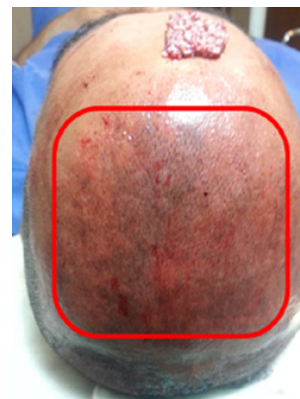
**Figure 13.** First day composed of just slitting of all of the scalp and engraftment in non-dangerous area in a horseshoe shape pattern in which the left arm was wider than the right and in the second day, grafts were placed on the remained slits. [Copyright: ©2015 Feily et al.]



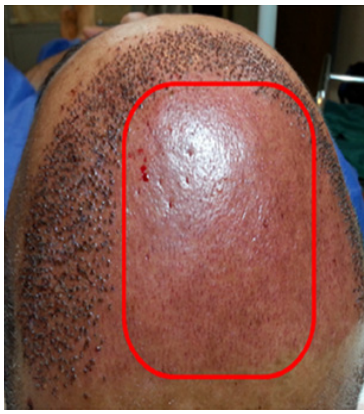**Figure 14.** First day composed of darkness after slitting and engraftment just in non-dangerous zone and letting the dark area to reperfusion at least for 24 hours. [Copyright: ©2015 Feily et al.]



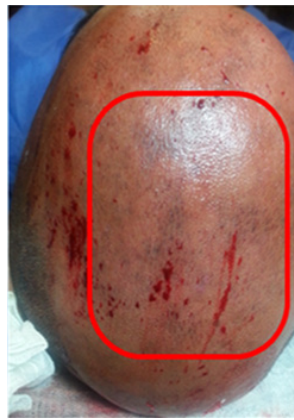**Figure 15.** Every dark area fades after 24 hours. [Copyright: ©2015 Feily et al.]



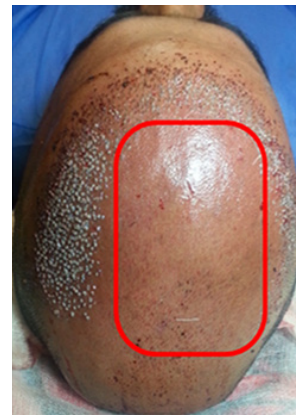
**Figure 16.** First day composed of darkness after slitting and engraftment just in non-dangerous zone and letting the dark area to reperfusion at least for 24 hours. [Copyright: ©2015 Feily et al.]



**Figure 17.** Every dark area fades after 24 hours. [Copyright: ©2015 Feily et al.]



**Figure 18.** First day composed of darkness after slitting and engraftment only in non-dangerous zone and letting the dark area to reperfusion at least for 24 hours. [Copyright: ©2015 Feily et al.]



**Figure 19.** Every dark area fades after 24 hours. [Copyright: ©2015 Feily et al.]

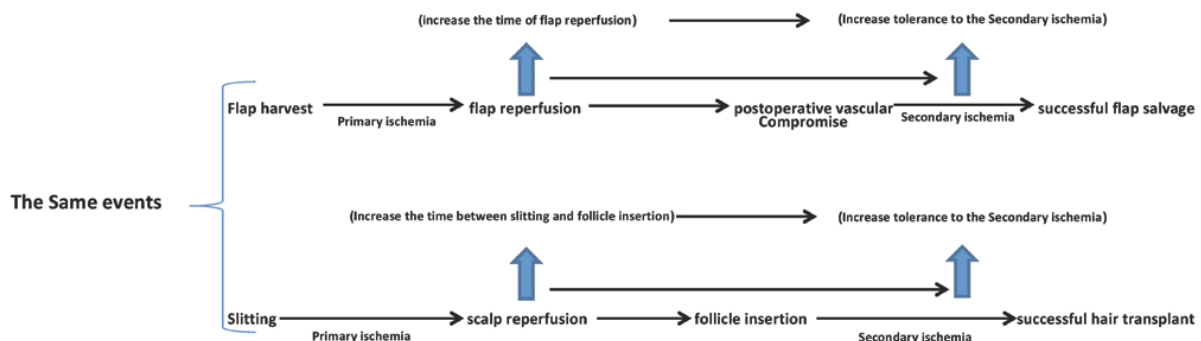
that Patient 1 had necrosis localized to the dark area that was grafted immediately following slitting without resultant necrosis in the dark area that was not grafted on the first day of transplantation (Figure 12). Interestingly there was no evidence of necrosis following engraftment on the remaining 15 patients with dark areas on the scalp after slitting, which was grafted in the dangerous zone on the second day and subsequent days after the procedure (Figures 13-19).

## Discussion

To better elucidate the chain of events, we describe some facts regarding flaps that is connected to our commentary on scalp necrosis. With regard to free tissue transfer surgery, a major problem that surgeons face is the rescuing of a flap that is at risk of failing due to ischemic complications in the postoperative period (postoperative vascular compromise leading to secondary ischemia). A study performed on mouse skin flaps subjected to combinations of primary ischemia, reperfusion,

and secondary ischemia revealed that flap survival significantly decreased due to a decreased reperfusion time (the time between primary and secondary ischemia). A longer period of primary ischemia and/or decreased reperfusion time lowers the tolerance of that flap to subsequent ischemic insults and secondary ischemia [9]. Based on this information, we could describe the ischemia timeline for the scalp in the hair transplant process.

The process is composed of three phases: primary and secondary ischemia, and reperfusion time. Dense slitting causes primary ischemia in the scalp, following which the scalp skin begins to reperfuse until engraftment. Hair follicle insertion in the slits causes secondary ischemia due to an increased demand of blood. Basically, slitting is primary ischemia, engraftment is secondary ischemia and the period of time in between these two phases of ischemia is the reperfusion time. We believe that by increasing the reperfusion time after slitting, the tolerance of scalp to secondary ischemia insult and ultimately necrosis would decrease (Table 1). Another



**Table 1.** Summary of Feily's method [Copyright: ©2015 Feily et al.]

study on flaps demonstrated that a reperfusion time of 24 hours before a complete ischemic episode had the best result in tolerance to ischemia [10]. In our study we dense-slit the scalp and put some of the grafts in the non-dangerous zone on the first day in a horseshoe pattern, and after 24 hours of reperfusion time for the dangerous zone and the other dark areas we continued to engraft the remaining slits. With this method we have not faced any recipient necrosis as of yet. If colleagues decide to graft hair follicles in one session, we recommend slitting the scalp as the first step in the session, followed by a rest period of a few hours, with subsequent engraftment because more reperfusion time would decrease the ischemic insults that most likely occur as a result of angina of the scalp skin where demand of oxygen is greater than the supply to implanted hair follicles. Based on our knowledge, this is the first study regarding the recipient scalp necrosis which compares several cases of necrosis and provides a method for prevention of this vascular catastrophe.

## Conclusion

In order to prevent development of recipient area necrosis following a hair transplant procedure, graft insertion ideally should occur 24 hours following dense slitting. In our method, we recommend dense slitting the scalp with some engraftment in the non-dangerous zones on the first day in a horseshoe pattern with a 24-hour rest reperfusion time for danger zones and other dark areas. Following this, we recommend engrafting of the slits. Adequate reperfusion time is required to allow for appropriate development of implanted hairs and prevents development of necrosis. In our experience, with this method we have performed many dense

packing hair transplantation processes without any vascular compromise.

**Acknowledgements:** A very special thanks goes to my hair transplant team: Ahmad and Arezoo Feily and Lida Daghigh for their efforts, support and participation in this study.

## References

1. Salanitri S, Goncalves AJ, Helene A Jr, Lopes FH. Surgical complications in hair transplantation: a series of 533 procedures. *Aesthetic Surg Journal*; 2009;29(1):72-6.
2. Unger W, Shapiro R, Unger R, et al. *Hair Transplantation*. 5th ed. Informa Healthcare, 2011.
3. Konior RJ. Complications to hair restoration surgery. *Facial Plast Surg Clin North Am*. 2013 Aug;21(3):505-20.
4. Khanna M. Hair transplantation surgery. *Indian J Plast Surg* 2008;41(Suppl):S56-63.
5. Dua A, Dua K. Follicular unit extraction hair transplant. *J Cutan Aesthet Surg* 2010;3(2):76-81.
6. Rassman WR. New instruments for automation. *Hair Transplant Forum Intl* 2004;14:131.
7. Google search. Recipient area necrosis after hair transplant. [https://www.google.com/search?q=recipient+area+necrosis+after+hair+transplant&biw=1366&bih=625&source=lnms&tbn=isc&sa=X&ei=ykXVMHyNoLlat7ugJgN&ved=0CAYQ\\_AUoAQ](https://www.google.com/search?q=recipient+area+necrosis+after+hair+transplant&biw=1366&bih=625&source=lnms&tbn=isc&sa=X&ei=ykXVMHyNoLlat7ugJgN&ved=0CAYQ_AUoAQ)
8. Lin TK, Ryu S, Hsu PW. Interhemispheric comparisons of cerebral blood flow velocity changes during mental tasks with transcranial Doppler sonography. *J Ultrasound Med* 2009;28(11):1487-92.
9. Babajanian M, Zhang WX, Turk JB, et al. Temporal factors affecting the secondary critical ischemia of normothermic experimental skin flaps. *Arch Otolaryngol Head Neck Surg* 1991;117(12):1360-4.
10. Angel MF, Mellow CG, Knight KR, O'Brien BM. The effect of time of vascular island skin flap elevation on tolerance to warm ischemia. *Ann Plast Surg* 1989;22(5):426-8.