

Keratotic papules of palms and soles

Vincenzo Maione¹, Giuseppe Stinco¹, Maria Orsaria², Enzo Errichetti¹

¹ Department of Experimental and Clinical Medicine, Institute of Dermatology, University of Udine, Italy

² Institute of Pathology, University of Udine, Italy

Citation: Maione V, Stinco G, Orsaria M, Errichetti E. Keratotic papules of palms and soles. *Dermatol Pract Concept* 2015;5(2):10. <http://dx.doi.org/10.5826/dpc.0502a10>

Copyright: ©2015 Maione et al. This is an open-access article distributed under the terms of the Creative Commons Attribution License, which permits unrestricted use, distribution, and reproduction in any medium, provided the original author and source are credited.

Corresponding author: Vincenzo Maione, MD, Institute of Dermatology, University of Udine, Ospedale San Michele, Piazza Rodolone, 1, 33013-Gemona del Friuli (Udine), Italy. Tel. +39 0432989378; Fax. +39 0432989209. E-mail: maionevincenzo@gmail.com

The patient

A 40-year-old white Caucasian woman presented with a 20-year history of asymptomatic lesions on palmoplantar regions. Physical examination revealed numerous keratotic papules with crateriform holes on the palms (Figure 1) and yellow pits over the areas of soles exposed to pressure (Figure 2). Her father reported the same skin signs but he was less severely affected. The patient displayed no systemic symptoms and chest x-ray and routine laboratory testing showed no alteration. No arsenic exposure was reported. Skin biopsy obtained from a lesion revealed marked orthokeratotic hyperkeratosis with hypergranulosis (Figure 3).

What is your diagnosis?

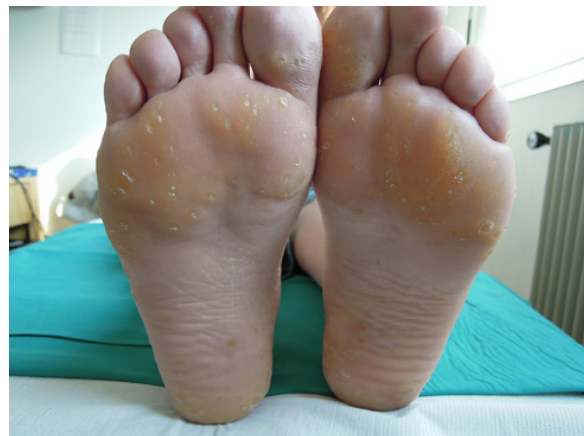

Figure 2. Numerous depressed pits of different sizes on the soles. [Copyright: ©2015 Maione et al.]

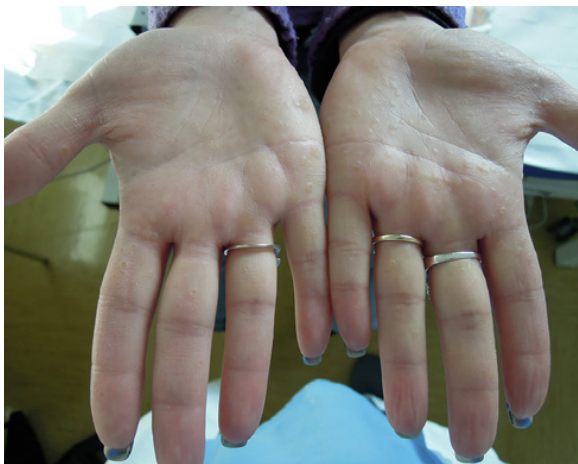

Figure 1. Multiple keratotic crateriform papules over the palms. [Copyright: ©2015 Maione et al.]

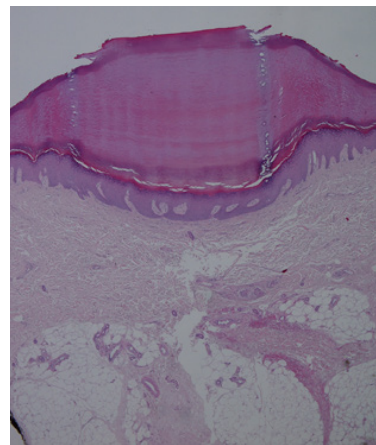


Figure 3. Epidermal depression with hypergranulosis and marked orthokeratotic hyperkeratosis (H & E, magnification 2x). [Copyright: ©2015 Maione et al.]

Diagnosis

Buschke-Fischer-Brauer keratoderma (BFBK)

Discussion

In 1910, Buschke and Fischer described a keratinization disorder with palmoplantar localization and named it “keratoderma maculosa disseminata palmaris et plantaris.” In 1913 Brauer demonstrated the genetic origin of disease. BFBK is an autosomal dominant condition with late adolescence onset and an incidence rate of 1.7/100000/year [1]. This disease has an important genetic heterogeneity. Two candidate regions were mapped: one on chromosome 15q22-24, where studies found mutations in AAGAB gene [2], and the other on chromosome 8q24.13-q24 [3]. BFBK is not associated with systemic illness, but recent reports signal an association with early- and late-onset malignancies.

Clinically, numerous yellow-brown papules and small, depressed pits occur on palms and soles. The papules frequently lose their keratotic plugs leaving crateriform holes. Lesions are usually asymptomatic, but pain and tenderness are occasionally reported.

The histology results aspecific with circumscribed, massive orthokeratotic hyperkeratosis, depression of the underlying malpighian layer and devoid of dermic inflammation. Hypergranulosis may be found. The differential diagnosis of BFBK includes verruca vulgaris, arsenic keratosis, palmoplantar porokeratosis, porokeratotic keratoderma, acrokeratoelastoidosis, focal acral hyperkeratosis and degenerative collagenous plaques of hands. Arsenic keratosis is characterized by mild-to-moderate keratinocyte dysplasia, and the presence of koilocytes is the histological hallmark of verruca vulgaris. The differential diagnosis between BFBK, palmoplantar porokeratosis and porokeratotic keratoderma results more difficult. In porokeratotic keratoderma, the parakeratotic column above the orthokeratotic stratum corneum is similar to cornoid lamella but there is no evidence of dyskeratosis, vacuolated keratinocytes, or lymphocytic inflammation of the papillary dermis, as in porokeratosis [4]. Marginal papular acrokeratoderma (acrokeratoelastoidosis and focal acral hyperkeratosis) differs from BFBK because

of the presence of hyperkeratotic polygonal papules on dorsum and lateral aspects of hands and feet. The histological features are pronounced orthohyperkeratosis and hyalinized and homogenous collagen, with the presence of elastorrhexis in acrokeratoelastoidosis, which is absent in focal acral hyperkeratosis [5]. Degenerative collagenous plaques of hands instead affect sun-damaged skin with symmetrical papules and plaques clustered on thumb, first web space and side of index finger. This disease is characterized by the presence of hyperkeratosis associated with a thickened and distorted collagen zone with fragmentation of elastic fibers [6]. It is always important to keep in mind Darier’s disease, nevoid basal cell carcinoma syndrome, Cowden’s disease, porokeratotic eccrine ostial and dermal duct nevus, Cole disease (guttate hypopigmentation with punctate keratoderma) and Cantú syndrome.

Treatment is symptomatic, and the principal aim is to reduce hyperkeratosis. Topical (urea, salicylic acid, retinoids) [7] and systemic (acitretin and alitretinoin) [8] therapies have been used widely, with variable results.

References

1. Oztas P, Alli N, Polat M, et al. Punctate palmoplantar keratoderma (Brauer-Buschke-Fischer Syndrome). *Am J Clin Dermatol* 2007;8(2):113-6.
2. Giehl KA, Eckstein GN, Pasternack SM, et al. Nonsense mutations in AAGAB cause punctate palmoplantar keratoderma type Buschke-Fischer-Brauer. *Am J Hum Genet* 2012;91(4):754-9.
3. Zhang, XJ, Li M, Gao TW, et al. Identification of a locus for punctate palmoplantar keratodermas at chromosome 8q24.13-8q24.21. *J Invest Derm* 2004;122(5):1121-5.
4. Alikhan A, Burns T, Zargari O. Punctate porokeratotic keratoderma. *Dermatol Online J* 2010;16(1):13.
5. Meziane M, Senouci K, Ouidane Y, et al. Acrokeratoelastoidosis. *Dermatol Online J* 2008;14(9):11.
6. Abulafia J, Vignale, RA. Degenerative collagenous plaques of the hands and acrokeratoelastoidosis: pathogenesis and relationship with knuckle pads. *Int J Dermatol* 2000;39(6):424-32.
7. Kong MS, Harford R, O’Neill JT. Keratosis punctata palmoplantaris controlled with topical retinoids: a case report and review of the literature. *Cutis* 2004;74(3):173-79.
8. Raone B, Raboni, Patrizi A. Alitretinoin: a new treatment option for hereditary punctate palmoplantar keratoderma (Brauer-Buschke-Fischer syndrome). *J Am Acad Dermatol* 2014;71(2):e48-9.