



Acantholytic dyskeratotic acanthoma: case report and review of the literature

Alina Goldenberg¹, Robert A. Lee^{2,3}, Philip R. Cohen²

1 Medical School, University of California San Diego, California, USA
2 Division of Dermatology, University of California San Diego, California, USA
3 Dermatopathology, University of California San Diego, California, USA

Keywords: acantholysis, acanthoma, cutaneous, dyskeratosis, nail, warty

Citation: Goldenberg A, Lee RA, Cohen PR. Acantholytic dyskeratotic acanthoma: case report and review of the literature. *Dermatol Pract Concept*. 2014;4(3):3. <http://dx.doi.org/10.5826/dpc.0403a03>

Received: February 15, 2014; **Accepted:** March 19, 2014; **Published:** July 31, 2014

Copyright: ©2014 Goldenberg et al. This is an open-access article distributed under the terms of the Creative Commons Attribution License, which permits unrestricted use, distribution, and reproduction in any medium, provided the original author and source are credited.

Funding: None.

Competing interests: The authors have no conflicts of interest to disclose.

All authors have contributed significantly to this publication.

Corresponding author: Philip R. Cohen, MD. University of California, San Diego, California, USA. Email: mitehead@gmail.com

ABSTRACT **Background:** Focal acantholytic dyskeratosis has been described as an incidental finding and as a clinically distinct lesion. In both situations, a dimorphic histologic pattern is observed: acantholysis and dyskeratosis. Solitary, non-genital lesions displaying such pathology have been difficult to classify. Clinical and pathological characteristics of acantholytic dyskeratotic acanthomas are described.

Methods: The features of a patient with solitary, non-genital, acantholytic dyskeratotic acanthoma are presented and the literature on acantholytic dyskeratotic acanthomas is reviewed. Using PubMed the following terms were searched and relevant citations assessed: acantholysis, acanthoma, cutaneous, dyskeratosis, nail, warty.

Results: We identified 30 cutaneous acantholytic dyskeratotic acanthomas, including our patient, most often found on the trunk and mimicking basal cell carcinoma, and three subungual acantholytic dyskeratotic acanthomas of the thumb, which mimicked onychopapilloma.

Conclusion: Acantholytic dyskeratotic acanthomas are clinically and pathologically distinct lesions, which may morphologically present as either truncal plaques or subungual longitudinal erythronychia.

Introduction

The incidental finding of focal acantholytic dyskeratosis, first described by Ackerman, is a common occurrence [1-4]. “Papular acantholytic dyskeratoma” has been used to describe a solitary lesion on the lip [5], whereas, “papular acantholytic dyskeratosis” has been used to describe numerous lesions of genital location [6-16].

However, non-genital lesions characterized by acantholysis and dyskeratosis have been difficult to properly identify and interpret. Solitary, non-genital lesions with prominent acantholysis and dyskeratosis without cup-shaped architecture or follicular involvement have been described as a distinct histologic entity: acantholytic dyskeratotic acanthoma [17,18]. We present a patient who developed an acantholytic

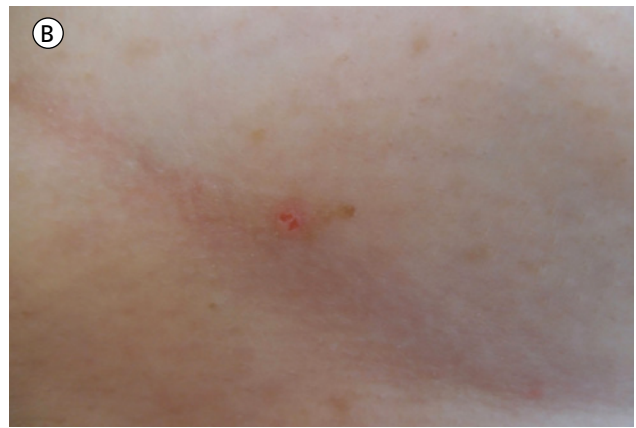
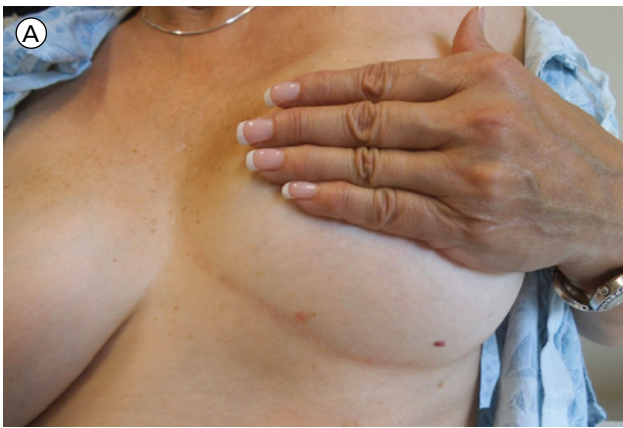
Figure 1. Distant (A) and closer (B) views of an acantholytic dyskeratotic acanthoma. The lesion appears as an erythematous plaque with central area of erosion. [Copyright: ©2014 Goldenberg et al.]

dyskeratotic acanthoma and summarize the acantholytic dyskeratotic acanthomas (30 cutaneous and 3 subungual) that have been described in literature during the past 30 years.

Case report

A 72-year-old white woman presented for evaluation of a painful lesion beneath her left breast. It appeared three months earlier as a non-healing, tender, raised area with central erosion. She had no personal or family history of keratosis follicularis (Darier's disease), transient acantholytic dermatosis (Grover's disease), non-melanoma skin cancer or melanoma.

Cutaneous examination revealed a 10 x 4 mm plaque beneath the left breast (Figure 1). A 3 x 3 mm erosion was present in the center of the lesion. An excisional biopsy was performed.

Microscopic examination showed acanthosis with focal parakeratosis and dyskeratosis. Focal areas of acantholysis, involving all layers of the epidermis, were also observed. In the dermis, there was mild superficial perivascular lymphocytic

inflammation (Figure 2). Correlation of the clinical presentation and pathologic findings established the diagnosis of an acantholytic dyskeratotic acanthoma. The entire lesion had been removed during the biopsy. The biopsy site healed by second intention and her symptoms resolved spontaneously.

Discussion

History

Focal acantholytic dyskeratosis was first coined by Ackerman in 1972 in an attempt to describe a distinctive histologic pattern with parakeratotic hyperkeratosis, acantholytic dyskeratosis (at all levels of the epidermis), and focal suprabasilar clefts. He classified the lesions by size, number (single or multiple), and duration (persistent and transient) leading to six distinct classes: (1) incidental, (2) multiple lesions (Darier's disease), (3) nodular with follicular involvement (wartlike dyskeratoma), (4) papular, (5) systematized, and (6) transient (Grover's disease). The majority of his patients had lesions that were similar to those subsequently observed, clinically unapparent and histologically incidental (3).

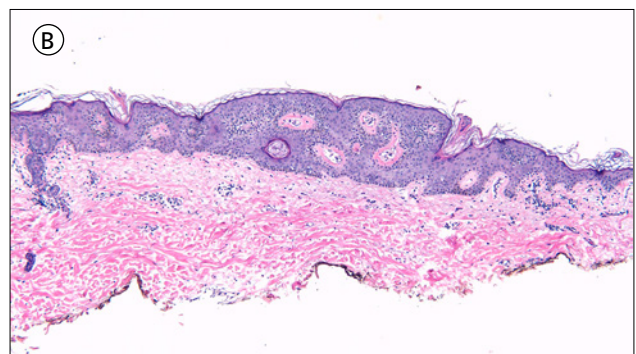
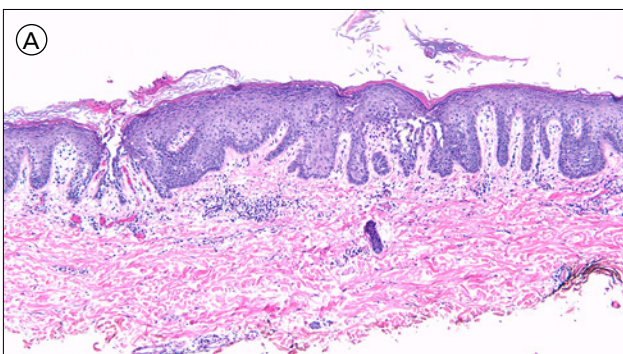


Figure 2. (A) At low magnification, one portion of the lesions shows mild thickening of the epidermis with focal areas of acantholysis involving all layers of the epidermis; there is overlying parakeratosis and focal dyskeratosis. Another portion of the same lesion (B) shows basket weave orthokeratosis, acanthosis, and horn pseudocyst formation (hematoxylin and eosin A, x10; b, x10). [Copyright: ©2014 Goldenberg et al.]

Two patients with the papular subtype of focal acantholytic dyskeratosis, diagnosed as seborrheic keratosis and basal cell carcinoma, appeared to have features that are similar to those now established as acantholytic dyskeratotic acanthomas [1]. Subsequently, Omulecki et al. described a patient who had a single plaque with bimodal histology of acantholysis and dyskeratosis, and introduced the term acantholytic dyskeratotic acanthoma [18]. Thereafter, Ko et al. did a retrospective study and described 28 patients who had a solitary, non-genital lesion with acantholysis and dyskeratosis; however, the lesion did not have a cup-shaped, cystic architecture or follicular involvement [17].

Nail findings of focal acantholytic dyskeratosis were first described by Isonokami and Higashi in the Japanese literature in 1990 [19]. However, it was not until nearly two decades later that Sass et al. reported 3 patients with acantholysis and dyskeratosis of the thumb nail bed epithelium as acantholytic dyskeratotic acanthoma [20].

There is currently neither a world health organization statement nor an agreement in explicative dermatopathology whether acantholytic dyskeratotic acanthoma is a distinct entity. Indeed, in Lever's histopathology textbook acantholytic dyskeratosis is described as a phenomena and not a separate entity [21]. In contrast, in Weedon's latest textbook some authors consider cutaneous acantholytic dyskeratotic acanthoma to be a separate entity, which usually clinically presents as a basal cell carcinoma [22]. We concur with Ko et al. that cutaneous acantholytic dyskeratotic acanthoma is a separate entity with a distinctive clinical morphology and corresponding pathologic features.

Epidemiology

Our review includes 30 patients with cutaneous acantholytic dyskeratotic acanthoma and 3 patients with subungual acantholytic dyskeratotic acanthoma (Table 1) [1,17-20,23]. Their onset age ranged from 39 years to 84 years with a median of 54 years. Cutaneous acantholytic dyskeratotic acanthoma is more common in women, whereas subungual acantholytic dyskeratoma is more common in men. The ratio of women to men who had cutaneous acantholytic dyskeratotic acanthomas was 3:2. In contrast, the ratio of women to men with subungual acantholytic dyskeratotic acanthoma was 1:2.

Clinical presentation

The cutaneous lesions were between 2-9mm, with a median size of 5mm. They presented as flesh colored, red papules or plaques. The most common location (83%, 25 of 30) was the trunk; the other site included the extremities (17%, 5 of 30). All of the subungual lesions presented with monodactylous, solitary longitudinal erythronychia of the thumbnail. The solitary red band extended from the matrix to the distal part of the nail apparatus.

Pathology

Three histopathologic patterns of cutaneous acantholytic dyskeratotic acanthoma were observed. Confluent acantholytic dyskeratosis affecting the entire thickness of the epidermis was noted in 19 patients [17]. Confluent acantholytic dyskeratosis localized only to the granular and corneal layer of the epidermis was observed in 3 patients [17]. Non-confluent focal sites of acantholytic dyskeratosis were present in 8 of the patients, including the patient reported herein and by Omulecki et al [18]. Specifically, our patient had two foci of intra-epidermal acantholysis with overlying parakeratosis and focal dyskeratosis; focal horn cyst formation was also noted. In addition, she had mild perivascular lymphocytic inflammation in the dermis.

Differential diagnosis

Clinical

Multiple clinical diagnoses were often submitted with the skin biopsy specimen. The most common clinical diagnoses of cutaneous acantholytic dyskeratotic acanthoma were either a nonmelanoma skin cancer (basal cell carcinoma in 15 patients or squamous cell carcinoma in 9 patients) or an actinic keratosis (5 patients). Less common diagnoses were seborrheic keratosis (3 patients), nevus (2 patients), or wart (2 patients).

Onychopapilloma, which can morphologically present as a monodactylous single red band, was the suggested diagnosis, prior to biopsy, in the 3 patients with subungual acantholytic dyskeratotic acanthoma. Other diagnoses of longitudinal erythronychia included glomus tumor, malignant neoplasms (such as melanoma and squamous cell carcinoma), and warty dyskeratoma [24].

Pathological

The co-existence of acantholysis and dyskeratosis is present in a few distinct conditions. Keratosis follicularis (Darier's disease) has focal orthokeratotic plugs, full epidermal acantholysis leading to the formation of suprabasal clefts (lacuna), and corneal and granular dyskeratosis (corps ronds and grains) [25]. Transient acantholytic dermatosis (Grover's disease) also can present with a "Darier's pattern" of acantholysis and dyskeratosis [26]. Warty dyskeratoma typically has a cup-shaped invagination into underlying dermis and follicular involvement; in addition to clefting and corps ronds, prominent villi may also be observed [27]. Table 2 summarizes the pathologic features that can differentiate acantholytic dyskeratotic acanthoma from warty dyskeratoma [17,18,27].

The absence of dyskeratosis permits differentiation of acantholytic dyskeratotic acanthoma from an acantholytic acanthoma. The absence multi-nucleated epidermal giant cells in acantholytic dyskeratotic acanthoma differentiates it from

TABLE 1. Clinical and pathologic characteristics of acantholytic dyskeratotic acanthoma^a
 [Copyright: ©2014 Goldenberg et al.]

Category	Cutaneous (17,18, CR)	Subungual (20)
Number	30 ^b	3 ^c
Age: range/median	39-84/ 54	12-53/ 15
F:M	3:2	1:2
Location		
. Trunk	25	
. Extremities	5	
. Thumb		3
Size: range/ median (mm)	2-9/ 5	3-5/4
Morphology		
. Papule ^d	10	
. Plaque ^e	20	
. Median longitudinal. . . hemorrhage, onycholysis		3
Histopathology		
. Confluent ^f	19	3 ^g
. Confluent, GC ^h	3	
. Focal ⁱ	8	
Clinical differential ^j		
. BCC	15	
. SCC	9	
. AK	5	
. SK	3	
. Nevus	2	
. Wart	2	
. Onychopapilloma	1	3
Treatment		
. Excision	30	3

[a] Abbreviations: AK, actinic keratosis; BCC, basal cell carcinoma; CR, current report; F, female; GC, granular and corneal layers; M, male; SCC, squamous cell carcinoma; SK, seborrheic keratosis

[b] Two patients with solitary papules with focal acantholytic dyskeratosis described by Ackerman [1] and one patient described by Barnette and Cobb [21] with a solitary acantholytic acanthoma with mild dyskeratosis reported in the literature prior to the establishment of acantholytic dyskeratotic acanthoma yet showing some of the features observed in this lesion, have not been included in the table [12]

[c] One patient with focal acantholytic dyskeratosis of the nail unit described by Isonokami and Higashi [19], reported in the literature prior to the establishment of acantholytic dyskeratotic acanthoma yet sharing some of the features observed in this lesion has not been included in the table

[d] Papule: the lesion is less than 5 mm

[e] Plaque: the lesion is greater than or equal to 5 mm

[f] Confluent: epidermis with acanthosis and confluent acantholytic dyskeratosis involving multiple levels of epidermis

[g] Epidermal acanthosis with subungual hyperkeratosis lifting nail plate (parakeratosis with neutrophils); many suprabasal acantholytic clefts and dyskeratotic cells (corps ronds and grains)

[h] GC: epidermis with acanthosis and confluent acantholytic dyskeratosis present mostly in the granular and corneal layers

[i] Focal, discrete foci of acantholytic dyskeratosis

[j] Total number may exceed number of patients due to multiple clinical differential diagnoses per each individual

TABLE 2. Comparison of morphology and histology of acantholytic dyskeratotic acanthoma to warty dyskeratoma [Copyright: ©2014 Goldenberg et al.]

Category	ADA	WD
Morphology		
Papule	+	+
Plaque	+	-
Histology		
Cup-shaped	-	+
Follicular	-	+

[a] Abbreviations: ADA, acantholytic dyskeratotic acanthoma; WD, warty dyskeratoma; +, present; -, absent

herpes simplex and varicella-zoster skin lesions [6]. Incidental acanthosis or dyskeratosis may be occasionally noted in an actinic keratosis, basal cell carcinoma, or squamous cell carcinoma; however, the absence of nuclear atypia differentiates acantholytic dyskeratotic acanthoma from those conditions.

In contrast to acantholytic dyskeratotic acanthoma, subungual warty dyskeratoma has a prominent papillomatous pattern; also, the acantholysis and dyskeratosis occur within a crater-like shape [28].

Pathogenesis

Currently the pathogenesis of acantholytic dyskeratotic acanthoma remains to be established. None of the patients had family history of keratosis follicularis (Darier's disease); however, specific genetic studies had not been performed. Testing for ATP2A2 gene mutations is an emerging diagnostic tool for the distinction between Darier's and Grover's diseases [4,29]. Evaluating for mutations in this gene may be useful in further elucidating the developmental pathway of acantholytic dyskeratotic acanthoma in patients with cutaneous or subungual lesions.

Treatment

All cutaneous and subungual lesions were completely excised. Our patient's lesion was entirely excised at the time of biopsy and healed without evidence of recurrence at the subsequent visit.

Conclusion

The term focal acantholytic dyskeratosis was originally used to describe incidental lesions with acantholysis and dyskeratosis; however, when these findings occur as a distinct, non-genital lesion of the skin or under the nail, we concur

with current nomenclature of acantholytic dyskeratotic acanthoma. Specifically, we consider acantholytic dyskeratotic acanthoma to be a clinically and pathologically distinct lesion, which may morphologically present as either truncal plaques or subungual longitudinal erythronychia. Our patient was a 72-year-old woman with a non-healing eroded plaque underneath the breast. In our review of the literature, we were able to find 30 patients whose skin lesions presented as solitary, non-genital plaque, usually between 5 mm to 1 cm in size. Cutaneous acantholytic dyskeratotic acanthoma most commonly occurred on the trunk of women. We also found 3 patients (2 men and 1 woman) with subungual acantholytic dyskeratotic acanthoma of the thumb. Clinically, cutaneous acantholytic dyskeratotic acanthoma most resembled a nonmelanoma skin cancer or actinic keratosis and subungual acantholytic dyskeratotic acanthoma was suspected to be an onychopapilloma. Three histological patterns of acantholytic dyskeratotic acanthoma were described: (1) confluent acantholytic dyskeratosis involving all layers of the epidermis seen in 19 patients, (2) confluent acantholytic dyskeratosis within granular and corneal layers seen in 3 patients, and (3) focal acantholytic dyskeratosis seen in 8 patients. The pathologic differential diagnosis of acantholytic dyskeratotic acanthoma includes Darier's disease, Grover's disease, and warty dyskeratoma; however, acantholytic dyskeratotic acanthoma can be differentiated from the solitary warty dyskeratoma by the absence of cup-shaped architecture and the absence of follicular involvement. The pathogenesis of acantholytic dyskeratoma remains to be discovered and excision appears to be the definitive treatment. Acantholytic dyskeratotic acanthoma may be more common than noted in the literature.

References

1. Ackerman AB. Focal acantholytic dyskeratosis. *Arch Dermatol.* 1972;106:702-6.
2. Bogle MA, Cohen PR, Tschen JA. Trichofolliculoma with incidental focal acantholytic dyskeratosis. *South Med J.* 2004;97:773-5.
3. DiMaio DJ, Cohen PR. Incidental focal acantholytic dyskeratosis. *J Am Acad Dermatol.* 1998;38:243-7.
4. Kolbusz RV, Fretzin DF. Focal acantholytic dyskeratosis in condyloma acuminata. *J Cutan Pathol.* 1987;16:44-7.
5. O'Connell BM, Nickoloff BJ. Solitary labial popular acantholytic dyskeratoma in an immunocompromised host. *Am J Dermatopathol.* 1987;9:339-42.
6. Chorzeliski TP, Kudejko J, Jablonska S. Is popular acantholytic dyskeratosis of the vulva a new entity? *Am J Dermatopathol.* 1984;6:557-60.
7. Coppola G, Muscardin LM, Piazza P. Papular acantholytic dyskeratosis. *Am J Dermatopathol.* 1986;8:364-5.
8. Van der Putte SCJ, Oey HB, Storm I. Papular acantholytic dyskeratosis of the penis. *Am J Dermatopathol.* 1986;8:365-6.
9. Warkel RL, Jager RM. Focal acantholytic dyskeratosis of the anal canal. *Am J Dermatopathol.* 1986;8:362-3.

10. Schepers C, Soler J, Palou J, Mascaró JM. Papular acantholytic dyskeratosis of the genitocrural area simulating molluscum contagiosum. *J Cutan Pathol*. 1997;24:122.
11. Coppola G, Muscardin LM, Piazza P. Papular acantholytic dyskeratosis. *Am J Dermatopathol*. 1986;8:364-5.
12. Cooper PH. Acantholytic dermatosis localized to the vulvocrural area. *J Cutan Pathol*. 1989;16:81-4.
13. Van Joost Th, Vuzevski VD, Tank B, Menke HE. Benign persistent papular acantholytic and dyskeratotic eruption: a case report and review of the literature. *Br J Dermatol*. 1991;124:92-5.
14. Bell HK, Farrar CW, Curley RK. Papular acantholytic dyskeratosis of the vulva. *Clin Exp Dermatol*. 2001;26:386-8.
15. Sáenz AM, Cirocco A, Avendaño M, González F, Sardi JR. Papular acantholytic dyskeratosis of the vulva. *Pediatr Dermatol*. 2005;22:237-9.
16. Grossin M, Battin-Bertho R, Belaich S. Another case of focal acantholytic dyskeratosis of the anal canal. *Am J Dermatopathol*. 1993;15:194-5.
17. Ko CJ, Barr RJ, Subtil A, McNiff JM. Acantholytic dyskeratotic acanthoma: a variant of a benign keratosis. *J Cutan Pathol*. 2008;35:298-301.
18. Omulecki A, Lesiak A, Narbutt J, et al. Plaque form of warty dyskeratoma—acantholytic dyskeratotic acanthoma. *J Cutan Pathol*. 2007;34:494-6.
19. Isonokami M, Higashi N. Focal acantholytic dyskeratosis—A case report in nail lesion. *Hifu*. 1990;32:507-10.
20. Sass U, Kolivras A, Richert B, et al. Acantholytic tumor of the nail: acantholytic dyskeratotic acanthoma. *J Cutan Pathol*. 2009;36:1308-1311.
21. Kirkham N. Tumors and cysts of the epidermis (Chapter 29). In: Elder DE, Elenitsas R, Johnson BL, Murphy GF. *Lever's histopathology of the Skin*, 9th edition. Lippincott Williams and Wilkins: Philadelphia, 2005:805-66.
22. Weedon D. Disorders of epidermal maturation and keratinization (Chapter 9). In: Weedon D. *Weedon's Skin Pathology*, 3rd ed. London: Churchill Livingstone Elsevier, 2010:247-79.
23. Barnette DJ Jr, Cobb M. A solitary, erythematous, hyperkeratotic papule. Acantholytic acanthoma. *Arch Dermatol*. 1995;131:211-2.
24. Cohen PR. Longitudinal erythronychia: individual or multiple linear red bands of the nail plate: a review of clinical features and associated conditions. *Am J Clin Dermatol*. 2011;12:217-31.
25. Frost K. Dyskeratosis follicularis (Darier's Disease). *Arch Derm Syphilol*. 1935;31:508-11.
26. Davis, MD, Dinneen AM, Landa N, Gibson LE. Grover's disease: clinicopathologic review of 72 cases. *Mayo. Clinic. Proc*. 1999;74:229-34.
27. Kaddu S, Dong H, Mayer G, Kerl H, Cerroni L. Warty dyskeratoma—'follicular dyskeratoma': analysis of clinicopathologic features of a distinctive follicular adnexal neoplasm. *J Am Acad Dermatol*. 2002;47:423-8.
28. Baran R, Perrin C. Focal subungual warty dyskeratoma. *Dermatology*. 1997;195:278-80.
29. Sakuntabhai A, Ruiz-Perez V, Carter S, et al. Mutations in *ATP2A2*, encoding a Ca²⁺ pump, cause Darier disease. *Nat Genet*. 1999;21:271-7.