

The dermatologist's stethoscope—traditional and new applications of dermoscopy

Iris Zalaudek, M.D.^{1,2}, Aimilios Lallas, M.D.¹, Elvira Moscarella, M.D.¹, Caterina Longo, M.D.¹,
H. Peter Soyer, M.D.³, Giuseppe Argenziano, M.D.¹

¹Dermatology and Skin Cancer Unit, Arcispedale Santa Maria Nuova, Istituto di Ricovero e Cura a Carattere Scientifico (IRCCS) Reggio Emilia, Italy

²Department of Dermatology, Medical University of Graz, Graz, Austria

³Dermatology Research Centre, The University of Queensland, School of Medicine, Princess Alexandra Hospital, Brisbane, Australia

Key words: dermoscopy, skin tumors, inflammatory skin diseases, skin infestations, topical chemotherapy

Citation: Zalaudek I, Lallas A, Moscarella E, Longo C, Soyer HP, Argenziano G. The dermatologist's stethoscope—traditional and new application of dermoscopy. *Dermatol Pract Conc*. 2013;3(2):11. <http://dx.doi.org/10.5826/dpc.0302a11>.

Received: December 5, 2012; **Accepted:** February 15, 2013; **Published:** April 30, 2013

Copyright: ©2013 Zalaudek et al. This is an open-access article distributed under the terms of the Creative Commons Attribution License, which permits unrestricted use, distribution, and reproduction in any medium, provided the original author and source are credited.

Funding: None.

Competing interests: The authors have no conflicts of interest to disclose.

All authors had full access to all of the data in the study and take responsibility for the integrity of the data and the accuracy of the data analysis. All authors have read and approved the version of the manuscript.

Corresponding author: Aimilios Lallas, M.D., Dermatology and Skin Cancer Unit, Arcispedale Santa Maria Nuova, Viale Risorgimento 80, 42100, Reggio Emilia, Italy. Tel. 00390522295611; Fax. 00390697625822. Email: emlallas@gmail.com.

Discussion

Dermoscopy is a non-invasive tool that is largely recognized and used in the diagnosis of pigmented and non-pigmented skin tumors. A steadily increasing number of publications on alternative applications of dermoscopy suggest, however, that dermoscopy aids also the recognition of skin manifestations in general dermatology.

The increasing use of dermoscopy in general dermatology can be partially explained by commercially available new generations of handheld dermoscopes, which are small enough to be easily placed in every dermatologist's pocket. Moreover, some devices do not require direct contact between the patient's skin and the optical glass plate, thus enabling a rapid and safe examination without the risk of possible transfection.

The wide and variable spectrum of traditional and newer applications of dermoscopy can be subdivided into the following six new main indications:

1. Classic dermoscopy for the diagnosis of pigmented and non-pigmented skin tumors (Figure 1) including melanocytic and non-melanocytic and benign and malignant skin tumors [1-5].
2. Entomodermoscopy for the diagnosis of skin infections and infestations (Figure 2) caused by parasites or viral, bacterial, fungal or protozoan infections [6-9].
3. Inflammoscopy for the diagnosis of inflammatory skin diseases (Figure 3), such as psoriasis, lichen ruber planus, pityriasis rosea and many others [10-12].
4. Trichoscopy for diagnosing hair and scalp disorders (Figure 4A, B, C) [13-15].
5. Capillaroscopy of the nail fold capillaries for the screening of autoimmune diseases (Figure 4D) [16-18].
6. Dermoscopy for treatment decision and monitoring: This application gains importance especially in the light of the steadily increasing availability and use of topical treatment options for non-melanoma skin cancer (Figure 5) [20-22].

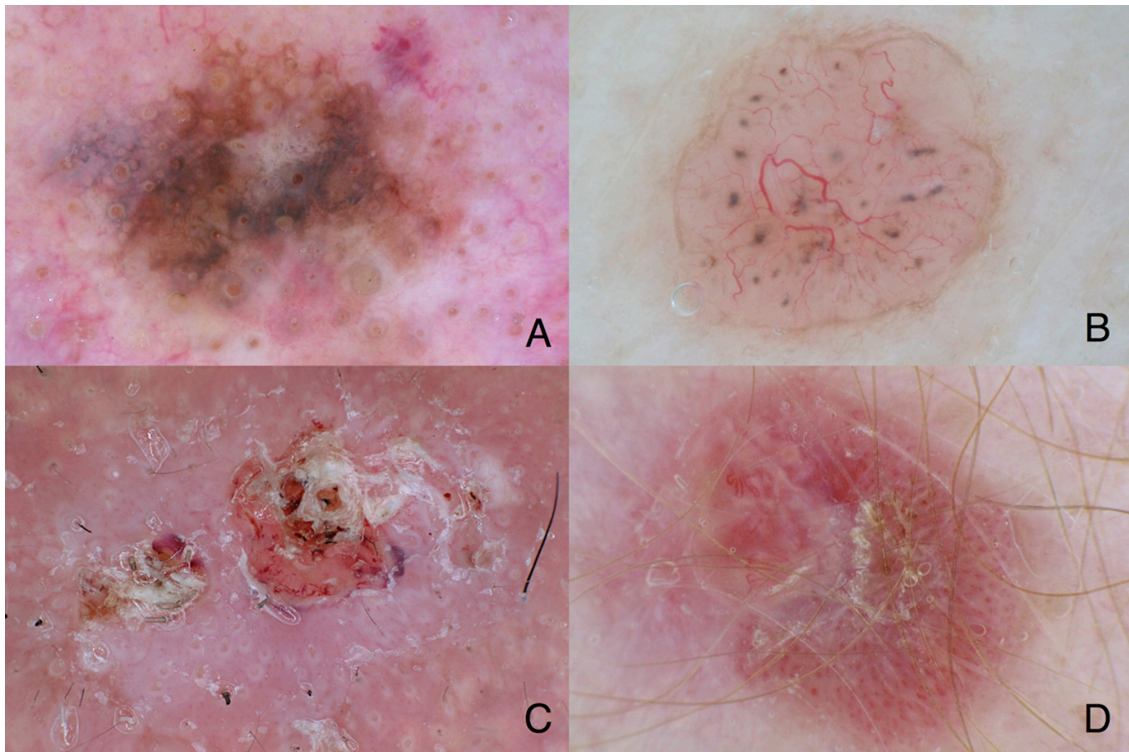


Figure 1. Classic dermoscopy improves the early diagnosis of melanoma and non-melanoma skin cancer. (A) Melanoma in situ, lentigo maligna subtype, showing gray, brown and white colors as well as gray circles (asymmetric pigmented follicular openings and gray dots (gray pepper-like granules)). (B) Nodular basal cell carcinoma showing loosely arranged gray globules and focused branching, arborizing vessels. (C) Invasive squamous cell carcinoma showing a white-pink background intermingled with white circles (targetoid appearing follicular openings consisting of an inner yellow globule and an outer white rim) and central yellow-white-red structureless areas (=keratin). (D) Amelanotic melanoma characterized by dotted and linear-irregular vessels (=polymorphous vessels). Original magnification x10. [Copyright: ©2013 Zalaudek et al.]

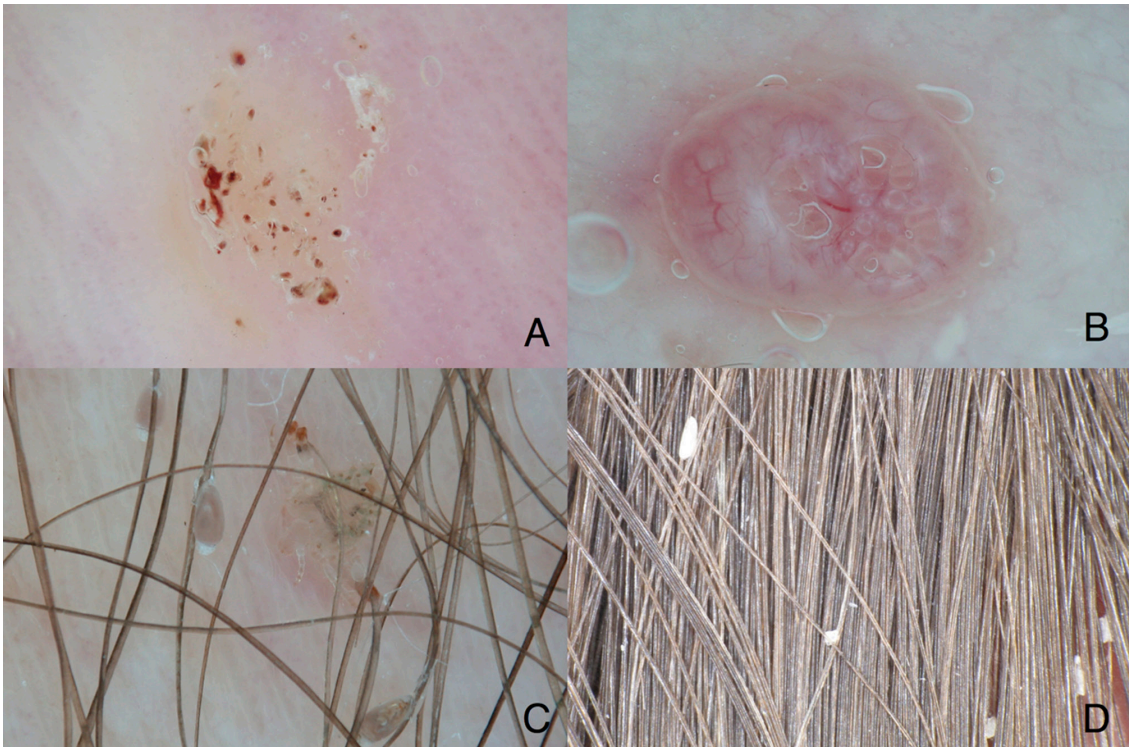


Figure 2. Entomodermoscopy improves the diagnosis of skin infestations and infections. (A) Stereotypical appearance of plantar viral wart showing structureless white-yellow areas and multiple small linear brown to red dots and streaks (=splinter hemorrhages). (B) Molluscum contagiosum is typified by central opaque yellowish globules, which are surrounded by blurred linear vessels (=crown vessels). (C) Dermoscopy of phthiriasis pubis with vital nits attached to the hair shaft. Vital nits have a convex end and appear translucent brownish. (D) Dermoscopy of pseudo-nits due to hair casts, which appear as white amorphous structures attached to the hair shaft. Original magnification x10. [Copyright: ©2013 Zalaudek et al.]

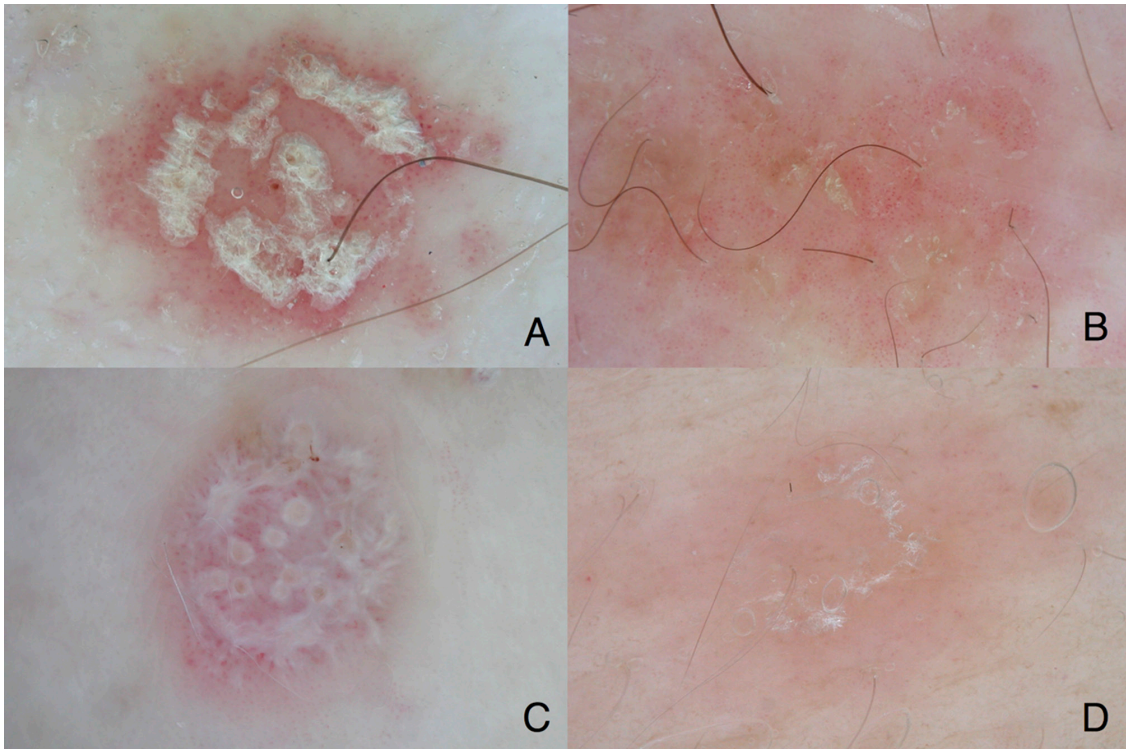


Figure 3. Inflammoscopy improves the differential diagnosis of inflammatory skin disorders. (A) Dermoscopy of psoriasis shows regularly arranged dotted vessels and white scales. (B) Dermoscopy of nummular eczema is typified by dotted vessels in a patchy arrangement and yellow scales. (C) Lichen ruber planus shows white streaks (=Whickham striae) over a red background and dotted and linear vessels. (D) Pityriasis rosea is characterized a red-brown structureless color and fine white translucent scales that “hang” from the periphery towards the center like a curtain. Original magnification x10. [Copyright: ©2013 Zalaudek et al.]

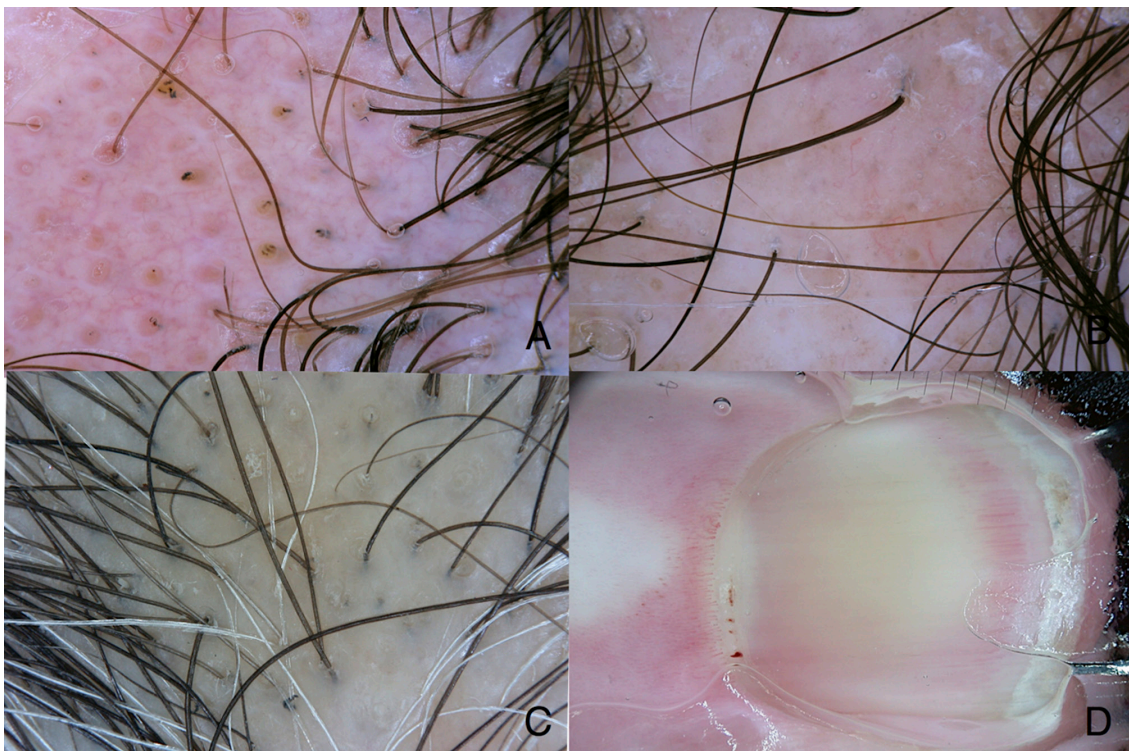


Figure 4. Trichoscopy and capillaroscopy. (A) Clinical image of a patient with alopecia areata showing yellow globules corresponding to hair follicles, cadaverized and exclamation hairs. (B) Dermoscopy of scarring alopecia due to discoid lupus erythematosus. There is a significant reduction of the hair follicles. Some linear vessels are additionally seen. (C) Dermoscopy of lichen planopilaris is characterized by keratotic scales within and around the hair shaft and reduced number of follicular openings. (D) Capillaroscopy of the nail fold of a patient with systemic sclerosis reveals twisted and elongated nail fold capillaries as well as micro-hemorrhages in the cuticula. Original magnification x10. [Copyright: ©2013 Zalaudek et al.]

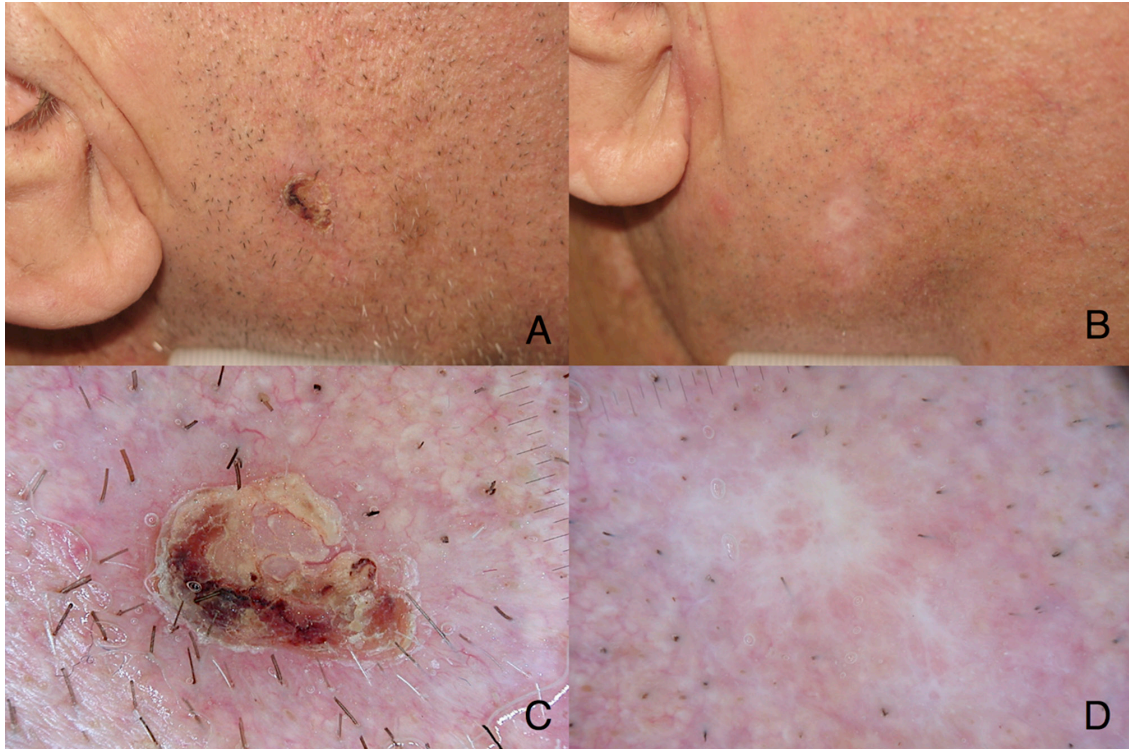


Figure 5. Clinical image of basal cell carcinoma (A) before and (B) two months after a six-week cycle of imiquimod 5% cream applied five times a week. (C) Dermoscopy of basal cell carcinoma at baseline showing peripheral focused arborizing vessels and a central ulceration. (D) After successful topic treatment, there is absence of criteria suggestive of persistence. Only white scar-like areas are visible. [Copyright: ©2013 Zalaudek et al.]

Conclusion

In summary, dermoscopy should be regarded as a safe and rapid diagnostic tool that assists in clinical examination and management decision in dermatology, as the stethoscope does for diagnosing heart, lung or abdominal problems. As a consequence, dermoscopy can be nowadays seen as the dermatologists' stethoscope.

References

- Vestergaard ME, Macaskill P, Holt PE, Menzies SW. Dermoscopy compared with naked eye examination for the diagnosis of primary melanoma: a meta-analysis of studies performed in a clinical setting. *Br J Dermatol.* 2008;159(3):669–76.
- Fagnoli MC, Kostaki D, Piccioni A, Micantonio T, Peris K. Dermoscopy in the diagnosis and management of non-melanoma skin cancers. *Eur J Dermatol.* 2012;22(4):456-63.
- Zalaudek I, Giacomel J, Schmid K, et al. Dermoscopy of facial actinic keratosis, intraepidermal carcinoma, and invasive squamous cell carcinoma: a progression model. *J Am Acad Dermatol.* 2012;66(4):589-97.
- Rosendahl C, Tschandl P, Cameron A, Kittler H. Diagnostic accuracy of dermoscopy for melanocytic and nonmelanocytic pigmented lesions. *J Am Acad Dermatol.* 2011;64(6):1068-73.
- Lallas A, Apalla Z, Lefaki I, et al. Dermoscopy of early stage mycosis fungoides. *J Eur Acad Dermatol Venereol.* 2012 Mar 9.[Epub ahead of print]
- Tschandl P, Argenziano G, Bakos R, et al. Dermoscopy and entomology (entomodermoscopy). *J Dtsch Dermatol Ges.* 2009;7(7):589-96.
- Zalaudek I, Giacomel J, Cabo H, et al. Entomodermoscopy: a new tool for diagnosing skin infections and infestations. *Dermatology.* 2008;216(1):14-23.
- Zalaudek I, Argenziano G. Images in clinical medicine. Dermoscopy of nits and pseudonits. *N Engl J Med.* 2012;367(18):1741.
- Dupuy A, Dehen L, Bourrat E, et al. Accuracy of standard dermoscopy for diagnosing scabies. *J Am Acad Dermatol.* 2007;56(1):53-62.
- Zalaudek I, Argenziano G, Di Stefani A, et al. Dermoscopy in general dermatology. *Dermatology.* 2006;212(1):7-18.
- Lallas A, Apalla Z, Lefaki I et al. Dermoscopy of discoid lupus erythematosus. *Br J Dermatol.* 2012; 168(2):282-8.
- Lallas A, Kyrgidis A, Tzellos TG, et al. Accuracy of dermoscopic criteria for the diagnosis of psoriasis, dermatitis, lichen planus and pityriasis rosea. *Br J Dermatol.* 2012;166(6):1198-205.
- Olszewska M, Rudnicka L, Rakowska A, Kowalska-Oledzka E, Slowinska M. Trichoscopy. *Arch Dermatol.* 2008;144(8):1007.
- Rudnicka L, Olszewska M, Rakowska A, Slowinska M. Trichoscopy update 2011. *J Dermatol Case Rep.* 2011;5(4):82-8.
- Miteva M, Tosti A. Hair and scalp dermoscopy. *J Am Acad Dermatol.* 2012;67(5):1040-8.
- Bergman R, Sharony L, Schapira D, Nahir MA, Balbir-Gurman A. The handheld dermatoscope as a nail-fold capillaroscopic instrument. *Arch Dermatol.* 2003;139(8):1027-30.
- Vázquez-López F, Marghoob AA. Dermoscopy vs capillaroscopy of nontumoral dermatoses. *Arch Dermatol.* 2004;140(5):617.

18. Hasegawa M. Dermoscopy findings of nail fold capillaries in connective tissue diseases. *J Dermatol.* 2011;38(1):66-70.
19. Beltrán E, Toll A, Pros A, Carbonell J, Pujol RM. Assessment of nailfold capillaroscopy by x 30 digital epiluminescence (dermoscopy) in patients with Raynaud phenomenon. *Br J Dermatol.* 2007;156(5):892-8.
20. Kaçar N, Sanli B, Zalaudek, Yildiz N, Ergin S. Dermatoscopy for monitoring treatment of actinic keratosis with imiquimod. *Clin Exp Dermatol.* 2012;37(5):567-9.
21. Micantonio T, Fagnoli MC, Peris K. Usefulness of dermoscopy to monitor clinical efficacy of imiquimod treatment for lentigo maligna. *Arch Dermatol.* 2006;142(4):530-1.
22. Micantonio T, Fagnoli MC, Piccolo D, Perris K. Letter: Changes in dermoscopic features in superficial basal cell carcinomas treated with imiquimod. *Dermatol Surg.* 2007;33(11):1403-5.