

ECOLOGICAL FEATURES OF MICROBIOCENOSIS OF THE SKIN OF MAMMARY GLANDS AND VAGINA IN PREGNANT WOMEN WITH THREAT OF PRETERM LABOR

V. Ya. Ivankiv, I. M. Malanchyn, N. I. Tkachuk

I. HORBACHEVSKY TERNOPIL STATE MEDICAL UNIVERSITY, TERNOPIL, UKRAINE

Background. *The threat of preterm birth is one of the most topical issues in the world medicine. According to the statistics, from 12–13 to 25–35 % of all pregnancies end prematurely. One of the causes of preterm labour is chronic inflammatory processes of female genital organs and disorder of microbiocenosis. Timely diagnosis and adequate treatment will reduce the risk of premature labour and avoid perinatal loss.*

Objective. *We examined and analysed the microflora of the skin of mammary glands and mucous membrane of vagina in healthy pregnant women and patients with threat of preterm labour.*

Methods. *The examination of the pregnant was conducted at the TRMPC “Mother and Child” in several stages. First of all, we rinsed the skin of mammary glands and smeared from mucous membrane the posterior vault of vagina with sterile swabs pre-moistened in physiological solution. After that, the tampons were placed in sterile tubes and delivered to laboratory. Sowing was carried out on Petri dishes with sterile medium: ZHSA, bloods MPA, Endo, Saburo, thioglycolic medium.*

Results. *As a result of the research we found saprophytic Gram-positive and Gram-negative microorganisms (in women with a physiological course of pregnancy). In pregnant women with preterm labor, there is an increase in the number of *St. haemolyticus* from 13% to 87%, appearance of representatives of the pathogenic flora – *St. aureus* (in 20%).*

Conclusions. *Changes in the microbiocenosis of the mammary glands and mucous membranes of the vagina of pregnant women with preterm labor may indicate the presence of opportunistic microflora, or personal hygiene or the presence of associated bacterial infections. It requires the further investigation of possible links among the preterm birth and microbiota.*

KEY WORDS: **microbiocenosis of the skin of mammary glands; mucous membrane of vagina; preterm labour.**

Introduction

Currently, the threat of preterm birth is one of the most pressing issues in the world. According to literary statistics, from 12–13 to 25–35% of all pregnancies ended prematurely [1, 3]. One of the causes of preterm labour is chronic inflammatory processes of female genital organs and disorder (dysbiosis) of microbiocenosis [2]. Timely diagnosis and adequate treatment reduce the risk of premature labour and avoid perinatal loss. In normal conditions, women are dominated by lactic acid bacteria in vagina, which prefer to live in an acidified medium of healthy vagina [4, 6]. They protect mucous membrane and may show slight scaling of mucous membranes. If this *Lactobacillus* becomes little, conditionally pathogenic microbes begin to multiply instead of them. They are

Corresponding author: Natalia Tkachuk, Department of Microbiology, Virology and Immunology, I. Horbachevsky Ternopil State Medical University, 1 Maidan Voli, Ternopil, Ukraine, 46001

Phone number: +380352250539

E-mail: tkachuk@tdmu.edu.ua

also normally in a womb of a healthy woman, but in very small quantities. If there are many of them the imbalance presents and bacterial vaginosis develops [5].

According to the literature, the main causes of the imbalance of microorganisms are:

- changes of hormonal state in pregnancy, when progesterone hormones shift the vaginal medium to the paralysis;
- dysbiosis in intestine, which promotes changes in the balance of microbes in vagina;
- the use of drugs during pregnancy that affect microflora;
- chronic infectious processes in the body of a pregnant woman with chronic inflammation in the urinary tract that is most often relevant;
- chronic sex infections are not detected in time and aggravated during pregnancy (Ford H. B, Schust D. J, 2009).

Methods

The examination of the pregnant was conducted at Ternopil Regional Municipal Perinatal

Centre "Mother and Child" in several stages. First of all, we rinsed the skin of mammary glands and smeared from mucous membrane the posterior vault of vagina with sterile swabs pre-moistened in physiological solution. We took the material by scrolling all sides of cotton swab. After that, the tampons were placed in sterile tubes and delivered to laboratory. The time was 20-30 minutes from the stage of taking the research material to the crop. Sowing was carried out on Petri dishes in sterile medium: ZHSA, bloods MPA (for detection of coccious microorganisms), Endo (Enterobacteriaceae), Saburo (mushrooms of genus *Candida*), thioglycolic medium (anaerobic microorganisms). Each of the cups was marked with the indication accordingly. Sowing on the medium was carried out with tampons: first touching one edge of Petri cup, then – scrolling with all sides. Then we continued sowing the sterilized bacteriological loop perpendicular to the sowing with a swab. The media was placed in a thermostat for 18-48 hours at an optimum temperature. We evaluated the growth of microorganisms on the media after incubation in the thermostat (their shape, colour, size of colonies, nature of surface and edges). Next, we made smears from certain types of colonies, stained with Gram method and microscopically.

Results

As a result of microscopic examination, in 15 women from the control group (pregnant women with physiological pregnancy) were found:

- **on the skin of mammary gland** *E. coli*, *Fusobacterium*, Gram-positive non-spore bacillus, *M. roseus*, *Streptococcus* spp., lactose-negative Enterobacteria in 7%; *Lactobacillus*,

St. haemolyticus – in 13%; *St. saprophyticus* – in 20%; *Corynebacterium* – in 27%; *Clostridium*, *Tetracoccus*, *Bacillus* spp. – in 33%; *M. luteus* – in 40%, *Peptostreptococcus*, *St. epidermidis*, *M. lylae* – in 47%; *Bacteroides* – in 60% of the examined patients were present;

- **in the vaginal smears** *St. hominis*, *Streptococcus*, Gram-positive non-spore bacillus, *St. haemolyticus* in 7%; *Streptobacillus*, *Streptococcus* spp., *M. lylae* – in 13%; *Tetracoccus*, *Candida*, *E. coli*, *St. saprophyticus*, Lactose-negative Enterobacteria – in 20%; *M. luteus* – in 33%; Doderlein sticks, *Corynebacterium*, *St. epidermidis*, *Bacillus* spp. – in 40%; *Clostridium*, *Bacteroides*, *Enterococcus* – in 47%; *Lactobacillus* – in 73% of the examined women were evidenced.

In the patients with a threat of preterm labour, it was found:

- **on the skin of mammary glands:** *M. sedentarius*, *St. hominis*, *M. roseus*, *Lactobacillus*, Gamma-hemolyticus streptococcus – in 7%; *M. varians*, *Bacillus* spp. – in 13%; *Co-*

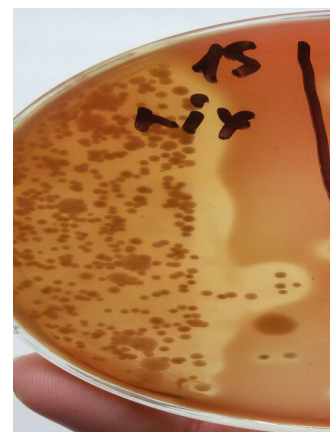

Fig. 2. Cultures of microorganisms on Petri dishes (bloods MPA medium)

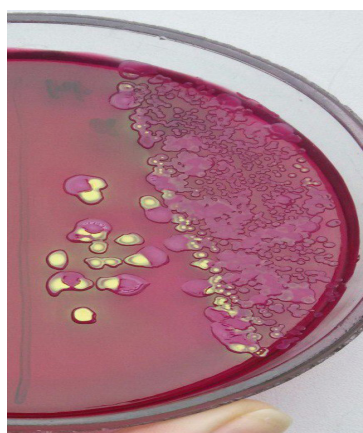


Fig. 1. Cultures of microorganisms on Petri dishes (Endo medium)

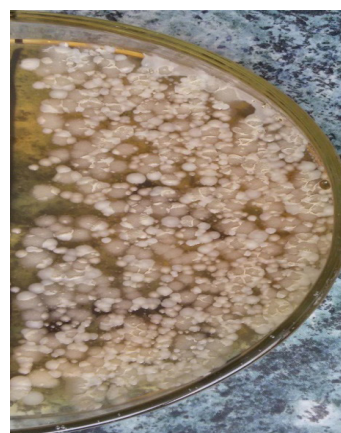

Fig. 3. Cultures of microorganisms on Petri dishes (ZHSA medium)

rynebakterium spp., *St. aureus*, *M. lylae* – in 20%; *M. luteus*, *St. epidermidis* – in 33%; *St. haemolyticus* – in 87% of the examined;

– **in the vagina smears:** *St. epidermidis*, *M. luteus*, *Streptobacillus* in – 7%; *St. aureus*, Lactose-negative *Enterococcus* – in 13%; Alpha-hemolytic streptococcus, Beta-hemolytic streptococcus in – 20%; *Bacillus* spp., *Candida*, *E. coli* – in 27%; *Enterococcus* – in 53%; *St. haemolyticus* in 67% of the examined pregnant women.

Discussion

According to foreign statistics, approximately 25% of all cases of preterm labour were caused by mother or foetus indications, 30% – due to premature rupture of membranes of foetus [8]. Many scholars argue that most of the premature labour occurs on the background of uncomplicated pregnancy [7, 9].

But, despite this, and summing up the results of our research, we can assume that a violation of microflora of vagina and skin of mammary glands is one of the causes of preterm labour. That is why women with violations of microflora of vagina and skin of mammary glands should be under the obstetrician supervision of obstetrician-gynaecologist. Each pregnant woman should be thoroughly examined to prevent complications during labour and avoid perinatal loss. In the detection of any pathology of female genital organs, it is necessary to conduct timely treatment.

References

1. Order of the Ministry of Health of Ukraine № 624: Premature childbirth. Accessed 03 Nov 2008.
2. Medved VI. Selected lectures on extragenital pathology of pregnant women. Kyiv; 2010:10–240.
3. Zhuk SI, KalinkaYa, Sidelnikova VM. Missing pregnancy: a new look at the old problem. Health of Ukraine. 2007;5:1–35.
4. Shchurevskaya OD. Stress of mother during pregnancy: implications for the fetus and the newborn. Taking Care of a Woman. 2015;9:54–57.
5. Golyanovsky V. Screening and treatment of bacterial vaginosis during pregnancy. Taking Care of a Woman. 2015;5:88–92.
6. Reznichenko HI. Prevention of miscarriage and premature delivery. Zhinochyi likar. 2013;3:10–12.
7. Khmil SV, Kuchma ZM, Romanchuk LI. Obstetrics. Ternopil. Tutorials and manuals. 2010:313–345.
8. Ford HB, Schust DJ. Recurrent pregnancy loss: etiology, diagnosis, and therapy. Rev Obstet Gynecol. 2009;2(2):76–83.
9. Christiansen OB, Steffensen R, Nielsen HS, Varming K. Multifactorial etiology of recurrent miscarriage and its scientific and clinical implications. Gynecol Obstet Invest. 2008;66(4):257–267.

Received: 2017-09-20