

## **Surgical Management of a Hydatid Cyst of the Hepatic Dome Ruptured into the Biliary Tree**

**Ali J. Awad \***

**Raysan F. Al-Fayadh\*\***

**CABS, MRCS**

**MD, FRCSE, FACS**

### **Summary:**

**Background:** Hydatid disease remains an important & challenging medical problem.

**Case report:** A 62 year old male patient was admitted complaining of upper abdominal discomfort. Six days earlier he suffered from acute pain in the right upper quadrant, mild systemic allergic manifestation, a fever of 38.5°C and chills. He was managed by a new surgical approach of myoplasty of the right hemidiaphragm combined with preoperative decompression of the bile duct by an endoscopic sphincterotomy. A case search identified study describing rupture of a hydatid cyst of the hepatic dome into biliary tract. The incidence of intrabiliary rupture of hepatic hydatid cysts is 25% in patients treated with external surgical drainage for liver hydatid cysts. Postoperative external biliary fistula have been reported in 27.5%.

**Conclusion:** this procedure may require less time (because liver mobilization is not necessary) and allows for easier abdominal reoperation in the future. The simplicity of the technique allows for a more reliable alternative to the treatment of the hydatid cyst located over the superior-posterior aspects of the liver.

**Key words:** Hydatidosis- Hydatid disease- liver- omentoplasty- myoplasty technique- Echinococcus.

*Fac Med Baghdad*  
2009; Vol. 51, No. 4  
Received Aug. 2009  
Accepted Oct. 2009

### **Introduction:**

We report the case of a male patient 62 years old with obstructive jaundice caused by rupture of a hydatid cyst of the hepatic dome into the biliary tract 1,2. Human echinococcosis is an endemic surgical problem in any Mediterranean country. CT scan demonstrated hydatid cyst located over the right superior-posterior aspect of the liver.

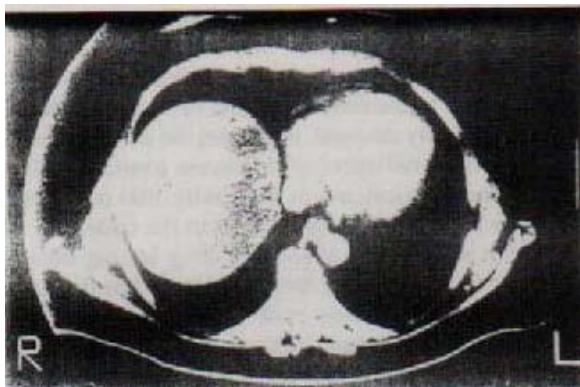
### **Case report:**

We report the case of a patient who had obstructive jaundice caused by rupture of a hydatid cyst of the hepatic dome into the biliary tract. He was managed by a surgical approach combined with preoperative decompression of the bile duct by an endoscopic sphincterotomy. The patient had a history of a liver hydatid cyst that was managed surgically by evacuation, unroofing of the cyst, and omentoplasty 6 years earlier on admission he was jaundiced with no masses palpable in the abdomen, laboratory investigation showed picture of mild obstructive jaundice. ERCP done shows dilated common bile duct with debris of daughter echinococcal cysts. Daughter cysts were removed and an endoscopic sphincterotomy was performed. At surgery, using a right postero-lateral thoracotomy, the right hemidiaphragm was opened, five hydatid cysts (5-8cm) containing bile were drained. Unroofing at the cysts with partial pericystectomy, accompanied by

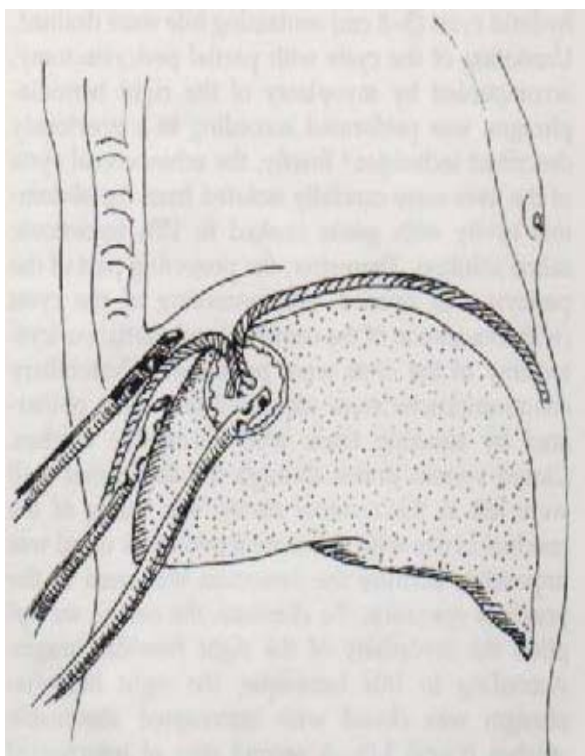
myoplasty of the right hemidiaphragm, was performed. The echinococcal cysts of the liver were carefully isolated from the abdominal cavity with gauze soaked in 15% hypertonic saline solution. Therefore, the projecting part of the pericyst was opened, and unroofing of the cysts (with evacuation of the contents) and partial pericystectomy of the cysts were performed 7, 8. Cystobiliary communications were identified and were obliterated by suturing them with absorbable stitches: closed system drains through the abdominal wall were left in the residual cavity. The filling of the residual cavity with an omental pedicle as usual was impossible because the omentum was used in the previous operation. To eliminate the cavity, we applied the myoplasty of the right hemidiaphragm. According to this technique, the right hemidiaphragm was closed with interrupted absorbable stitches. (Vicryl 1.0). A second row of the interrupted stitches was performed in a parallel line from the previous stitches, more distally from the edges of the initial incision. Therefore, the incision's edges of the right hemidiaphragm protruded into the residual cavity of the cyst 11, 12. Thus the diaphragm could play a similar role as the omentum in omentoplasty. The postoperative course, the drainage tubes were removed on postoperative day 8, and the patient was discharged in good general condition 3 days later.

\*Department of Surgery ,Al-Karama Teaching Hospital.

\*\* Department of Surgery, Al-Mustansiriyah Medical College.



**Fig. 1** Computerized tomography scan demonstrating hydatid cysts located over the right superior-posterior aspect of the liver



**Fig. 2** Diagram showing the myoplasty of the hemidiaphragm. The incision edges of the right hemidiaphragm protrude into the residual cavity of the cyst

#### Discussion:

Liver hydatidosis cannot be considered "a benign disease" because it is progressive and often recurrent (10% to 20% of cases). 10% in recurrences, a mortality rate that reaches operative strategy to patient considering age, general status, accurate preoperative evaluation of size, number and location of the cyst, interference with the biliary system and vascular supply of the liver. The radical procedures achieve better results of postoperative complications and recurrence of the disease<sup>3-4</sup>. The incidence of intrabiliary rupture of hepatic hydatid cysts is 25% 4, 8 in patients treated with external surgical

drainage for liver hydatid cysts. Postoperative external biliary fistula have been reported in 27.5% 2. Immediate postoperative complications are related mainly to the remnant of the cyst cavity. Our technique for cysts located at liver dome by suturing the edge of the diaphragm with interrupted stitches. The diaphragm has the same properties as the greater omentum. So this procedure may require less time (because liver mobilization is not necessary) 5. The simplicity of the technique allows for a more reliable alternative to the treatment of the hydatid cyst located over the right superior-posterior aspects of the liver<sup>9-10</sup>. Consequently, it should be considered available addition to the treatment of the hepatic dome hydatidosis and deserve application 6.

#### References:

- 1- Doty JE, Tompkins RK, *Management of Cystic Disease of the Liver*, Surg.Clin.North.Am. 1989, 69, 285-290.
- 2- Little JM, Hollands MJ, Ekberg H, *Recurrence of hydatid disease*, World J Surg, 2004, 12, 700-704.
- 3- Ennabli K, Saidi R., *The postoperative mortality of the liver hydatid cysts*, Lyon Chir, 1983, 28: 411-413.
- 4- Dawson JL, Stamatakis JD, Stringer MD, Williams R., *Surgical treatment of hepatic hydatid disease*, Br J Surg, 2007, 75: 946-948.
- 5- Demirci S, Eraslan S, Anadol E, *Comparison of difference surgical technique in the management hydatid cyst of the liver*, World J Surg, 2003, 13: 88-91.
- 6- Leung JWC, Chung JY, Li MKW, *Endoscopic Management of Postoperative Biliary Fistula*, Surg Endosc, 1988, 2: 190-193.
- 7- Dosios T, Kouraklis G, Karatzas G, *Diaphragm myoplasty in the prevention of complication after surgery of hydrated disease of the liver*, World J Surg in Press.
- 8- Demirci S, Eraslan S, Anadol E, *Comparison of different surgical techniques in the management of hydatid cyst of the liver*, World J Surg, 2006, 13: 88-91.
- 9- Dziri C., *Hydatid disease, Continuing serious public health problem*, World J Surg, 2005, 25: 1-3.
- 10- Zaouche A., Haouet K., Jouini M., El Hachaichi A., Dziri C., *Management of liver hydatid cyst with a large bilocystic fistula: Multicenter retrospective study*, World J Surg, 2004, 25: 28-39.
- 11- Leung JWC, Cotton PB, *Endoscopic nasobiliary catheter drainage in biliary & pancreatic disease*, Am J Gastroenterol, 2004, 86: 389-394.
- 12- Girenei A, Bertoldi T., *Evolution of Surgery for Liver Hydatosis from 1950 to today: Analysis of Personal Experience*, World J Surg, 2005, 25: 87-92.