

Herbal activation of mammary gland; a comparative morphometrical & Biochemical analysis

Malak A Al-Yawer*Ph.D
Huda M Al-Khateeb* Ph.D
Fadhil A Al-Khafaji*Ph.D
Zuher. R. Zahid*Ph.D

Summary:

J Fac Med Baghdad
Vol. 49, No. 1, 2007
Received: Sep. 2005
Accepted: June 2006

Seventy five adult virgin female Norway rats (60 experimental and 15 controls) were used to evaluate the effect of seeds of three herbs (Fennel, Cumin and Garden cress) on their mammary glands. Experimental animals were fed with these herbs (each type of herb seeds was given to twenty experimental rats) for fourteen days. Rats were sacrificed and mammary gland sections were obtained, stained then morphometrically assessed. Serum prolactin level was performed too.

Results revealed that Garden cress seeds are the strongest lactogenic agent among the three. Both Fennel and Cumin seeds were shown to be very weak galactagogues.

Key words: Fennel (*Foeniculum vulgare*), Cumin (*Cuminum cyminum*) Garden cress (*Leptidium sativum*), Morphometry prolactin.

Introduction:

Fennel (Family name = Umbelliferae, Scientific name = *Foeniculum vulgare*, Arabic name = Habbat - Helwah), Cumin (Family name = Umbelliferae, Scientific name = *Cuminum cyminum*, Arabic name = kammun) and Garden cress (Family name = Cruciferae, Scientific name = *Leptidium sativum*, Arabic name = Rhishad) seeds were reputed (by the practitioners of traditional medicine and most of the books that are concerned with herbs) as strong galactagogal agents (1,2,3,4,5) However, scientific conformations are not found (Medline reviewed 2004 - 1965).

Therefore, the present preliminary study was designated to pick up the real galactagogue (by evaluation and comparison of the lactogenic role played by these herbs, on the mammary gland, using morphometrical and biochemical means).

Materials And Methods:

A total of 75 adult virgin female Norway rats (*Rattus norvegicus*) were used in this experiment. Their average body weight ranged between 140 - 200gm. They were kept at a temperature between 20 - 24 ° C (room temperature). Animals were housed individually in wire - meshed stainless steel cages. The light / dark cycle was maintained as 12 hr.s /12 hr.s. Rats were fed the ordinary pallet diet and maintained on free access to food and water. They were divided into 60 experimental rats (each 20 were fed one type of herb seeds) and 15 as control.

Seeds of the three herbs were cleaned from artifacts, standardized in the "Iraqi National Herbarium" and in

the "Dept. of Pharmacognosy, College of Pharmacy, Univ. of Baghdad" and ground in a coffee grinder. The seeds powder was suspended in distilled water (DW) and given via oro-gastric tube. Each experimental rat received 1.6 mg seeds powder / g body weight / day (the calculated dose was suspended in 4ml DW) for 14 days. The control received 4ml DW as placebo, under identical conditions.

After 14 days animals (both experimental and control rats) were sacrificed. Mammary gland samples were obtained. These samples were processed for routine haematoxylin and eosin stain (HE stain) (6). Blood samples were obtained via intra-cardiac puncture before animal sacrifice (to be used for estimation of serum prolactin, using the "Enzyme Linked Fluorescent Assay" 30 410 / Vidas Prolactin Kits, BioM'erieux /France).

Three parameters (acinar diameter, thickness of the secretory epithelium and number of nuclei per one acinus) were studied morphometrically, using ocular micrometer fitted to light microscope at 10x40 magnification (calibration was done using slide micrometer).

The collected data were analyzed using the computer facility with the available software statistical packages "Statistical Packages for Social Sciences, Version 10.0" (SPSS 10.0). The significance of differences among the quantitative variables of the three groups was assessed using One-way analysis of variance (ANOVA). Results between two groups were analyzed using student's t- test (7)

Results:

During the period of experiment, rats were maintaining good general health and well being as assessed by their normal activities and good food

*Dept. of Anatomy, College of Pharmacy, Univ. of Baghdad"

intake. However, statistically significant weight differences, between control and experimental animals, were not recorded.

HE stained sections, of control mammary gland, exhibited small lobules scattered among huge amount of adipose and connective tissues. Each lobule consisted of few secretory tubules. Interlobular ducts were found within interlobular connective tissue (Figure 1).

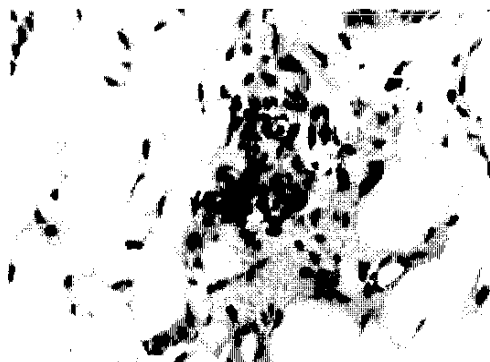


Figure (1): HE stained section of mammary gland of control group (X 40)

On the other hand, experimental rats' mammary glands were showing relative increase in lobular size on the account of adipose and connective tissues reduction. Acini and ducts were larger and with wider lumen. Some were eliciting secretory products within their lumen (Figure 2, 3 and 4).

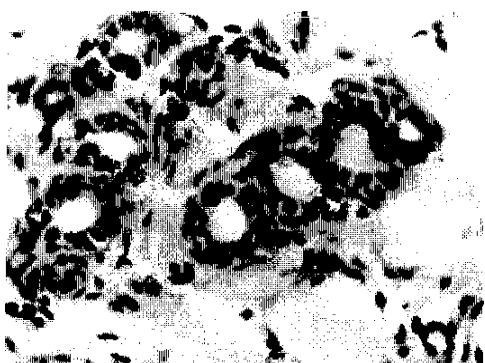


Figure (2): fennel-treated rat mammary gland. Note the dilated acini (HE stain). (X 40)

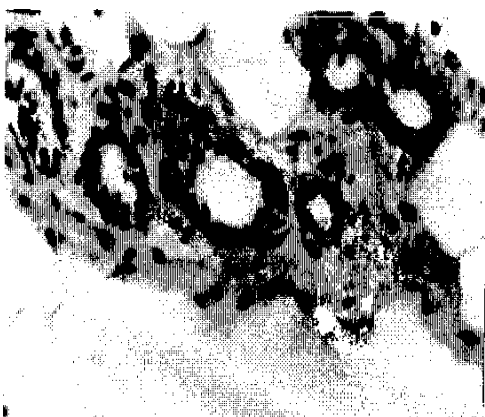


Figure (3): HE stained section of cumin-treated rat mammary gland showing dilated acini. (X 40)

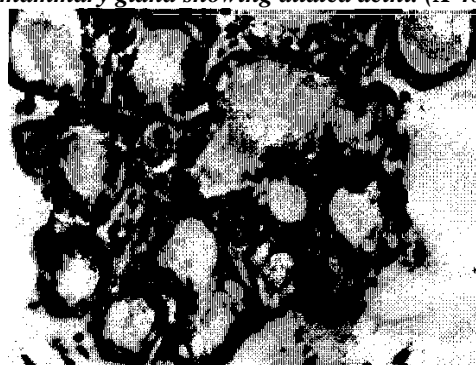

Figure (4): Garden cress-treated rat mammary gland exhibiting widely dilated acini, which are filled with milk secretion (HE stain). (X 40)

Lastly, collected morphometrical data is listed in table (1) and hormonal survey in table (2).

Table (1): manifesting histometry of some items in the mammary gland sections (of control and experimental rats) using eye piece micrometer.

Group	Acinar dia. (µm)	Acinar epith. thickness (µm)	No. of nuclei per acinar wall
Control	23.01±1.49	12.16±1.82	14±1.16
Fennel	39.03±3.94*	7±0.76*	15±1.64
Cumin	38.39±1.93*	7.41±0.52*	14±1.34
Garden cress	44.35±4.31 *	7.71±0.31 *	16±2.19*

Data are expressed as mean ± standard deviation
dia. = diameter, epith. = epithelium, No. = number
* = significant at P < 0.05, ** = significant at P < 0.01

Table (2): exhibiting serum prolactin level survey in control and experimental groups.

Group	Serum prolactin (ng/ml)
Control	4.50±0.31
Fennel	5.73±0.18
Cumin	6.45±0.20
Garden cress	9.00±0.14*

Data are expressed as mean ± standard deviation * = significant at P < 0.05 ** = significant at P < 0.01

Discussion:

Although, seeds of the three herbs are recorded as nutritional items (1,2), yet maintenance of good general health during treatment was not accompanied by significant weight gain, this may be due to the strong diuretic action of these herbs (2,5,8,9)

Histologically, control mammary glands revealed features of a resting mammary gland, which match the age and physiology of this group (10,11)

The marked mammogenic effect of fennel seeds on the mammary gland could be attributed to anethole, which is the main constituent of essential oil of fennel seeds⁽²⁾. Anethole is considered to be an active estrogenic agent that is responsible for the mammatrophic activity. It acts either by interacting with estrogen receptors, activation of estrogen dependant progesterone receptors⁽¹²⁾, or by stimulation of the release of vascular endothelial growth factors (VEGFs) (13)

The mammogenic effect of cumin seeds, in this study, seems to exceed that of fennel. This mammatrophic activity, of cumin seeds, may be due to the estrogenic effect of its volatile oil (contains cuminaldehyde, γ -terpens, (3-pinenes, P-cymene and 1,3-P-menthandial) (2).

In this investigation, Garden cress seeds seem to have great mammogenic effect together with lactogenic activity (strongest among the three), which was clearly evident by marked acinar dilatation (filled with milk secretion), increase number of nuclei / acinus and significant highest serum prolactin level. Such outcome was not worked out previously (Medline reviewed 2004 - 1965), therefore, it can be regarded as a 1st step in this topic. The effect of Garden cress seeds on the mammary gland could be due to its cardiac steroids (cardenolides) content (2,8,14)

In conclusion, Garden cress is the strongest lactogenic agent among the three tested herbs. Furthermore, morphometry could be very good, easy and precise parameter in assessing mammary gland activity.

Finally, future studies should be directed towards detailed histological, histochemical and a biochemical study on the seeds extracts effect on the mammary gland.

References:

1. [British Herbal Pharmacopia], 1983. Published by the "British Herbal Medicine Association Scientific Committee".
2. [PDR for Herbal Medicine], 1998. 1st ed., Medical Economic Co., New Jersey.
3. Dastur F (ed.), 1977. In: [Medicinal plants in India and Pakistan]. 4th ed., Taraporeverta Sons and Co. Private Ltd.
4. Al-Rawi A and Chakravarty H (ed.s), 1988. In: [Medicinal Plants in Iraq]. 2nd Ed., Al-Yaqda Press, Baghdad.
5. Balch J and Balch P, 1988. Herbs. In: [Nutritional Healing]. 2^d ed., Avery Publishing group. NY. 63 - 70.
6. Stevens A, 1982. The haematoxylin. In: [Theory and Practice in Histological Techniques]. 2nd ed., Bancroft and Stevens A (ed.s), Churchill Living Stone, London, 114 - 116.
7. Daniel W, 1988. Hypothesis testing. In: [Biostatistics: A Foundation for Analysis in the Health Sciences]. 4th ed., Wiley J & Sons, London, 161 - 250.
8. Evans W, 1998. In: [Trease and Evans Pharmacognosy]. 4th ed., WB Saunders Co. Ltd., London.
9. [The Wealth of India], 1976. Vol. X, Publication and Information Directorarte CSIR, New Delhi, 307-311.

10. Junqueira L, Cameiro J and Kelley R (ed.s), 2003. Mammary gland. In: [Basic Histology]. 10th ed., Prentice - Hall International Inc., USA, 443 - 446.

11. Ganong F (ed.), 1995. The female reproductive system. In: [Review of Medical Physiology]. 17th ed., Prentice - Hall International Inc., USA, 379 - 417.

12. Haslam S, 1988. "Cell to cell interactions and normal mammary gland function". J. Dairy Sci., 71(10), 2843-2854.

13. Pepper M, Baetens D, Mandriota S, Di Sanza C and Iruela M, 2000. "Regulation of VEGF and VEGF receptor expression in the rodent mammary gland during pregnancy, lactation and involution". Dev. Dyn., 218(3), 507-524. (Medline)

14. Newall C, Anderson L and Phillipson J, 1996. In: [Herbal Medicines; A Guide for Health Care Professionals]. The Pharmaceutical Press, London.