

Subcutaneous Pancreatic Transplantation Shows Success In The Treatment Of Experimentally Induced Diabetes Mellitus In Golden Hamsters

Mahera N Al-Shaik**MSc*
Huda M Al-Khateeb**Ph.D*
Salim R Al-Ubaidy***Ph.D*

Summery:

Background: to evaluate subcutaneous pancreatic transplantation in an experimentally induced diabetes mellitus in golden hamsters.

Methods - many indexes (histological /using two stains, histochemical /using three enzymes, morphometrical and biochemical /blood glucose level) were employed in this assessment. Alloxan was used as β -cytotoxic therapy (to induce diabetes mellitus), and cyclophosphamide was employed as immunosuppressive agent.

Results - high rate of success of transplantation (clearly evident by microscopical features of viable endocrine and exocrine tissue of transplanted pancreas and great tissue vascularization, normal enzymatic activities and significant lowering of blood glucose level) were elicited.

Conclusion – subcutaneous pancreatic transplantation should be thank about in treatment of diabetes mellitus.

Key wards: Pancreatic transplantation, Diabetes mellitus

J Fac Med Baghdad
2006; Vol. 48, No.3

Received Oct 2005
Accepted May 2005

Introduction:

Transplantation therapies have revolutionized care for patients with end-stage organ (kidney, liver, heart, lung and pancreas) failure⁽¹⁾.

During the sixties and seventies, transplantation was usually performed after appearance of organ failure. Few centers, including the University of Minnesota, did transplantation before occurrence of organ damage.

Pancreatic and islet transplantation had been investigated as a treatment for type I diabetes mellitus (DM) in selected patients with inadequate glucose control despite insulin therapy⁽²⁾. The first human islet transplant was done in 1974, eight years after the first pancreatic transplant, in the University of Minnesota. Islet transplantation had been under continuous development since that time, while pancreas transplantation has become routine^(3,4,5). Islet grafts had been transplanted in rodents to different sites (e.g. subcutaneous implant, in the peritoneal cavity, in thymus, injected into liver and under kidney capsule) and comprising different volumes^(2,6,7,8,9).

Several factors, aside from the inadequate organ supply, limit more wide spread transplantation. Despite great improvements in immunosuppressive therapies to prevent acute rejection, chronic graft rejection remains a problem^(10,11,12,13).

Up to our knowledge, trails on pancreatic transplantation are not performed in Iraq previously or done trivially. Therefore the aim of this study was to high light few spots in this respect.

Materials And Methods:

A total of ninety Syrian golden male hamsters (weight = 100 – 120 gm, age = 4 – 6 moths) were used in this study. They were isolated in the “Animal Breeding Center” (of the College of Medicine, University of Baghdad) in a relatively controlled environment at a temperature of about $25 \pm 2^\circ$ C. they were kept at 12 /12 hr.s light / dark cycle and given free access to water and food ad libitum. Lastly, hamsters were categorized into three groups, as shown in table (1).

Table (1): grouping of hamsters.

Group	Subgroup	No.	Notes
Vehicle control	VC	20	Given water only
Experimental	A	35	Given alloxan + cyclophosphamide
	AT	35	Given alloxan + cyclophosphamide + pancreatic transplant

To induce DM, alloxan (specific β -cytotoxin^(14,15,16)) was given in a dose of 100 mg / kg body weight. Alloxan was dissolved in distilled water immediately before use. It was infused intraperitoneally over a period of 10 minutes to a hypoglycemic hamster (animal was starved overnight before infusion)^(17,18) to induce DM in hamsters.

* Dept. of Anatomy, College of Medicine, Univ. of Baghdad

** Dept. of Pathology, College of Medicine, Univ. of Baghdad

On the other hand, 500 mg of cyclophosphamide (immunosuppressive drug) was dissolved in 25 ml distilled water and given in a dose of 0.012 ml /g body weight in single intramuscular injection ⁽¹⁹⁾. Surgical procedure of transplantation involved removing pancreatic tissue (mainly tail region) from donor hamster and its implantation subcutaneously in the diabetic (sister or brother) recipient. Different sites of implantations were tested and different sizes of transplanted pancreas were implanted. Operations were done under Nembutal anesthesia. Transplantation was usually followed by antibiotic cover ⁽²⁰⁾. Each recipient animal was isolated in a sterilized cage with a relatively well controlled environment.

Before sacrifice, hamsters were isolated and subjected to fasting (16 – 18) hr.s. Animals were sacrificed after 1, 2, 3, 4 and 5 weeks (7 experimental and 4 controls / sacrifice). Original and transplanted pancreas was removed. Small piece of liver was removed too (to be used as positive control for the histochemical assessment of the enzymes). Finally, blood samples were collected from the anesthetized hamsters via intracardiac puncture (for blood sugar estimation).

Pancreatic tissue blocks were processed for haematoxylin and eosin (HE) stain ⁽²¹⁾, orange fuchsin green (OFG) stain ⁽²²⁾, lipoprotein lipase (LPL) histochemical study ⁽²³⁾, alkaline phosphatase (ALP) histochemical localization ⁽²⁴⁾ and acid phosphatase (ACP) cytochemical activity ⁽²⁴⁾.

After examination and assessment of pancreatic tissue, morphometrical study was done through calibration of three parameters (diameter and number of the islets of Langerhans and number of pyknotic nuclei / one islet) using an eye piece micrometer (calibrated by a slid micrometer).

The intensity of the final reaction product of LPL, AKP and ACP, in pancreatic tissue, was subjectively estimated by double blind assessment. The range of assessment was 0=no, 1=very weak, 2= weak, 3= moderate, 4= intense and 5= very intense enzyme activity.

Lastly, pancreatic tissue sections were photographed using Olympus microscope with its attached SC 35 camera.

Results were analyzed statistically using “Student-T-test” to compare the significance of differences between two groups mean and “F-test” among three groups ⁽²⁵⁾.

Results:

Hamsters were maintaining good health and well being except subgroup A, which revealed sluggish movements and significant reduction in weight. However, they didn't record any mortality.

Subgroup AT showed 94.28 % survival and 82.85 % successful implantations and didn't elicit any serious complications. No gross or microscopical

differences were seen between different implantation sites. However, smaller implanted piece of pancreas exhibited better survival than larger piece.

Weight changes among the three subgroups were listed in table (2).

Table (2): Revealing body weight changes during the experiment.

Subgroup	First week	Second week	Third week
VC	120 ± 6.8	118 ± 5.9	122 ± 7.0
A	90 ± 4.5*	95 ± 3.6*	90 ± 4.1*
AT	110 ± 1.5*	115 ± 2.8*	116 ± 3.8*

Data are expressed as mean body weight (gm) ± standard deviation

* = Significant at $P < 0.05$

Histologically, pancreas of control hamsters arrayed normal distribution of islet of Langerhans within the exocrine parts. Islets were regular, with well defined boundaries. Their cells had oval to round nuclei, with scattered chromatin granules (Fig. 1).

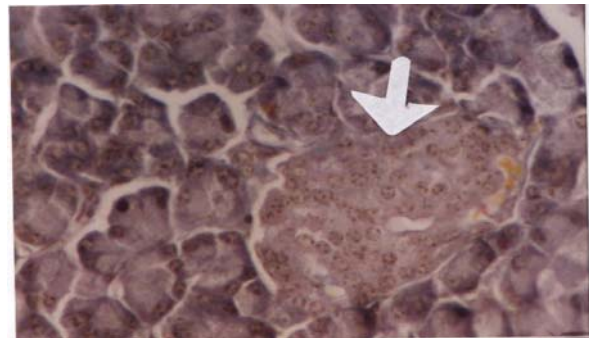


Figure (1): OFG stained section of pancreas of VC subgroup. Note the well defined islet (arrow) (x40)

On the other hand, islets of pancreas of alloxan-treated hamsters elicited marked pyknosis of their nuclei (Fig. 2).

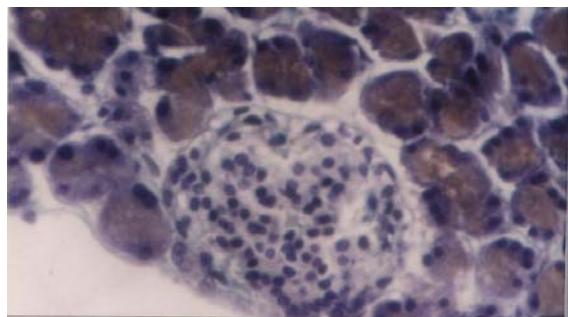


Figure (2): islet of Langerhans of subgroup A hamster (after 3 weeks). Note the pyknotic nuclei (deeply basophilic with reduction in size). (40)

Lastly, the transplanted pancreatic tissue, revealed apparently viable and normal distribution of endocrine part (islets of Langerhans) within the

exocrine part. Islets cells were maintaining well defined boundaries. Scattered chromatin granules within the nuclei were observed one and three weeks after implantation. After five weeks of implantation, the transplanted pancreas remained apparently viable (Figure 3). In addition, the area of implantation displayed great vascularization. Further more, the original pancreas of this group of hamsters was, histologically, identical to those of subgroup A.

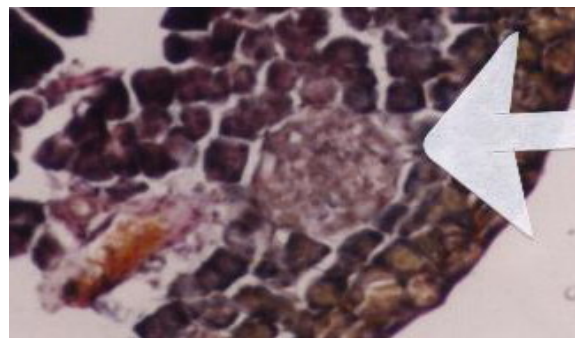


Figure (3): OFG stained section of transplanted pancreas (after 5 weeks). (X40)

Histochemical results were tabulated in table (3,4 and 5)

Table (3): Exhibiting a subjective (double-blind) assessment of LPL histochemical activity among different subgroups of hamsters.

Subgroup	Period (weeks)	Original pancreas		Transplanted pancreas	
		Islets of Langerhans	Exocrine secretory cells	Islets of Langerhans	Exocrine secretory cells
VC	1,3 and 5	0	3		
A	1	0	2*		
	3	0	1*		
	5	0	1*		
AT	1	0	2*	0	2
	3	0	1*	0	3
	5	0	1*	0	3
Liver	1,3 and 5	5	5	5	5

* = Significant at $P < 0.05$

Liver is used as positive control for LPL cytochemical evaluation.

Table (4): Showing subjective (double-blind) assessment of ALP histochemical activity in hamster's pancreas.

Subgroup	Period (weeks)	Original pancreas		Transplanted pancreas	
		Islet of Langerhans	Exocrine secretory cells	Islet of Langerhans	Exocrine secretory cells
VC	1,3 and 5	1	3		
A	1	1	5*		
	3	1	4*		
	5	1	4*		
AT	1	1	5*	1	3
	3	1	4*	1	3
	5	1	4*	1	3
liver	1,3 and 5	5	5	5	5

* = Significant at $P < 0.05$

Liver was employed as positive control for ALP histochemical localization

Table (5): Eliciting double-blind (subjective) assessment of ACP histochemical activity among hamster subgroups.

Subgroup	Period (weeks)	Original pancreas		Transplanted pancreas	
		Islets of Langerhans	Exocrine secretory cells	Islet of Langerhans	Exocrine secretory cells
VC	1,3 and 5	1	3		
A	1	3*	5*		
	3	5*	4*		
	5	1	4*		
AT	1	1	5*	1	3
	3	1	4*	1	2
	5	1	4*	1	3
Liver	1,3 and 5	5	5	5	5

* = Significant at $P < 0.05$

Liver was encountered as positive control for ACP final reaction product evaluation.

Morphometrical data were summarized in table (6 and 7).

Table (6): exhibiting differences in the diameter (μm) of islet of Langerhans in experimental and control hamsters' pancreas.

Subgroup	Islet	1 week	3 weeks	5 weeks
VC	Original	9.2	9.5	9.2
A	Original	7 \pm 0.94*	7 \pm 0.9*	7.5 \pm 0.9*
AT	Original	7 \pm 0.94	7 \pm 0.9	7.5 \pm 0.9
	Transplanted	9.2 \pm 0.8*	9 \pm 0.8*	8.5 \pm 0.7*

Data are expressed as mean \pm standard deviation

*= significant at $P < 0.05$

Table (7): eliciting changes in mean number of islets per low power field in experimental and control groups.

Subgroup	Islet	1 week	3weeks	5weeks
VC	Original	8	7	8
A	Original	4 \pm 4.9*	4 \pm 5.0*	5 \pm 4.8*
AT	Original	4 \pm 4.9*	4 \pm 5.0*	5 \pm 4.8*
	Transplanted	7 \pm 2.9*	8 \pm 3.0*	7 \pm 3.5*

Data are expressed as mean \pm standard deviation

* = significant at $P < 0.05$

Lastly, the data of blood sugar level, in control and experimental hamsters, are listed in table (8).

Table (8): blood sugar level in both experimental and control hamsters.

Subgroup	1week	3weeks	5weeks
VC	110	108	112
A	183 \pm 3.6*	170 \pm 3.7*	175 \pm 3.8*
AT	140 \pm 3.8*	115 \pm 3.0*	120 \pm 4.6*

VC=vehicle control, A=alloxan treated, AT=alloxan and transplantation

Data are expressed as mean \pm standard deviation

*= significant at $P < 0.05$

Discussion:

Male rather than female hamsters were intentionally selected to avoid interference of female sex hormones in the outcome of this study (26).

Animals were fasted before treatment with alloxan because glucose acts as a protective agent against the diabetogenic effect of alloxan (27).

Implanted animals arrayed mild body weight loss, in this investigation. This outcome contradicts previous works (28,29). This controversial result

might be attributed to the use of different diabetogenic agent.

In this study, VC hamsters' pancreas exhibited normal histology, very weak enzymatic activity (especially within islets of Langerhans), average morphometrical data and they showed normal blood glucose level. These results parallel normal structure and function described in standard textbooks^(30, 31).

In this study, the shrinkage of islet of Langerhans size, pyknosis, eccentric accumulation of nuclear chromatin and other signs of necrosis (in the first, third and fifth week after treatment with alloxan), in subgroup A, are in favor of marked cellular destruction within the islets. This result parallels previous studies^(32, 33, 34). Moreover, the significant augmentation of ACP (lysosomal enzyme) activity within the islets tends to assure an increased tissue catabolism and cellular autophagy, which are possible sequences leading to damage of cells⁽³⁵⁾. Furthermore, the significant elevation of blood glucose level (hyperglycemia), in this subgroup, points to the highly destructive mechanism of alloxan to β -cells. Lastly, morphometrical evaluations to islets, of this subgroup, also coincide with the above mentioned outcome. Conclusively, all parameters point to a massive damage of β -cells by alloxan.

Although, the subcutaneous part of the head region is well known to be more vascular than that of abdominal wall⁽³⁶⁾, Yet significant difference were not recorded in the present study. On the other hand, the size of transplanted pancreas seems to be influential. This outcome accords previous work (the smallest the grafted piece, the better survival)⁽³⁷⁾.

Histologically, islets of the transplanted pancreas revealed viable normal outlook, which is rather similar to islets of subgroup VC. Moreover, LPL, ALP & ACP histochemical activities were nearly achieving that of subgroup VC. Furthermore, all quantitative estimations of transplanted islets' morphometry were parallel to those of subgroup VC too. Finally, blood sugar level of transplanted animals was regaining normal values in the third and fifth week. In brief, all parameters (used to evaluate transplanted pancreas) were pointing to a viable and functioning tissue and consequently successful transplantation. These results agree with previous works^(37,38).

Future studies are best directed toward electron microscopical study of transplanted pancreas in addition to comprehensive study to transplanted pancreas for a period longer than five weeks.

References:

1. Harlan M & Kirk D, 1999. "The future of organ and tissue transplantation". *JAMA*, 282(11), 15.
2. Shapiro J, Jonathan R, Ryan E, Korbitt G, Toth E, Warnock G, Kneterman N and Rajotte R, 2000. "Islet transplantation in type I DM using glucocorticoid-free

immunosuppressive regimen". *The New England Journal of Medicine*, 343(4), 230-238.

3. Tormo M, Bailbe D, Serradas P, Saulnier C, Portha B and Campillo J, 1997. "Transplantation of pancreatic islet into rats with STZ induced non-insulin dependent DM". *Adv. Exp. Med. Biol.*, 426, 441-445.
4. Sutherland V, 2001. "Pancreas and islet transplantation". *Voice of diabetic*, 16(3), 1-34.
5. Sutherland V, Cecka M and Gruessner A, 1999. "Report from the international pancreas transplant registry". *Transplant. Proc.*, 31(1-2), 597-601.
6. Van Suylichem P, Strubbe J, Houwing H, Wolters G and Van Schilfgaed R, 1992. "Insulin secretion by rat islet isograft of defined endocrine volume after transplantation to three different sites". *Diabetologia*, 35, 917-923.
7. Gamian E, Kochman A, Rabczynski and Burczak K, 1999. "Evaluation of bioartificial pancreas function made from sodium alginate and poly-L-Lisine microcapsules settled with viable pancreatic islets". *J. Polim-med.*, 29(3-4), 3-20. (Medline)
8. Kae Y, Youson J, Holmes J, Al-Mahrouki A, Sheridan M and Comp G, 1999. "Effects of insulin on lipid metabolism of larvae and metamorphosing landlocked sea Lamprey". *Endocrinol.*, 114(3), 405-414.
9. Tyrberg B, Eizirik D, Marklund S, Olejnicka B, Madsen O and Anderson A, 1999. "human islets in mixed islet grafts protect mouse pancreatic beta-cells from alloxan toxicity". *Pharmacol. Toxicol.*, 85(6), 269-275.
10. Lacy S, 1990. "advances in islet cell transplantation. Is science closer to a diabetic cure?" *JAMA*, 264(4), 25-32.
11. Nagona H, 1997. "chronic allograft failure; the clinical problem". *Am.J. Med. Sci.*, 313, 305-309.
12. Cecka J and Terasaki P (ed.s), 1998. *the UNOS scientific renal transplant registry; ten years of kidney transplants*. In: [Clinical Transplants], 1-15.
13. Monaco A, Burke J and Ferguson R, 1999. "current thinking on chronic renal allograft rejection; issues, concerns and recommendations (review)". *Am. J. Kidney dis.*, 33, 150-160.
14. Jansson L and Sandler S, 1986. "alloxan-induced DM in the mouse; time course of pancreatic beta-cell destruction as reflected in an increased islet vascular permeability". *Protol. Anat.*, 410, 17-21.
15. Murata M, Imada M, Inoue S and Kawanishi S, 1998. "metal-mediated DNA damage induced by alloxan in the presence of NADH". *Free. Radic. Biol. Med.*, 25(4-5), 586-595.
16. Kvist M, Sundler F and Ahren B, 2002. "effect of chemical sympathectomy by means of 6-hydroxy-dopamine on insulin secretion and islet morphology in alloxan-diabetic mice". *Swedish Medical Research Council (grant no. 6843)*. (Medline)
17. Buko V, Lukivskaya O, Nikiti V, Tarasov Y and Zavodnik L, 1996. "hepatic and pancreatic effect of polyenoylphosphatidylcholine in rats with alloxan induced DM". *Cell Biochem. Funct. J.*, 14(2), 131-137.
18. Ohno T, Kitoh J, Yamashita K, Ichikawa Y, Horio F, Terada M and Tanaka S, 1998. "namikawa-t toxin induced insulin dependent DM in the musk shrew". *Life Sci.*, 63(6), 455-462. (Medline)
19. Thomson M, 1994. "immunosuppressive drugs and the induction of transplantation tolerance". *Transplant. Immunol.*, 2, 263-270. (Medline)
20. Sullivan S, Maki T, Kermtt M, Borland M, Mahoney M, Solomon B, Muller T, Monaco A and Chick W, 1991. "Biohybrid artificial pancreas ; long term implantation studies in diabetic pancreatectomized dog". *Science*, 252, 24-29.
21. Stevens A, 1982. *The haematoxylin*. In: Bancroft J and Stevens A (ed.s) [Theory and Practice of Histological Techniques]. 2nd ed., Churchill Livingstone, London, 114-115.
22. Pearse A, 1968. In: [Histochemistry, Theoretical and Applied]. Vol. 1, Little Brown and Co., Boston.
23. Gomori G, 1952. "histochemistry of esterases". *International Review of Cytology J.*, 323-324.
24. Stoward P and Pearse A, 1991. Tween-method for lipase. In: [Histochemistry]. Vol. 3, Churchill Livingstone, 4th ed., 610-611.

25. Danial W, 1988. Hypothesis testing. In: [Biostatistics: A Foundation for Analysis in the Health Science]. Wiley J and sons. London, 161-166.
26. Ling Z, Van de Casteel M and Eizirik D, 2000. *Diabetes*, 49(3), 340-345.
27. Jorns A, Tiedge M, Lenzen S and Munday R, 1999. "effect of super oxide mutase, catalase, chelating agent and free radical scavengers on the toxicity of alloxan to isolated pancreatic islets in vitro". *Free Radic. Biol. Med.*, 26(9-10), 1300-1304.
28. Rajotte R and Thompson A, 1987. "effect of diet on islet cell transplantation". *Diabetes Res.*, 4, 125-130.
29. Tobin B, Holland K and Marchello M, 1997. "pancreatic islet transplantation improves body composition, decreases energy intake and normalizes energy efficiency in previously diabetic female rats". *J. Nutr.*, 122(6), 1191-1197.
30. Janqueira L and Carineiro J, 2003. The female reproductive system. In:[Basic Histology]. 10th ed., Lange International ed., 465-467.
31. Ganong W, 1993. Development and function of the reproductive system. In: [Review of Medical Physiology]. 16th ed., Lange medical books, 411-412.
32. Adeghate E, 1999. "effect of subcutaneous pancreatic transplantation on streptozotocin-induced DM in rats". *Tissue cell*, 31(1), 84-89. (Medline)
33. Adeghate E and Parvez S, 2000. "nitric oxide and neuronal and pancreatic beta-cell death". *Toxicology*, 153(1-3), 143-165.
34. Peschke E, Ebel H, Bromme H and Peschke D, 2000. *Cell Mol. Life Sci.*, 57(1), 158-164. (Medline)
35. Mansour H, Newairy A, Yousef M and Sheweita S, 2002. "biochemical study on the effects of some Egyptian herbs in alloxan-induced diabetic rats". *Toxicology*, 170(3), 221-228.
36. Gray H, 1994. the pancreas. In: [Anatomy ; Descriptive and Surgical]. 5th ed., Finland Wsoy, 929-935.
37. Orloff L, Orloff M, Orloff S and Surg A, 1999. "lifelong prevention of mesangial enlargement by whole pancreas transplantation in rats with DM". *Anug.*, 134(8), 889-897.
38. Gainer A, Suarez P, Min W and Swiston J, 1998. "improved survival of biolistically transplanted mouse islet allografts expressing CTL A4-Ig or soluble fas ligand ". *Transplantation*, 66(2), 194-199.