

Histological and Histochemical changes in diabetic male rat liver and intestine: and protective effect of cinnamon oil.

Mahera N. AL – Shaikh * BSc, PhD

Summary:

Background:The diabetogenic agent alloxan is a selective necrosis of insulin producing cells .Alloxan accumulated rapidly in liver and pancreatic islets , this study was carried out to evaluate the antidiabetic effect of cinnamon oil on the destructive effect of alloxan in liver and intestine diabetic tissues .

Materials and methods:Thirty male rats were used and divided into threegroups: Group I =10 animal controls, Group II =10 treated with alloxan, Group III = 10 treated with alloxan + cinnamon oil .

Results:Liver and intestine tissues of diabetic groups revealed necrotic, degeneration of cells (histologically) , increase in blood serum enzymes for acid and alkaline phosphatase , total protein ,cholesterol and triglycerides (biochemically) , and increase in the activity of acid and alkaline phosphatase in liver and intestine tissues (histochemically). While diabetic group treated with cinnamon oil revealed decrease in all these parameters.

Conclusions: Oral administration of cinnamon oil produce significant hypoglycemic effect restores liver function and normalize the histological, histochemical and biochemical abnormalities caused by diabetes in alloxan induced diabetic rats, this may be due to antioxidant effect of this herb.

Keywords: liver, intestine, Diabetes mellitus, Cinnamon oil, Acid phosphatase, Alkaline phosphatase

Fac Med Baghdad
2010; Vol. 52, No. 3
Received Feb., 2010
Accepted June. 2010

Introduction:

Diabetes mellitus a complex syndrome is characterized primarily by the imbalance in blood glucose homeostasis leading to hyperglycemia and series of secondary complications caused by an absolute or relative lack of insulin. In conventional theory, type I diabetes is treated with exogenous insulin and type II with oral hypoglycemic agents (1). Many of the oral antidiabetic agents have a number of serious adverse effects, thus, managing without any side effects is still a challenge. Therefore, the search for many effective and safer hypoglycemic agents has continued to be an important area of investigation. Besides drug classically used for the treatment of diabetes (insulin, sulphonylureas, biguanides and thiazolidinediones), several species of plants have been described in the scientific and popular literatures having a hypoglycemic activity and this activity may be due to its antioxidant properties (2), flavonoids are commonly found in all plants and also possess hypoglycemic and antidiabetic activities (3). Because of their perceived effectiveness, minimal side effects in clinical experience and relatively low cost, herbal drugs are prescribed widely even when their biological active compounds are unknown. Insulin deficiency leads to various metabolic aberrations in the animals mainly increased blood glucose, decreased protein , increase levels of cholesterol and triglycerides (TG), increase in the activity of serum alkaline (ALP) and acid (ALP) phosphatase , serum Glutamate Oxaloamino Transferase (SGOT) indicate liver dysfunction in

diabetes (4) , Ohaeri 2001 (5) also found that liver was necrotized in STZ- induced diabetes rats . Although cinnamomum zeylanicum has been used as folklore medicine all over the world. Yet scientific validations of its hypoglycemic and hepatoprotective properties need to be established. Hence this study was undertaken to evaluate the hypoglycemic and restoration of normal liver functioning activity of cinnamon in alloxan – induced diabetic rats.

Materials and Methods:

Male albino rats of wistar strains, weighing about 150-200 gm. From animal breeding center – college of medicine – university of Baghdad. All animals were kept and maintained under laboratory conditions of temperature 25 C⁰ and 12 hr.day, 12 hr. night cycle and were allowed free access to food and water ad libitum .Diabetes was induced by a single dose of 100 mg / kg (body weight) intraperitoneally injection of alloxan monohydrate (BDH chemicals Ltd ,England , product no. 4201) dissolved in D.W. immediately before use and infused over a period of 10 min. to overnight fasted animals (6) , because glucose is known to protect the beta cell and prevent the superoxide derivative , which cause the cell damage (7) the rats were kept for the next 24 hr. on 5% glucose solution bottles in their cage to prevent hypoglycemia (8). After fortnight rats with moderate diabetes having hypoglycemia with blood glucose range of 250-300 mg/dl , were used for this study .

The animals were divided into 3 groups of 10 each. Group I served as normal control rats received only distilled water during the experimental period.

* *Department of anatomy, Medical Biology, Medical College, Baghdad University*

Group II was the untreated diabetic control group. Group III diabetic rat were once daily treated with cinnamon oil 0.2 mg / kg B.W. (9) . The treatment was continued for 60 days. The rats were sacrificed at the 14,28,42,56 days after induction of diabetes, small pieces of liver and intestine was removed and divided into 2 parts, one for the histological studies and the other for histochemical studies.

Histological study:

The pieces of liver and intestine tissues immediately fixed in 10 % formaldehyde, the specimens were dehydrated in ascending grades of ethanol, cleared with xylene and embedded in paraffin wax , sectioned to get 5 µm sections , and stained with haematoxylin – eosin stain (H & E) and periodic acid shiff (PAS) stain .

Histochemical study:

Another part of each of liver and intestine tissues were fixed in 2 % paraformaldehyde, the lead method after Gomori 1952 (10) was used for cytochemical localization of acid (ACP) and alkaline (ALP) phosphatase. Black precipitate indicated the sites of the enzyme.

Biochemical study:

Blood was obtained through intracephalic puncture, then serum was separated by centrifugation and sent to the biochemical test for blood sugar, total protein, cholesterol, triglycerides acid and alkaline phosphatas.

Statistical analysis was done by using ANOVA and students – test. Data expressed as ±SD statistical significance was defined as P<0.05.

Results:

Blood glucose level was significantly (P<0.05) elevated in alloxan – induced diabetic rats as compared with control rats. Oral administration of cinnamon oil during 60 days showed significant (P<0.05) reduction in glucose similar to the normal when compared with diabetic control animals, as shown in Table I.

Table I: effect of cinnamon oil on serum glucose of control and experimental rats

Parameters	Group I Control	Group II Diabetic	Group III Diabetic +Cinnamon oil
Serum glucose	98.33 ± 2.6	302.67 ±2.35*	106.67±4.2*
Mg/dl			

Results are expressed as mean ± SD ; * significant at P<0.05

The histopathological (heamatoxyline & eosin stain) examination of diabetic rats showed necrosis of the hepatic cells , degeneration, vaculation in hepatic cells in comparison to that of normal rats (Fig. 1 : A&B) .

In diabetic groups treated with cinnamon oil indicated that hepatic lobules appear more or less like normal parenchymal hepatic tissue structure.

Regeneration and hyperplasia of hepatic cells are indicated by cell division (Fig.1C).

The histochemical examination of diabetic rats stained with periodic acid Schiff (PAS) technique showed pericentral depletion of PAS +ve materials. While in diabetic rats treated with cinnamon oil there was well distribution of polysaccharides in the hepatocytes that appeared more or less like normal control (Fig.1: D&E). On the other hand histopathological (heamatoxyline & eosin stain) examination of diabetic rats showed mucosal sloughing, degeneration of mucosal villi, shortness of intestinal villi as compared with normal control tissues , while diabetic groups treated with cinnamon oil revealed regeneration of epithelial mucosa hyperplasia of goblet cell (Fig.II : a,b&c) .

The effects of cinnamon oil on diabetic rats liver serum enzymes, acid phosphatase, alkaline phosphatase, and total protein are given in table II.

Table II: Effect of 60 days treatment of cinnamon oil on enzymes, acid phosphatase (ALP), alkaline phosphatase(ALP) , and total protein in alloxan-diabetic male Wister rats .

Parameters	Normal Control N	Diabetic Control D	Diabetic +Cinnamon oil (DC)
ACP IU/L	5.88 ±1.7	9.23 ±2.0*	6.56 ± 2.2*
ALP IU/L	17.93 ± 1.2	22.19 ±0.6*	8.62 ± 1.4*
Total protein	120 ± 1.7	178 ± 0.5*	124 ±0.5*

Results are expressed as mean ± SD ; * significant at P<0.05

Levels of cholesterol and triglycerides showed a significant increase in blood serum (as shown in table III) in alloxan diabetic groups when compared with control groups .

Tale III: Effect of alloxan and cinnamon oil on cholesterol and triglycerides in experimental animals.

Parameters	Normal Control N	Diabetic Control D	Diabetic +Cinnamon oil (DC)
Triglycerides Mg/dl	78.5 ± 2.5	114.33 ± 6.7*	90 ± 2.2*
Cholesterol Mg/dl	94.5 ± 2.1	190.33± 3.2*	118.66 ± 3.3*

Results are expressed as mean ± SD ; * significant at P<0.05

Discussions:

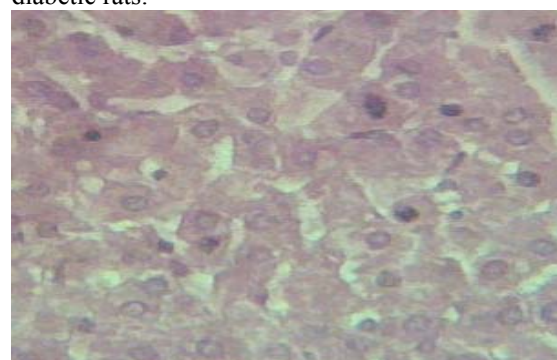
Alloxan has been observed as rapidly and selectively acting on pancreatic beta cells (11) and is known to induce DNA strand breaks in isolated rat pancreatic islets (12), also cause massive reduction of the β-cells of islet of Langerhans induce hyperglycemia ,and elevation of local free radicals in β-cell after increasing free radicals in other body organs (13) . An observation in this study correlates with the previous research findings about elevation of Blood glucose level in alloxan – induced diabetic rats , and

a reduction in this level after oral administration of cinnamon oil during 60 days as shown in Table I. Several researches have reported that flavonoids (oil) have hypoglycemic, hypolipidemic and hypocholesterolaemic effects (14). From our results, it can be assumed that the flavonoids might be responsible for the hypoglycemic effects of cinnamon oil. It is not clear now, how cinnamon oil cures diabetic rats under hypoglycemic condition, so we suggested that, the mechanism may be through the stimulation of beta cells for elevated secretion of insulin, thereby increasing the utilization of glucose in various tissues, and this agrees with previous workers (15), or the oil may act as insulin substitutes, or the cinnamon oil causes increase in the glucose transport across the cell membrane, which is reduced by alloxan in rats (20). It has been well established that diabetes mellitus alters the normal metabolism of tissues like liver, kidney and heart (16). The histopathological (hematoxyline & eosin stain) examination of diabetic rats showed necrosis of the hepatic cells, degeneration, vaculation in hepatic cells in comparison to that of normal rats (Fig1: A&B). These results are in agreement with Buko (17) who reported that the diabetic liver rats characterized by hydropic dystrophy and lymphocytic infiltrations. These damages may be due to oxygen free radicals (OFR) exerting their cytotoxic effect by peroxidation of membrane phospholipids leading to a change in permeability and loss of membrane integrity. Decreased endothelium- dependent relaxation in diabetes is linked to release of OFRs. Hyperglycemia causes increased production of OFRs, during diabetes, from glucose oxidation and protein glycosylation (18). The level of total protein in serum decreased in diabetic groups when compared to those of normal control, while it increased in diabetic rats treated with cinnamon oil compared to those of diabetic rats. Distinct metabolic renal alterations lead to a negative nitrogen balance, enhanced proteolysis and lowered protein synthesis in experimental diabetes (19). The reversal of the changes by cinnamon oil may be proved that the insulin deficiency had been corrected. Serum protein never deviated from the normal range throughout the treatment period in cinnamon treated diabetic rats, so the oil may act as anabolic effects, and this agrees with previous studies, or by enhancing the synthesis of certain proteins in rat liver and increasing the body weight in human (20). Histochemical studies to ACP & ALP in livers tissue treated by alloxan are shown in (FigIII: a, b, c&d). Those for intestinal tissue are shown in (Fig.IV: a, b, c&d). Enzymes in intestinal tissue, increased significantly in comparison with normal control rats. These changes are directly related to changes in metabolism in which the enzymes are involved. The restoration of acid and alkaline phosphatase in liver tissue and ACP & ALP enzymes in intestinal tissue compared with normal tissue, was observed in cinnamon treated diabetic groups, these findings come out with

previous studies by Udayakumar et al., 2009 (20). Increase activities of serum enzymes in alloxan diabetic animals caused lipid peroxide mediated tissue damage in the pancreas, liver, kidney and heart (21). The increase in the level of these enzymes in diabetes may be due to liver dysfunction as result of the leaking out from the tissues and then migrating into the blood serum (22) which gives an indication on the hepatotoxic effect of alloxan, and also cause cell damage by altering cell membrane architecture, which results in enhanced activities of ACP, ALP in diabetic rats (20). Treatment of alloxan-diabetic rats with the plant oil (flavones) caused reduction in the activity of serum ACP & ALP enzymes compared to the diabetic groups and consequently may alleviate liver damage caused by alloxan – induced diabetes. These findings agree with those obtained by EL-Demerdash et al. 2005 (23). The abnormal high concentration of serum lipids is mainly due to increase in mobilization of free fatty acids from the peripheral fat deposits, because insulin inhibits the hormone sensitive lipase production. However on treatment with cinnamon oil it decreased significantly and improved the diabetic status including protection of DNA against oxidative damage, hypocholesterolemic effect (24). These results are in agreement with Anderson et al., 2004 (25) which revealed that the polyphenolic, polymers, anthocynins, found in cinnamon functions as antioxidants, potentiate insulin action and may be beneficial in the control of glucose intolerance and diabetes. As a strategy to counteract the negative effect of oxidative stress, antioxidant-based therapy is promising to minimize the complications associated with oxidative stress in diabetes mellitus. In other hand many of these complications are diminished with certain dietary antioxidants such as vitamin E, C and lipoic acid (25). The use of other non – nutrient antioxidants such as flavonoids and polyphenol has been reported with the same advantage (27).

Conclusions:

Present findings show that oral administration of cinnamon oil produce significant hypoglycemic effect, restores liver function and normalized the histological, histochemical and biochemical abnormalities caused by diabetes in alloxan induced diabetic rats.



A

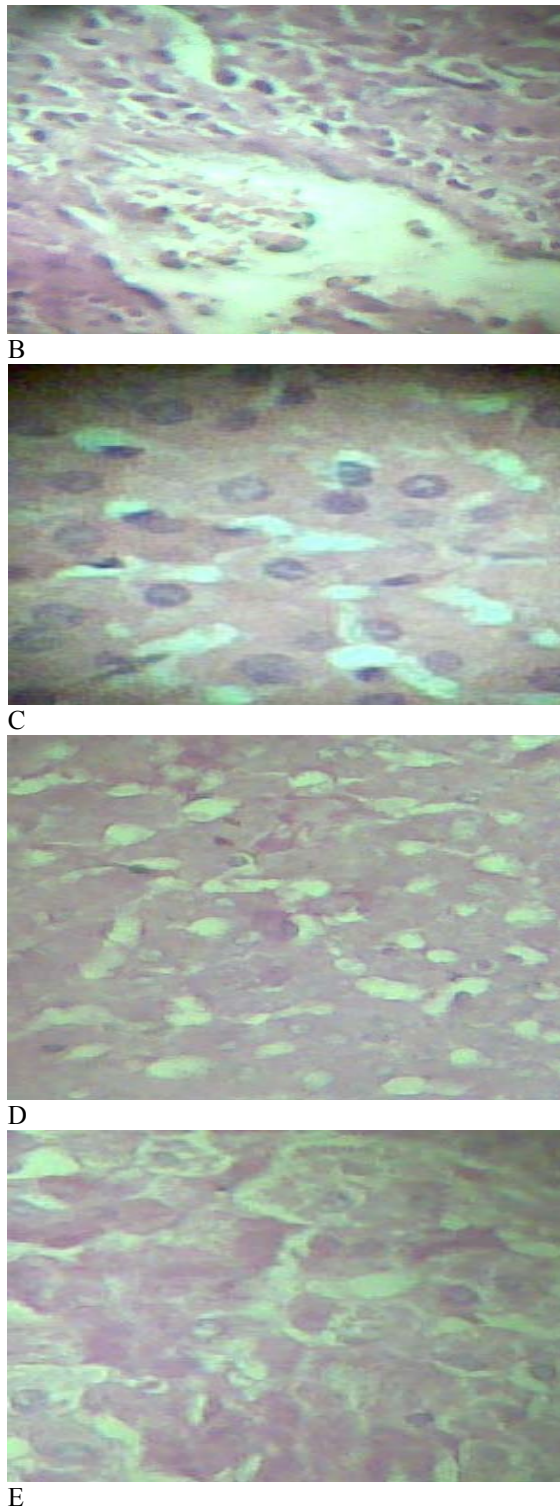


Fig. I: Sections in liver tissues showing: A- Normal parenchymal hepatic (H& E stain) 400 X., B - Alloxan – diabetic group, showing necrotic, vacuolated cells, (H&E), 400X., C- : Rat's treated with cinnamon oil , showing normal tissue looking , regeneration of parenchymal cells , hyperplasia (cell division, indicated by the pointer), (H&E), 400X., D - Alloxan treated animal, showed necrosis and vacuolated of hepatocytes (→) PAS stain, 400 X. , E - Tissue of diabetic rats treated with cinnamon oil showed the distribution of polysaccharides in the hepatocytes .(PAS stain) , 400X.

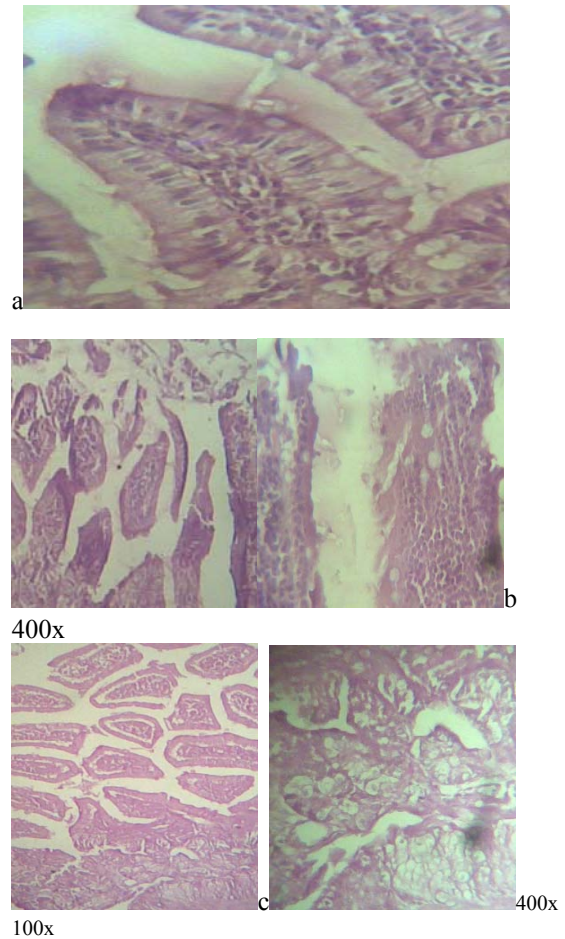


Fig.II: Sections of rat's intestinal mucosa showing : a -Normal looking villi (H&E stain), 200X., b - Rat treated with alloxan, showing surface mucosa sloughing and degeneration of intestinal villi, (H&E stain) , c – Rat treated with alloxan + cinnamon oil , showing regeneration of villi , hyperplasia of goblet cell , (H&E) .

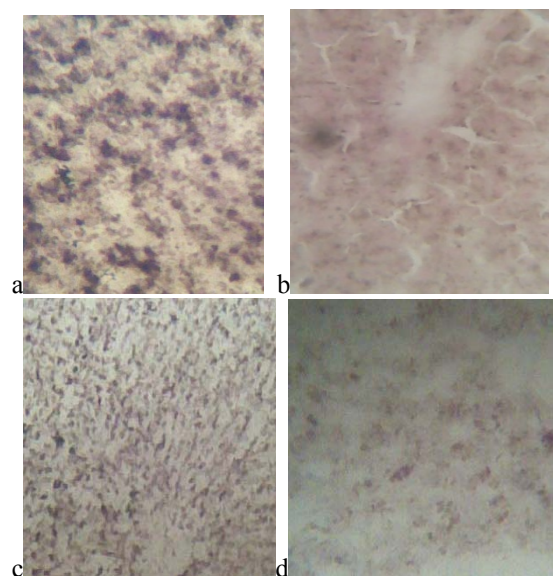


Fig. III: Acid phosphatase activity in hepatocytes in, a: alloxan- induced diabetic animals(200x), b: diabetic animals treated with cinnamon oil , 400X .

Alkaline phosphatase activity in hepatocytes in , c :
alloxan – induced diabetic animals (200x d: diabetic
animals treated with cinnamon oil , 400X.

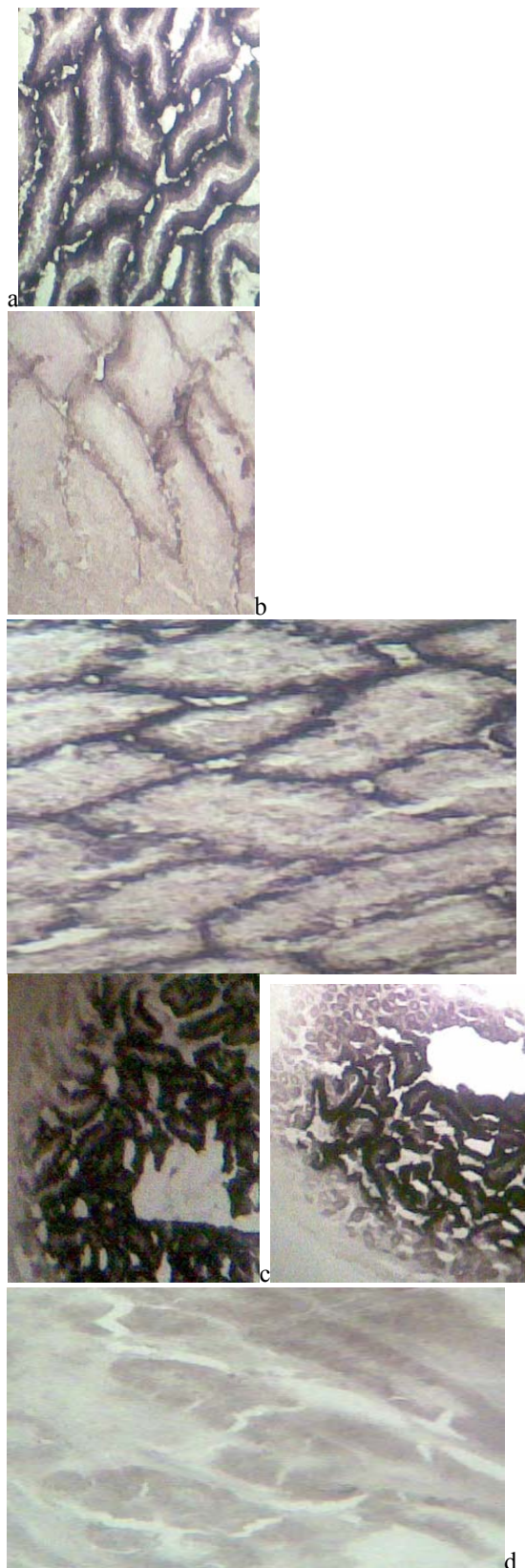


Fig. IV: Acid phosphatase activity in small intestinal tissue in, a: alloxan- induced diabetic

animals(200x), b: diabetic animals treated with cinnamon oil , 400X .

Alkaline phosphatase activity in small intestinal tissue in, c: alloxan – induced diabetic animals(100x), d : diabetic animals treated with cinnamon oil, 400X .

References:

- 1- Rosak C,2002 . When diet and oral antidiabetics are no longer enough. Optimal management of the diabetic patient with insulin MMW Fortschr Med., 144:28-34.
- 2- Colca J R,2006. Insulin sensitizers may present metabolic inflammation. Biochem.Pharmacol.72:125-131.
- 3- Sharna B ; Viswanath G .;Salunke R : Effect of flavonoid – rich extract from seeds of *Eugenia gambolana* (L .) on carbohydrate and lipid metabolism in diabetic mice . Food Chem.2008, 110 , 697-705.
- 4- Huseini H F , B. Lanrijani R, Heshmat H , Fakhzadeh B ,Radjabipour T Toliat and M Raza ,2006: The efficacy of *Silybum marianum*(L.) Gaertn (silymarin) in the treatment of type II diabetes . A randomized double- blind, place bo-controlled. Clinical trial Phytother Res. ,20, 1036-1039 .
- 5- Ohaeri O C, 2001 : Effect of garlic oil on the level of various enzymes in the serum and tissue of streptozotocin diabetic rats . Biosci.Resprod.21:19-21.
- 6- Ohno T; Kitoh j ; Yamashita K ; Ichikawa Y ; Horio F 1998 : Toxin – induced IDDM (insulin dependent diabetes mellituse) in the musk shrew , Life – Sci . ; 63 (6) : 455-62 .
- 7- Martens G A Y ; Cai S; Hinke G ; Stange M V; Castele and Pipeleers , 2005: Glucose suppresses superoxide generation in metabolically responsive pancreatic β - cells . J . Biol . Chem. 280: 20389-20396 .
- 8- Prince P S M ;Menon V P ;Pari L : Hyperglycemic activity of *Syzigium cumini* seeds : effect on lipid peroxidation in alloxan diabetic rats . J.Ethnopharmacol 1998 , 61 , 1-7.
- 9- Foster L A , 1996 : Encyclopedia of common natural ingredient used in food . Drugs and consmetics . 2nd ed. New York . NY : Joh wiely & sons 163.
- 10-Gomori g , 1952 : Histovhemistry of esterases . International Review of cytology J.p. 323.
- 11-Elsner M ; Gurgul – Convey E and Lenzen S , 2006 : Relative importance of cellular uptake and reactive oxygen species for the toxicity of the alloxan and dialuric acid to insulin producing cells . free Radic . Biolo . Med . 41 : 825-834 .
- 12-Okamoto , H, 2005 . Molecular basis of experimental diabetes . Degeneration, -,Bio.Essays. 2:15-21.
- 13-Muruganandan, S ; Gupta M ;Kataria J I; Gupta O K , 2002 : Mangiferin protects the streptozotocin-induced oxidative damage to cardiac and renal tissues in rats . Toxicology, 15:165-173.

- 14-Babu P S ; Prabuseenivasan S ; Ignacimuthu S , 2007: Cinnamaldehyde-A potential antidiabetic agent . *Phylomedicine* 14 , 15-22.
- 15-Prakasam S ; Sethupathy and Pugalendi K V , 2002 : Antihyperglycemic effect of *Caseariaesculenta* root extract in streptozotocin induced diabetic rats . *Pharmazie* . 57, 11.
- 16-Leite A C R ; Ara'ujo T G ; Carvalho B M ; Silva N H ; Lima V I M ; Maia M B S , 2007 : Parkinsonia aculeate aqueous extract fraction : Biochemical studies in alloxan – induced diabetic rats . *J. Ethnopharmacol.* , 111 , 547-552 .
- 17-Buko V O ; Bukivskaya v ; Nikitin Y; Tarasov L ; Zavodnik A ; Borodinsky B Corenshtein , 1996 : Hepatic and pancreatic effect of polyenoylphosphatidylcholine in rats with alloxan-induced diabetes . *Cell . Biochem. Funct.* Jun. , 14(2) 131-7.
- 18-Tesfamariam B , 1994 : Free radicals in diabetic endothelial cell dysfunction . *Free Rad. Biol . Med.* , 16 : 383-91.
- 19-Pathak A ; Dhawan D , 1998 : Effect of lithium on the levels of blood urea and creatinine in diabetic rats . *Med . Sci. Res.* 26 , 855 .
- 20-Udayakumar R , Kasthuriangan S , Salammal T , Rajesh M , Ramesh A , Chang Kim S ; Ganapathi A and Choi C , 2009 : Hypohlycemic and hypolipidemic effects of *Withania somnifera* root and leaf extract on alloxan – induced diabetic rats . *Int. J. Mol.Sci.* , 10, 2367-2382 .
- 21-Prince P S M ; Meno V P L , 1997 : Effect of *Syzigium cumini* extracts on hepatic hexokinase and glucose-6-phosphatase in experimental diabetes . *Phytother . Res.* , 11, 529-531.
- 22-Prince P S M ; Meno V P L , 2000 . Hypoglycemic and other related actions of *Tinospora cardifolia* roots in alloxan – induced diabetic rats . *J . Ethnopharmacol* , 70 , 9-15 .
- 23- El-Demerdash E M ; Yousef M I and El-Naga N I , 2005 : Biochemical study on the hypoglycemic effects of onion and garlic in alloxan-induced diabetic rats . *food Chem. Toxicol* , 43 , 57-63 .
- 24- Thresa E ; Christieand C ; Andrea R , 2004 : Streptozotocin – induced diabetes impairs Mg²⁺ homeostasis and uptake in rat liver cells *American J. physiology* . 49 (2) : pp. E 184 – E 193 .
- 25- Anderson R A ; Broadhurst C L ; Polansky M M ; Schmidt W F ; Khan A ; Flanagan V P ; Schoene N W ; Graves D J , 2004 : Isolation and characterization of polyphenol type – A polymers from cinnamon with insulin- like biological activity *J. Agric . Food Chem.* , 52 : 65-70 .
- 26- Davie S J ; Gould B P ; Yudkin J S , 1992 : Effect of vitamin C on glycosylation of proteins . *Diabetes* 41 : 167-173 .
- 27- Asgary S G A ; Naderi N; Sarraf R; Zadegan R; Vakilt R , 2002 : The inhibitory effects of pure flavonoids on in vitro protein glycosylation . *Journal of herbal pharmacotherapy* , 2: 47-55 .