

- Lukacs JR, and Hemphill BE (1993) Odontometry and biological affinity in south Asia: analysis of three ethnic groups from northwest India. *Hum. Biol.* 65(2):279-325.
- Mehrotra MC (1966) Impacted mesiodens and maxillary central incisor with cyst formation. *J. All-India Dent. Assoc.* 38(2):41.
- Millhon JA, and Stafne CC (1941) Incidence of supernumerary and congenitally missing lateral incisor teeth in 81 cases of harelip and cleft palate. *Am. J. Orthodont.* 37:599-604.
- Morley KR, and Tompson BD (1983) The palatally impacted mesiodens. *J. Can. Dent. Assoc.* 49(8):571-574.
- Niswander JD, and Sujaku C (1963) Congenital anomalies of the teeth in Japanese. *Am. J. Phys. Anthropol.* 27:569-574.
- Pal A (1964) Observations on the dentition of the crania from eastern India. *Anthropol. Surv. of India. Bull.* 12(1/2):9-18.
- Perry RR, and Iyer VS (1961) Supernumerary teeth amongst orthodontic patients in India. *Brit. Dent. J.* 111:257-258.
- Pindborg JJ (1970) *Pathology of the Dental Hard Tissues.* Copenhagen: Munksgaard.
- Primosch RF (1981) Anterior supernumerary teeth -- assessment and surgical intervention in children. *Pediatr. Dent.* 3:204-215.
- Rao (1953) Aberrant canine tooth in the nose. *J. Laryngol. Otol.* 67:370-371.
- Reddy VR (1982) Incidence of supernumerary teeth among the people of Gulbarga, Karnataka. *J. Karnatak University-Social Sciences.* 27:99-110.
- Reddy VR, and Vijaykumar M (1978) Caries and some dental features among the Vysyas of southeastern Andhra Pradesh. *Acta Anthropogenetica.* 2(3):63-72.
- Reddy VR, Vijaylaxmi PB, and Reddy BCK (1981) Some dental features of the Muslims of southeastern Andhra Pradesh. *Antropologia Contemporanea (Italy).* 4(3/4):275-282.
- Rosenzweig KA, and Garbaski D (1965) Numerical aberrations in the permanent teeth of grade school children in Jerusalem. *Am. J. Phys. Anthropol.* 23:277-283.
- Scott JH, and Symons NBB (1989) *Introduction to Dental Anatomy.* (ninth edition). Edinburgh: Churchill Livingstone.
- Sedano HO, and Gorlin RJ (1969) Familial occurrence of mesiodens. *Oral Surgery.* 27:360-362.
- Shapiro SD, and Farrington FH (1983) A potpourri of syndromes with anomalies of the dentition. In RJ Jorgensen (ed): *Dentition: Genetic Effects.* New York: Alan R. Liss, pp. 129-140.
- Sinha DK, Kumar S, and Lall B (1986) Tooth in the nose. *J. Indian Med. Assoc.* 84:318-319.
- Stafne EC (1932) Supernumerary teeth. *Dent. Cosmos.* 74:653-659.
- Stermer-Beyer-Olsen EM (1989) Premaxillary hyperdontia in medieval Norwegians: a radiographic study. *Dentomaxillofacial Radiol.* 18(4):177-179.
- Sutton PR (1985) Tooth eruption and migration theories: can they account for the presence of a 13,000-year-old mesiodens in the vault of the palate? *Oral Surg. Oral Med. Oral Pathol.* 59(3):252-255.
- Takei T, Hamada N, Toh H, and Ohmori T (1989) The dental anthropological study on the erupted mesiodens in the Paiwan tribe of Formosan aboriginals. *Fukuoka Shika Daigaku Gakki Zasshi.* 16(1):44-51.
- Tay F, Pang A, and Yuen S (1984) Unerupted maxillary anterior supernumerary teeth: report of 204 cases. *J. Dent. Child.* 51:289-294.

## DENTISTRY IN ANCIENT EGYPT: JUNKERS' TEETH

PIERRE-FRANCOIS F. PUECH

*Laboratory of Odontology and Cranio-Facial Anthropology of Marseille La Timone; Laboratory of Prehistory of the Museum of Man in Paris; B.P. 191, 30012 Nîmes, France*

**ABSTRACT** The earliest known example of dental ligature was excavated from the Egyptian site of Cheops by Junker. Made of gold, the wire unites two molar teeth. For comparative purposes, we present two other molar teeth with the same occlusal wear surface. The teeth came from an Egyptian mummy recently autopsied.

### INTRODUCTION

Dentistry may be defined as the art or practice of treating dental injuries and disorders by manual operation or instrumental appliances. Direct archaeological evidence of the occurrence of dentistry in ancient Egypt tends to excite rivalry between advocates of effective methods of dental treatment and those who believe that the exhibited evidence are the result of wishful thinking. Such partisanship is largely prejudiced, since both are present. While arguments against human intervention in the case of bone holes which accompany abscess formation are convincing (Leek, 1967), at least one case, known as "Junkers' teeth," is to be accepted (Fig. 1).

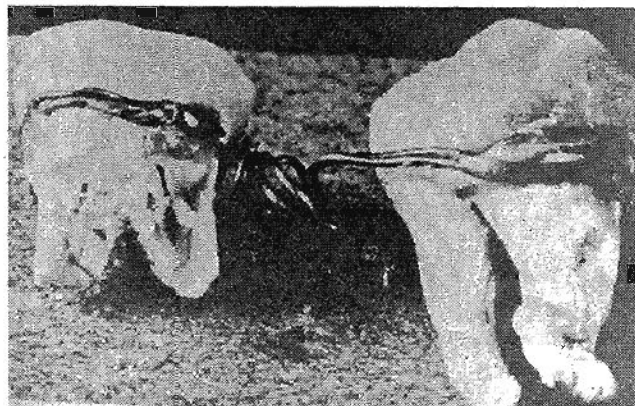


Fig. 1. The "Junkers' teeth," 1929.

### HISTORY

The three Giza pyramids of Mycerinus, Chephren and Cheops dominate the view at the edge of modern Cairo. These great ancient funerary monuments stand as an awesome reminder of the power of the pharaohs. A city of tombs arose around each pyramid. Each was used by members of the royal family or by a family promoted by the pharaoh.

## JUNKERS' TEETH

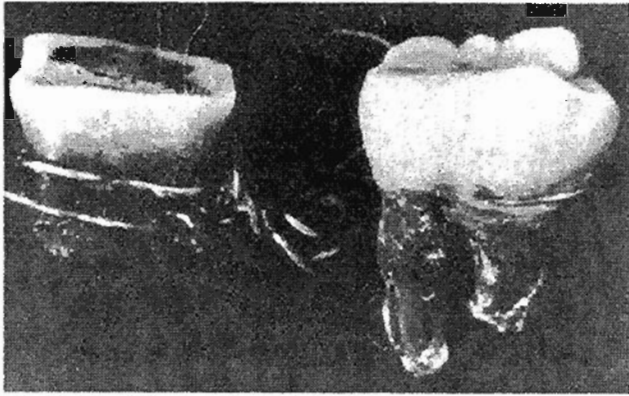


Fig. 2. The "Junkers' teeth," 1976.

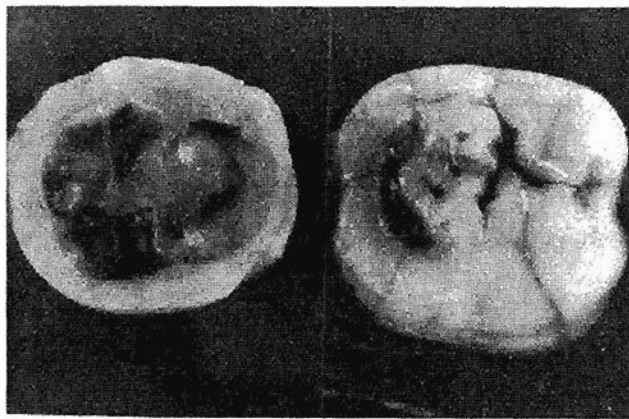


Fig. 3. The Lyons' teeth, 1985.

Systematic excavation of the Western Cemetery of Cheops' pyramid was begun in 1902. One of the expeditions was fielded by the University of Leipzig, and later transferred to the Akademie der Wissenschaften of Vienna and the Roemer-Pelizaues Museum, Hildesheim, Germany, represented by Professor Hermann Junker. Junker recovered many human remains, which included two lower molar teeth from Tomb 984 dated at approximately 2500 BC.

These teeth were originally reported by Junker in 1914. He noted (p. 31) that this strange discovery evidenced a will to conserve as much as possible of the corpse intact. The two teeth were artistically held together with a thin gold wire, in such a manner as to hold a mobile tooth to a strong close one. Perhaps this man had this artifice installed in life. These teeth had been found in the mortuary chamber of the "Nile mud head reproduction."

### DESCRIPTION

In 1975, F. Sallou published his report after reuniting the six bits of the 0.4 mm gold wire. He established the presence of an innate gap between the two teeth that corresponded with the fact that the two teeth were not in direct contact when the wire was modeled. The roots of the teeth had been broken postmortem. In putting the tightening knot against the proximal face of the molar, in a neutral space, the operator acted as a clinical surgeon.

What was the desired action of such an artifact? The lid has, it seems, been reopened recently by Becker (1994) on a controversy about whether the ancient Egyptians performed operative dentistry. A misunderstanding of the observations made by Quenouille in 1977 has been used in an attempt to "demonstrate" the non-existence of the dental appliance from the Old Kingdom. Contrary to the statement by Becker, Quenouille (1977) has affirmed that "in my own opinion, a real possibility exists of an in-vivo utilization...of the Junker teeth ligature..."

Enlarging the description so that all can understand the special case of "Junkers' teeth" now seems necessary. Along this line, the analysis requires comparative data. We have Egyptian skeletal material suitable for comparison. In 1985 in Lyons, France, a team of medical experts, led by the Egyptologist J.-C. Goyon, undertook a minute examination of an anonymous mummy. I had the opportunity to observe the teeth, to make scanning electron microscopic examinations of dental wear, and to do comparisons to previous studies on similar material (Puech, 1987; Puech et al., 1983). The main objective of the project was to assess the mummy in exacting detail, with a view to analyzing every action of the embalmers, both in terms of the physical preparation of the body and in the wrapping of the prepared corpse. The body of the man was well preserved. He was probably around forty years old at death, of slender build, and had badly worn teeth. The molar teeth had an occlusal wear grade very similar to "Junkers' teeth" (Figs. 2 and 3).

In a first antemortem sequence, the mummy had lost the upper and lower first molars and mesioversions of the second and third molars, followed by an opening of the space between those teeth. Heavy usage of one of the two remaining teeth had led to heavy wear and periodontal problems. In a second antemortem sequence, loss of one of the antagonist teeth of the most altered tooth decreased the occlusal stress and made possible a prolonged presence.

### DISCUSSION AND CONCLUSION

Judging from the comparable condition of occlusal wear in the two cases, we may conclude that owner of the "Junkers' teeth" likely had missing and displaced teeth. Unfortunately, in the absence of details concerning the dentition of the Junker specimen, we have to present a mixture of analysis and narrative logic. However,

## JUNKERS' TEETH

Junker's hypothesis about a gold wire to hold a mobile tooth, maybe during life, is strengthened by the condition of the Lyons' mummy. According to this hypothesis, the ligature was an attempt to provide a better condition for a mobile tooth that had lost the possibility of an occlusal load during mastication. The major objection to this hypothesis of dental treatments is its poor efficiency, but one might quote the phrase from John Hunter, the founder of modern surgical pathology in the mid-1780's: "but why think, why not try the experiment?" (Palmer, 1835).

### LITERATURE CITED

- Becker MJ (1994) Spurious "examples" of ancient dental implants or appliances, part two of a series. *Dental Anthropology Newsletter* 9(1):5-10.
- Junker H (1914) *Expedition der Wiener Akademie 1914 auf dem Freidhof von Gizeh*. Vorbericht.
- Leek FF (1967) Reputed early Egyptian dental operation: an appraisal. In DR Brothwell and AT Sandison (eds): *Disease in Antiquity*. Springfield, pp. 702-705.
- Palmer, JF (1835) *The works of John Hunter FRS, with notes*. London: Longman, Rees, Orme, Brown, Greenand and Longgman.
- Puech PF (1987) *Examen microscopique d'une momie egyptienne*. *Nouvelles Archives du Musee d'Histoire Naturelle de Lyon*, fascicule 25:58-60.
- Puech PF, Serratrice C, Leek FF (1983) Tooth wear as observed in ancient Egyptian skulls. *Journal of Human Evolution* 12:617-629.
- Quenouille JJ (1977) *L'art dentaire dans l'ancienne Egypte*. *L'information dentaire*. 43:25-38.
- Sallou F (1975) *Archeologie dentaire, le specimen de Junker*. *Revue d'Odonto-Stomatologie* 4:521-531.

## NEWS SECTION

### DENTAL ANTHROPOLOGY ON GUAM

GARY HEATHCOTE

*University of Guam, Den's Circle, UOG Station, Mingilao, Guam 96923*

I am working on a sample of ancient remains from Rota (Chamorros) which includes many infant and child jaws and dentitions. I am also doing some forensic consulting, and have been working with a local orthodontist, John Van Der Pyl, on betel-stained teeth. "Style" of betel-chewing is uneven across ethnic groups on Guam, and Van Der Pyl has insight into such matters. In addition, I am studying pregnancy outcome data collected this past summer in Palau. The women were nutritionally and anthropometrically assessed the previous summer by Dr. Rebecca Pobocik (nutritional scientist, University of Guam) and myself.

My work on cranial superstructures continues. I am presenting a paper on the interpretive aspects of three occipital superstructures (tubercle development on the occipital torus, retromastoid process, and posterior supramastoid tubercle) in indigenous Mariana Islanders (Chamorros or Chamoru), Tongans, and other Pacific Islanders at the symposium, "Humans in the Australasian Region," at the 9th Annual Meeting of the Australian Society of Human Biology, December 4-6, 1995, in Melbourne, Australia. The paper is titled, "Geographically Restricted Patterning of Cranial Superstructures among Pacific Islanders," and is co-authored with Vincent J. Sava (University of Hawaii-Manoa), Douglas B. Hanson (Forsyth Institute for Advanced Research, Boston), and Bruce E. Anderson (Army Central Identification Laboratory, Hickam AFB, Hawaii).

### GOOD NEWS FROM THE UNIVERSITY OF ADELAIDE

GRANT TOWNSEND, LINDSAY RICHARDS, AND TASMAN BROWN

*Department of Dentistry, University of Adelaide, Adelaide, 5000 South Australia*

**DENTAL RESEARCH PRIZE:** Paula Dempsey, one of our PhD students, was recently awarded the prestigious IADR Travel Award at the 73rd General Session of the International Association for Dental Research in Singapore. Paula won the award for her presentation titled Genetic and Environmental Contributions to Variation in Permanent Tooth Crown Size. A paper presenting some of Paula's findings has just appeared in the *Journal of Dental Research*.

**AWARD OF PhD:** John Kaidonis was awarded his PhD degree at a recent commemoration ceremony in Bonython Hall at the University of Adelaide. John's thesis was titled *An Experimental Study of the Wear Characteristics of Human Enamel during Tooth Grinding*. The objective of John's research was to study enamel attrition using an electromechanical machine that was specifically designed and constructed to grind opposing tooth surfaces while controlling for load, speed, duration of contact, direction of movement, number of cycles, and quantity and quality of lubricant. The wear rate of enamel was quantified under various conditions and replicas of experimental wear facets were examined using electron microscopy to assess surface features qualitatively.