

Nutritional Supplements and Recovery from Tooth Extractions

R. A. HALBERTSTEIN

Department of Anthropology, Department of Epidemiology & Public Health, University of Miami, Coral Gables, Florida

33124

Vitamins, minerals, and other nutritional supplements have been successfully administered for many years in the treatment of a variety of illnesses and injuries. Nutrients have historically not been prescribed, however, for dental diseases or to assist in the recovery from oral surgery (Ismail et al., 1983). By way of example, supplemental vitamin C has not been tested for dental therapeutics despite the longstanding recognition of the role of ascorbic acid in the formation and maintenance of dental structures (Fullmer et al., 1961) and the frequently observed occurrence of gingivitis as a symptom of vitamin C deficiency such as scurvy (e.g. Chope and Breslow, 1956).

The research project reported here investigated the potential benefits of the application of ascorbic acid in promoting healing in a large sample (N = 696) of consecutive tooth extraction patients analyzed at a dental clinic in Miami, Florida. The subjects are broadly distributed in different age groups (range = 11 to 77 years), and both genders are well-represented (males = 48.9% and females = 51.1%). Each individual was provided a printed list of standardized instructions for post-surgical dental care and dietary modification which is routinely given to all clinic extraction patients, and each was asked to return exactly one week later for a follow-up examination. Surprisingly, all patients reported the ability to ingest ample amounts of solid foods beyond the "soft" diet recommendations during the week of recovery.

TABLE 1. Healing progress and incidence of alveolgia (dry socket) according to supplemental Vitamin C status.

Postoperative Medication	Incidence Slow Healing	Incidence Rapid Healing	Dry Socket
Vitamin C (N=358)	13.1%	86.9%	1.1%
Placebo No Vitamin C N = 255	36.5%	63.5%	7.1%
Total N = 613	22.8%	77.2%	3.6%

In both of the above mentioned series of trials, the sub-samples receiving supplementary vitamin C exhibited significantly more rapid healing according to several criteria: (1) presence or absence of edema and purulent material, (2) degree of granulation bed formation, (3) pain expression (according to the Melzack scale) and need for extra analgesic, and 4) post-surgical complications. Table 1 summarizes the cumulative results of the first two samples.

The incidence of alveolgia ("dry socket"), an extremely painful form of faulty extraction recovery, was scored as an objective measure of post-operative complications. As illustrated by the X-ray in Figure 1, dry socket characteristically involves bony osteitis and "ghost imaging" of the socket a full week following the extraction. Alveolgia was nearly seven times more frequent in the non-vitamin C control groups (7.1% to 1.1%); its overall incidence among tooth extraction patients is about 5% (Archer, 1975, p. 1628).

While vitamin C administration was strongly correlated with rapid healing progress according to chi-square and matched (paired) sample *t* test values ($p = 0.0002-0.0009$), gender, age, occupation, medical history, and other demographic and clinical characteristics were not statistically associated with healing rates. No negative side effects of high-dose vitamin C usage (e.g. excess gastric acidity) were reported.

In the third phase of the research the possible role of dietary vitamin C and other nutrients in extraction recovery was monitored. An extensive and detailed analysis was conducted on patients' post-operative intake of dietary nutrients and their possible correlation with healing progress. Neither supplementary vitamin C nor placebos were provided to this additional sample of 83 extraction patients, 28 of whom (33.7%) were subsequently classified as slow healing, while the remainder exhibited rapid healing according to our previous criteria. Protein, calorie, vitamin (A, B6, B12, C), and mineral (magnesium, calcium, iron, zinc, copper, and manganese) ingestion was determined and quantified from patient diaries documenting all food and drink

The study was conducted in three different phases, each with a separate sample and distinctive experimental design. First was a "single-blind" comparison of 277 patients prescribed vitamin C 1,000 mg/day (500 mg 2 times/day) for a week following the procedure against 175 control patients who received no post-operative vitamin C (Halberstein and Abrahamsohn, 1988). In the second phase 81 patients treated with a larger dosage of vitamin C (1,500 mg/day; 500 mg 3 times/day) were likewise evaluated for healing progress one week after their extractions along with 80 placebo patients in a "double-blind" follow-up (Abrahamsohn, Halberstein et al., 1993).

NUTRITIONAL SUPPLEMENTS AND RECOVERY FROM TOOTH EXTRACTIONS

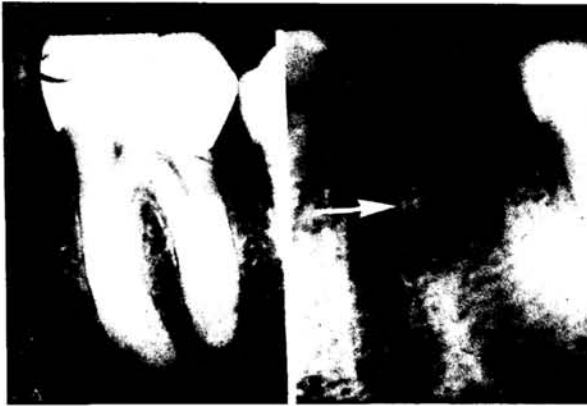


Fig. 1. a case of alveolgia ("dry socket"). X-rays of a molar prior to extraction (A), and its socket one week following the extraction (B) exhibiting "ghost imaging" and bony osteitis (arrow).

TABLE 2. Nutrient constituents of patient's post-operative diets (7 days); N = 28 (Slow Healing) and 55 (Rapid Healing)

Nutrient	Patient Category	Mean	Standard Deviation
Vitamin A (IU)	Slow Healing	8,506.3	7,432.3
	Rapid Healing	12,308.1	10,551.5
Vitamin B6 (mg)	Slow Healing	3.3	2.5
	Rapid Healing	4.1	3.5
Vitamin B12 (μ g)	Slow Healing	9.0	5.4
	Rapid Healing	11.7	12.2
Vitamin C (mg)	Slow Healing	395.9	317.5
	Rapid Healing	554.2	382.6
Magnesium (mg)	Slow Healing	569.0	336.5
	Rapid Healing	632.1	361.6
Calcium (mg)	Slow Healing	2,219.6	1,264.8
	Rapid Healing	2,936.9	1,787.2
Iron (mg)	Slow Healing	31.3	12.8
	Rapid Healing	34.4	15.9
Zinc (mg)	Slow Healing	18.2	11.7
	Rapid Healing	20.5	14.1
Copper (mg)	Slow Healing	2.4	2.2
	Rapid Healing	2.6	3.0
Manganese (mg)	Slow Healing	3.5	2.9
	Rapid Healing	4.7	3.7
Kilocalories	Slow Healing	5,230.3	2,316.2
	Rapid Healing	5,972.4	2,576.9
Protein (gm)	Slow Healing	205.2	94.7
	Rapid Healing	253.0	102.32

consumed during the week following the surgery. Particular items and their specific quantities (e.g. tuna fish sandwich on whole wheat bread, bowl of tomato soup, serving of applesauce, etc.) were converted to nutrient constituents (gm of protein; number of calories expressed in kcal; and vitamins and minerals in mg, μ g, or International Units) by utilizing the 15th edition of Bowes and Church's *Food Values of Portions Commonly Used* (Pennington and Church, 1985).

Results of the independent dietary analysis are presented in Table 2. Subjects classified in the rapid healing category were subsequently discovered to exhibit higher average nutrient intake values across the board. Analysis of variance and *t* tests indicate that statistically significant differences characterized the variations between slow and rapid healing patients with respect to vitamin A, vitamin C, and calcium ($p < 0.05$). Weaker statistical associations were found between healing rates and intake levels of vitamin B12 and protein ($p < 0.20$). Standard deviation figures suggest wide variation among individual patients within the sub-samples with regard to post-operative ingestion of two of the investigated nutrients (vitamin A and calcium) and total calories. An intermediate range of variation may be noted in intake of vitamin C, magnesium, and protein, as well as a greater uniformity in the consumption of the remaining nutrients.

DISCUSSION

The present findings strongly suggest that certain nutrients are beneficial for hastening the recovery from tooth extractions. Results from all three samples indicate that dietary and supplemental ascorbic acid intake is correlated with more rapid clinical healing and reduced likelihood of complication, particularly alveolgia. This discovery is especially significant in light of the fact that the patients' demographic and clinical characteristics (e.g. age, gender, marital status, occupation, disease and medical care history) were not statistically important contributing factors to the observed variations in healing rates.

Recent research indicates that vitamin C might speed dental healing through several biodynamic mechanisms: stimulation of the immune system and antibacterial activity of antibodies and enzymes, strengthening of blood clots, and facilitation of scar (connective) tissue formation during wound repair (Halberstein and Abrahamsohn, 1988). Particularly important is the realization that ascorbic acid serves as a catalyst in the body's synthesis of collagen, a non-dietary protein which is the principal constituent of scar tissue and tooth socket granulation beds (Pinnel, 1984; Pinnel et al, 1987; Rubin, 1984).

NUTRITIONAL SUPPLEMENTS AND RECOVERY FROM TOOTH EXTRACTIONS

According to the present study vitamin A, calcium, and vitamin B12 might also assist an extraction recovery, and further research is warranted to test this hypothesis. The possible role of post-surgical dietary protein intake also deserves reevaluation and double-blind experimentation. Since this investigation revealed extensive variation in post-operative consumption of certain nutrients with relative uniformity of others, it would be worthwhile to reexamine this phenomenon in additional samples of oral surgery patients.

In conclusion, dietary and supplementary nutrients appear to be important factors influencing the course of dental healing. Consequently, dentists and oral surgeons could maximize positive results of their procedures by prescribing vitamins C, A, and B12 and possibly calcium supplements. Dental patients might also profit by the recommendation to ingest as much nutritious food as possible during the recovery period.

ACKNOWLEDGEMENTS

The collaboration and technical assistance of Dr. G.M. Abrahamsohn, S. Fregeolle, and B. Vergara is gratefully appreciated. This research was funded by the University of Miami Research Council, the Mobil Corporation, and the Schering-Plough Company.

LITERATURE CITED

- Abrahamsohn GM, Halberstein RA, and Fregeolle S (1993) Vitamin C and dental healing. II: Testing the placebo effect. *Gen. Dent.* (in press).
- Archer WH (1975) *Oral and Maxillofacial Surgery*; vol. II (5th ed.). Philadelphia: Saunders.
- Chope H, and Breslow L (1956) Nutritional status of the aging. *Am. J. Pub. Health.* 46:61-67.
- Fullmer HM, Martin GR, and Burns JJ (1961) Role of ascorbic acid in the formation and maintenance of dental structures. *Ann. N.Y. Acad. Sci.* 92:286-294.
- Halberstein RA, and Abrahamsohn GM (1988) Vitamin C and dental healing. *Florida Scientist.* 51:41-48.
- Ismail A, Burt B, and Eklund S (1983) Relation between ascorbic acid intake and periodontal disease in the United States. *J. Am. Dent. Assn.* 107:927-931.
- Pennington JA, and Church HN (1985) *Bowes and Church's Food Values of Portions Commonly Used* (15th ed.) New York: Harper & Row.
- Pinnel SR (1984) Regulation of collagen biosynthesis by ascorbic acid: A review. *Yale J. Biol. Med.* 58:553-559.
- Pinnel SR, Murad S, and Darr D (1987) Induction of collagen synthesis by ascorbic acid. *Arch. Dermatol.* 123:1684-1686.
- Rubin MB (1984) Vitamins and wound healing. *Plast. Surg. Nurs.* 4(1):16-19.

A Prehistoric Peruvian Oral Pathology Suggesting Coca Chewing

CHRISTY G. TURNER II

Department of Anthropology, Arizona State University, Tempe, AZ 85287-2402

Figures 1 and 2 illustrate the left and right sides of a prehistoric Peruvian male mandible from the physical anthropology collections of the Smithsonian Institution's National Museum of Natural History, Washington, D.C. The mandible was one of many collected by Aleš Hrdlička in the summer of 1910 from the desert coastal zone of the Chicama Valley, about 20 miles north of Trujillo, Peru. Hrdlička enlisted the aid of the local residents to help him collect 3,400 crania and loose mandibles that were lying on the ground surface in some 30 desert cemeteries in the Chicama Valley and at Pachecamac. According to Clifford Evans (pers. com.) the Chicama Valley was occupied mainly during the Chimu and Mochica periods (A.D. 600 to 1,450). Most of the Chicama skulls probably belong to the latter period.

I found this unusual bone erosion pathology, as illustrated, on the buccal surfaces of lower premolar and molar alveolar borders in a number of the Chicama adults, as well as in the same region in their maxillae. It did not occur in children, subadults, or in the anterior tooth region of any adult. Because mandibles in the collection (all numbered the same, 265352) were in storage trays unassociated with the crania, I counted the pathological condition only in the mandibles. It was present in 56 out of 250 Chicama adults. Sex could not be reliably determined, although both males and females seem to have been about equally represented in the 56 affected mandibles. There were 171 mandibles that lacked the buccal side alveolar bone destruction (i.e., the unaffected