



Eduardo C. Yap, MD<sup>1,2</sup>  
John Michael Porquez, MD<sup>3</sup>

<sup>1</sup>Belo Medical Group  
<sup>2</sup>Department of ENT, Metropolitan Medical Center  
<sup>3</sup>Department of Otolaryngology – Head and Neck Surgery  
University of the Philippines - Philippine General Hospital

# Intradermal Hyaluronidase: The Answer to Treatment in Softening a Fibrous Thick Supratip Skin in Rhinoplasty?

## ABSTRACT

**Keywords:** rhinoplasty; supratip break; supratip fullness; hyaluronidase; fibrous thick supratip skin; bulbous tip

**It is a common goal** for rhinoplastic surgeons to make the best-looking tip with proper projection, maintaining the tip lobule appearance with a supratip break. (Figure 1) However, a fibrous thick skin with fullness may not achieve the ideal tip. It is one of the nuisances in rhinoplasty that makes tip definition surgery difficult. The supratip area remains firm and convex causing a wide bulbous feature of the tip. Several techniques have been introduced with good results however some may still result in supratip fullness because of the firm fibrous nature of thick skin.<sup>1-3</sup>

Hyaluronidase is an enzyme that depolymerizes hyaluronic acid which is present in the epithelium.<sup>4</sup> The use of intradermal hyaluronidase for thick skin was discovered by the junior author (JMP) in one of his rhinoplasties when he injected hyaluronidase in a nose with fillers containing hyaluronic acid. The fillers not only instantly dissolved but the skin also softened, so he tried injecting intradermally in his subsequent rhinoplasties on non-filler noses with fibrous thick skin and indeed found the same effect of softening of the fibrous supratip skin.

We here describe the technique used in this preliminary clinical series.

## METHODS

A vial of 1,500 I.U. of hyaluronidase (Liporase, Skin Lab Medical, Essex, UK) is mixed with 1.0 ml of Normal Saline Solution (NSS) and 0.1 - 0.2ml (150u – 300u) is aspirated and may be diluted with 0.8ml of PNSS in a 1 cc tuberculin syringe or given as concentrated dose. Intradermal injection into fibrous thick skin can be performed intraoperatively before incision or after closure when defatting and tip grafts are put in place but still with supratip fullness. The areas to be injected are the supratip and its sides. (Figure 2)

A disposable hypodermic needle gauge 30 is used to inject intradermally or subdermally in minute amounts until blanching is noted. These injections are given at equally random spacing. Immediately after injection, finger pressure massage is applied at the supratip area for 1-3 minutes to soften the skin and allow redraping of the skin and soft tissue envelope (SSTE).

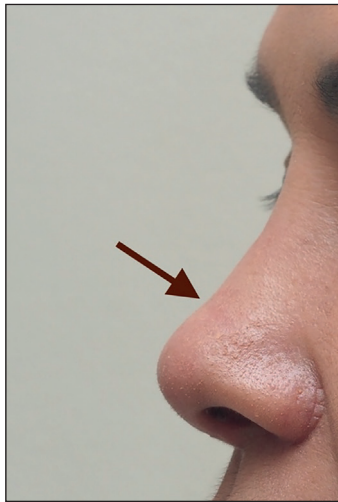
Correspondence: Dr. Eduardo C. Yap  
Unit 3, 28 Times St., West Triangle, Quezon City 1104  
Philippines  
Phone: (632) 8254 1111  
Email: edcyap88@gmail.com

The authors declare that this represents original material that is not being considered for publication elsewhere in full or in part, in print or electronic media; that the manuscript has been read and approved by the authors, that the requirements for authorship have been met by the authors, and that the authors believe that the manuscript represents honest work.

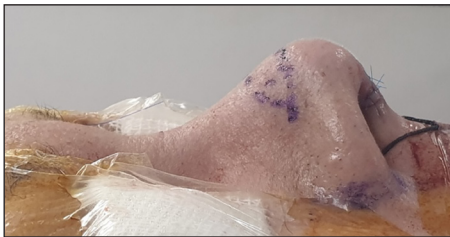
Disclosures: The authors signed a disclosure that there are no financial or other (including personal) relationships, intellectual passion, political or religious beliefs, and institutional affiliations that might lead to a conflict of interest.



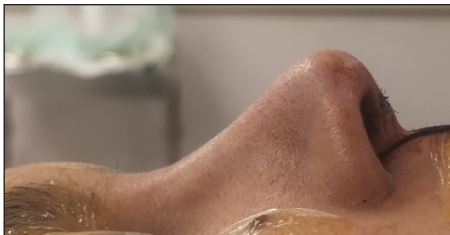Creative Commons (CC BY-NC-ND 4.0)  
Attribution - NonCommercial - NoDerivatives 4.0 International



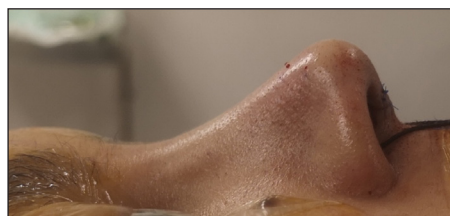**Figure 1.** Ideal tip should have a supratip break



**Figure 2.** Markings at supratip skin and its sides where hyaluronidase is injected intradermally



**Figure 3.** Intraoperative appearance of the nose after open structured rhinoplasty which still showed convexity and supratip fullness



**Figure 4.** Intraoperative appearance of the nose after intradermal injection of hyaluronidase. Note the immediate loss of convexity and softening of the supratip skin. Additional tip grafting can be performed to create a more pronounced supratip break.

An instant effect is noted thereafter. (Figure 3, 4) Because of the transient softening effect, immediate taping and pressure cast dressing is applied post operatively. The procedure may be repeated a week post operatively if there is still residual supratip fullness.

## RESULTS

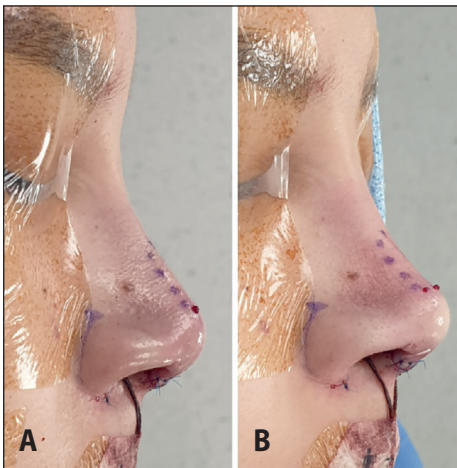
Our initial clinical experience involved 16 patients, aged 22 to 43, with 5 males and 11 females. All patients gave written informed consent for the possible additional procedure of hyaluronidase injection for the supratip skin if tip projection is not well-defined intraoperatively despite defatting and tip grafts. The 16 patients with various thickness in their supratip skin had immediate improvement of nasal profile with good tip definition. Sample cases with pre-operative and post-operative photographs are shown. (Figure 5,6,7)

## DISCUSSION

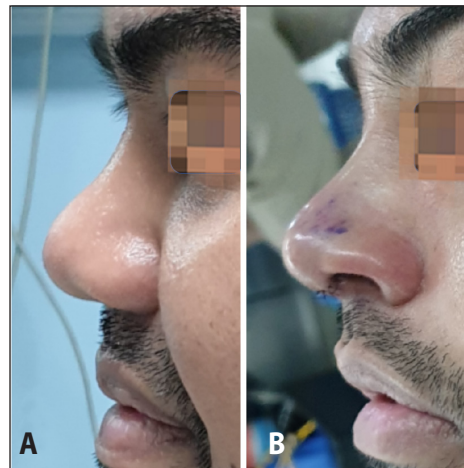
Our initial clinical experience suggests that intradermal hyaluronidase may soften fibrous thick supratip skin and allow a nice aesthetic redraping of the SSTE in rhinoplasty. Hyaluronidase is an enzyme that breaks down hyaluronic acid. Hyaluronic acid or hyaluronan is a polysaccharide found in connective, epithelial and neural tissues. It has been shown that hyaluronidase improve systemic delivery of injectable medications because it depolymerizes hyaluronic acid.<sup>4</sup> It is used in subcutaneous fluid infusion (hypodermoclysis) as well as an adjuvant to accelerate the absorption and dispersion of drugs in subcutaneous tissue. It is also used as an adjunct to promote the absorption of contrast media in urinary tract angiography (subcutaneous urography). It is also approved for used in increasing hematoma absorption in Europe.<sup>5</sup>

One of the off-label uses of hyaluronidase is the reversing of cosmetic facial filler, hyaluronic acid. This practice is widely accepted in cosmetic medicine and surgery.<sup>6</sup> Since the epithelium is rich in naturally occurring hyaluronic acid, injecting hyaluronidase causes degradation of hyaluronic acid causing the skin to soften.

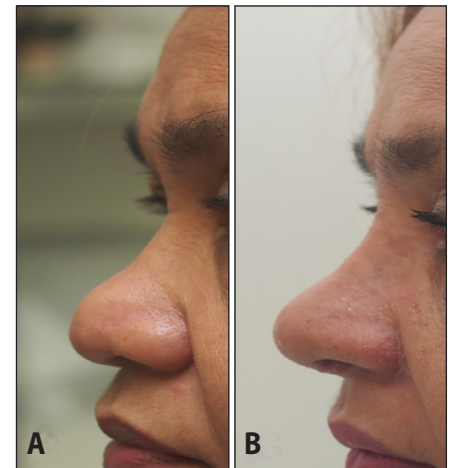
A fibrous thick tip skin in rhinoplasty may not result in a nose with nice tip projection. A convexity may occur causing supratip fullness and polly beak deformity.<sup>1,7</sup> Several surgical techniques recommended to correct such a deformity include skin excision, cartilage suturing, suturing of the dermis to the cartilages, soft tissue resection, multiple layered tip grafts.<sup>1,2</sup> Medical treatments include post operative supratip triamcinolone injection.<sup>3</sup> The above-mentioned treatments improve the supratip up to a certain extent with a supratip fullness. Using hyaluronidase intradermally to soften the supratip skin may be added to the surgical armamentarium to allow molding and redraping. The skin softens significantly with finger massage and pressure allowing



**Figure 5.** A 24-year-old female: **A.** Intraoperatively after rhinoplasty, despite the tip grafts, there is still lack of tip projection because of the thick supratip skin causing fullness. **B.** 150u of hyaluronidase injected intradermally at the supratip area resulted in softening, allowing a nice re-draping of skin and soft tissue over the tip for a supratip break.



**Figure 6.** A 34-year-old male: **A.** Preoperative and **B.** immediate post operative photograph (Photo rotated upright for comparison purposes) showed a remarkable nasal lengthening and tip definition. Intraoperatively after tip grafting and defatting, 300 u of hyaluronidase was injected intradermally to soften the skin and soft tissue thus allowing a slimmer look of the tip.



**Figure 7.** A 43-year-old female: **A.** Preoperative and **B.** one week post operative photographs showed a projected tip. Intraoperatively after rhinoplasty, 300u of hyaluronidase was injected intradermally at supratip area aside from defatting resulting in a softer, slimmer tip.

molding of the supratip area, creating a supratip break. The effect is transient intraoperatively so immediate taping and pressure cast should be applied.

There are possible limitations to our series. First, hyaluronidase is known to be short acting, lasting 3-6 hours and we do not know how long the effects will ultimately last.<sup>8</sup> Because this is a report of our very early experiences, we do not have any long term follow up either. Future studies with long term follow up can address this issue. Second, we did not perform objective measurements of the supratip break, supratip lobule and tip-defining point, tip lobule, infratip lobule using standardized views and angles. A future formal trial can better document these. Indeed, our intraoperative results may be easily produced by finger pressure and molding, and the volume effect of hyaluronidase injection itself can be argued to cause tip projection and relative supratip depression. However, our longstanding combined experience in performing rhinoplasties convinces us that there is a marked softening of fibrous supratip skin after hyaluronidase injection that we have not seen with any other intervention to date. We cannot objectively report this softening, but long term follow-up results and future trials may confirm our initial experience. Perhaps a future formal trial using high resolution ultrasound to measure the supratip skin and SSTE, with long-term follow up may demonstrate the true effect of hyaluronidase.

To the best of our knowledge, based on a search of HERDIN Plus, the ASEAN Citation Index, the Global Index Medicus – Western Pacific Region Index Medicus and Index Medicus of the South East Asia Region, the Directory of Open Access Journals, MEDLINE (PubMed and PubMed

Central, and Google Scholar using the search terms “hyaluronidase,” “rhinoplasty,” “fibrous thick skin,” and “bulbous tip,” there are no English language articles to date on the use of hyaluronidase for fibrous thick skin.

Is intradermal hyaluronidase the answer to treatment in softening a fibrous thick supratip skin in rhinoplasty? Our initial clinical experience suggests that intradermal hyaluronidase may be an adjunct treatment and the answer to softening a fibrous thick supratip skin in rhinoplasty, but the main procedure for producing a nice tip lobule with supratip break is still tip grafting and defatting.

REFERENCES

1. Bhatt M, Brandstetter M, Gubisch W, Haack S. Supratip excision in rhinoplasty. *Otolaryngology case reports.* 2017 Aug;5:8-12. DOI: 10.1016/j.xocr.2017.08.002.
2. Kim SK, Kim JC, Lee KC, Kim HS. Correction of the supratip deformity of the nose. *Aesthet Surg J.* 2012 Nov;32(8):943-55. DOI:10.1177/1090820X12463386; PubMed PMID: 23110926.
3. Goyuron B, DeLuca L, Lash R. Supratip deformity: a closer look. *Plast Reconstr Surg.* 2000 Mar;105(3):1140-51. DOI: 10.1097/00006534-200003000-00049; PubMed PMID: 10724276.
4. Wasserman RL. Recombinant human hyaluronidase-facilitated immunoglobulin infusion in primary immunodeficiency diseases. *Immunotherapy.* 2017 Sep;9(12):1035-1050. DOI: 10.2217/imt-2017-0092; PubMed PMID: 28871852.
5. Jung HW. Hyaluronidase: an overview of its properties, applications, and side effects. *Arch Plastic Surg.* 2020 Jul;47(4): 297-300. DOI:10.5999/aps.2020.00752; PubMed PMID: 32718106; PubMed Central PMCID: PMC7398804.
6. Paap MK, Silkiss RZ. The interaction between hyaluronidase and hyaluronic acid gel fillers – a review of literature and comparative analysis. *Plast Aesthet Res.* 2020 Jul;7:36. DOI: 10.20517/2347-9264.121.
7. Saadoun R, Risse E, Crisan D, Veit JA. Dermatological assessment of thick-skinned patients before rhinoplasty-what may surgeons ask for? *Int J Dermatol.* 2022 Jul 3. DOI: 10.1111/ijd.16341; PubMed PMID: 35781878.
8. Kim HJ, Kwon SB, Whang KU, Lee JS, Park YL, Lee SY. The duration of hyaluronidase and optimal timing of hyaluronic acid (HA) filler reinjection after hyaluronidase injection. *J Cosmet Laser Ther.* 2018 Feb;20(1):52-57. DOI: 10.1080/14764172.2017.1293825; PubMed PMID: 29199877.