

High Flow Bypass for Cavernous Carotid Aneurysms

**Maruf Matmusaev¹, Temur Duschanov², Yasuhiro Yamada³,
Katsumi Takizawa⁴, Tsukasa Kawase³, Riki Tanaka³, Miyatani
Kyosuke³, Yoko Kato³, Ahmed Ansari³**

¹Republican Specialized Scientific and Practical Medical Center of Neurosurgery, Tashkent, UZBEKISTAN

²Department of Neurosurgery, Republican Research Center of Emergency Medicine, Tashkent, UZBEKISTAN

³Department of Neurosurgery, Banbuntane Hotokukai Hospital, Fujita Health University, Nagoya, JAPAN

⁴Department of Neurosurgery, Asahikawa Red Cross Hospital, Hokkaido, JAPAN

Abstract: *Introduction and objective:* High flow extracranial to intracranial (HF EC-IC) cerebral revascularisation may be necessary in the management of complex skull base tumours and intracranial aneurysms. Bypass grafting can be considered high flow when a radial artery or the saphenous vein is interposed between the extracranial carotids arteries and intracranial vessels. The decision as to whether to use a low flow or high flow bypass is determined by the anticipated cerebral blood flow needed and the availability of a supply source. In this study, we have used this method to bypass for two cases of giant aneurysms of the cavernous sinus part of the ICA. *Methods:* Two cases of giant ICE aneurysm not amenable to clipping or coiling were taken since 2016. Patients were treated in Neurosurgery department of Fujita Health University Banbuntane Hotokukai Hospital, Nagoya, Japan. During bypass surgery, intraoperative methods were used to determine the patency of the graft artery: Doppler sonography and indocyanine green (ICG) Dual-Image Videoangiography (DIVA). *Results:* Two patients with symptomatic large and giant cavernous carotid aneurysms were evaluated as not amenable for clipping or endovascular treatment due to location and size of the aneurysm and associated high morbidity risk with these treatment options. In both cases radial artery graft was used for high-flow EC-MCA bypass and proximal internal carotid artery was ligated. Additionally, for high-flow bypass was performed superficial temporal artery (STA) to middle cerebral artery (MCA) bypass. DIVA, ICG and Doppler sonography were used multiple times to assess the patency of graft artery. In one case there was not complete ligation of the IC after postop DSA, the next day was

performed reintervention to completely ligate IC. Postoperative course was uneventful, there were no mortality or morbidity. Follow-up showed good recovery and postoperative CT and DSA showed complete occlusion of ligated IC and patent functioning arterial graft. *Conclusions:* Cavernous carotid aneurysms (CCA) are rare and pose considerable challenges in management. A bypass procedure before parent artery occlusion, preferable to reduce the risks of postocclusion stroke. Intraoperative Doppler sonography and DIVA makes it easy to check the patency of the graft. DIVA is superior over Doppler or ICG in terms of better visualization of related anatomical structures.

Key words: high flow bypass, cavernous carotid aneurysm, radial artery graft

Introduction

Cavernous carotid aneurysms (CCA) are rare and pose considerable challenges in management. High flow extracranial to intracranial (HF EC-IC) cerebral revascularisation may be necessary in the management of complex skull base tumors and intracranial aneurysms [1]. Bypass grafting can be considered high flow when a radial artery or the saphenous vein is interposed between the extracranial carotids arteries and intracranial vessels. The decision as to whether to use a low flow or high flow bypass is determined by the anticipated cerebral blood flow needed and the availability of a supply source. The risks and benefits of treatment of CCA should be carefully considered because CCAs are not a common pathology, and there are no definite guidelines for treatment currently. Furthermore, data about the natural history and pathogenesis of CCA is limited. Indications for treatment of CCA are summarized in Table 1.[2,3]

Table 1 - Indication of surgical intervention for cavernous part of ICA giant aneurysms

Asymptomatic aneurysms	Symptomatic aneurysms
<ul style="list-style-type: none"> • Extension of aneurysm into subarachnoid space • Origin from anterior genu of cavernous carotid • Radiographic enlargement of aneurysm 	<ul style="list-style-type: none"> • Subarachnoid hemorrhage • Unbearable ipsilateral face or retro-orbital pain • Progressive ophthalmoplegia • Sudden, severe ophthalmoplegia

Objective of this study is to evaluate effectiveness and surgical techniques of HF EF - IC bypass as appropriate choice of surgical treatment for giant aneurysms of cavernous sinus part of internal carotid artery.

Materials and methods

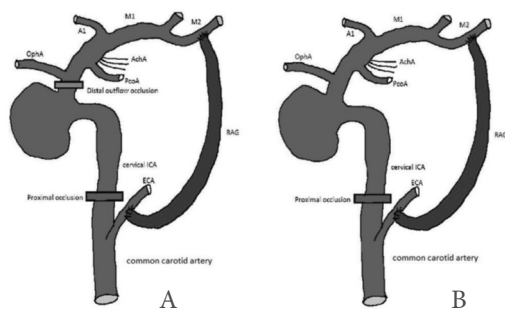
This study was conducted on two cases with giant aneurysms of the cavernous sinus part of the ICA that treated with high flow bypass techniques using radial artery (RA) in our practice at Neurosurgery department of Fujita Health University Banbuntane

Hotokukai Hospital, Nagoya, Japan since 2016. Preoperative evaluation was done with digital subtraction angiography (DSA) and 3D-CT angio. Balloon occlusion test was not performed on these patients, because of atherosclerotic vessels. It is essential to evaluate collateral supply of both intracranial vessels and arteries of non-dominant upper limb using non-invasive fusion or DSA. During surgical procedure that has been done by us, Doppler Sonography (DS), Indocyanine green (ICG) and Dual-Image videoangiography (DIVA) were used to determine the patency of the graft artery.

Case report

77-year-old female was admitted to our hospital with complaints of 3 months history of headache and dizziness. Preoperative 3D-CT, MRI and DSA showed a giant aneurysm on the right cavernous part of internal carotid artery (ICA) that is why diagnosis was a giant right aneurysm of the cavernous portion.

Illustration of procedure



(A) Trapping (cervical internal carotid artery ligation with clipping of C3 segment of internal carotid artery, just proximal

toophthalmic artery origin) of cavernous carotid aneurysm with high-flowbypass. (B) Cervical internal carotid artery ligation with high-flowbypass. Both techniques result in the complete aneurysm thrombosis. First segment of anterior cerebral artery (A1), anterior choroidal artery, first segment of middle cerebral artery (M1), second segment of middle cerebral artery (M2), ophthalmic artery (OphA), posterior communicating artery (PcoA), and radial artery graft (RAG)[4,5].

Surgical procedure

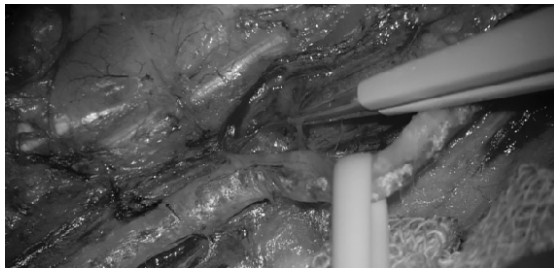
First, anastomose the STA to M4 (peripheral part of the M2 to which RA is anastomosed). In the supine position with raised and turned head to the opposite side. Due to presence of many procedures, two operation teams carry out operation by using two microscopes to shorten operation time at the same time. Team for radial graft preparation identifies and confirms collateral circulation using DSA. If there is good collateral circulation RA graft can be obtained at least 18 cm in length but it is effective to get longer as much as possible because the diverging from the brachiocephalic trunk is the limit of removal on the proximal side, so the distal side is removed as long as possible. During or some time before obtaining RA graft, to let STA-MCA bypass precede for the assist bypass both parietal branch and frontal branch of STA is dissected. It is important to note that the main disadvantage of RA graft is the potential for vasospasm following harvest, which may lead to total occlusion of the vessel and therefore vasospasm is prevented by using pressure distention technique.

Normal parieto-temporal craniotomy is enough, but removing the bones of middle cranial fossa should be appropriate for the RA graft. As for the common artery, it is not necessary to expose a long segment, yet the external carotid artery that becomes the anastomosis of RA is to be exposed to as high position as possible to choose the anastomotic part. To occlude the central of the ICA, two 1.0 silk threads are put through the internal carotid beforehand and identify the posterior belly of the digastric muscle and hypoglossal nerve. Choose the submandibular root as the graft root. As for this root, the length of this graft becomes the shortest, and thus the influence such as the pressure of graft can be avoided. However, pay much attention whether there is not possibilities for torsion or kinking of the graft in the blind part to be occurred.

Making tunnel for graft by using Merkmal consists of following stages; insertion of forefinger from the interval of posterior belly and the hypoglossal nerve from the cervical side till styloid process and then towards the upper front. When it reaches cranial side by Kelly forceps that is inserted in front part of the zygomatic bone from the interval of the temporal muscle and the temporal bone it reaches to cranial side from the neck.

On the cranial side, RA graft is anastomosed to the silk thread in the Chest tube. By pulling out the silk thread to the neck side, the RA graft can be indwelled from the head to the neck, after the final confirmation following the anastomosis of the RA graft to

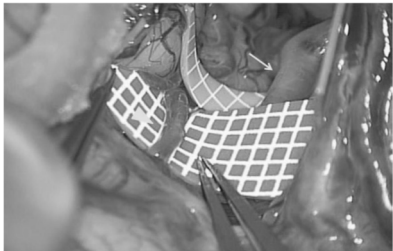
M2 by the 9.0 Nylon suture because of the big vascular size and solid wall of RA, remove the chest tube. First, anastomose the STA to M4 (peripheral part of the M2 to which RA is anastomosed). As for STA perform end-to-side anastomosis by 10.0 Nylon suture. The purpose of this bypass is to prevent the ischemia complications at the time of RA-M2 anastomosis that calls for the longer-time temporary blockade (assist bypass) and to monitor the brain surface MCA pressure to evaluate the patency of RA graft that was completed finally in real time during the operation and in this stage anastomosis process is finished. After that temporary clip in RA in the region close to the anastomosis is done so as to prevent retrograde flows of blood into the graft. Finally, due to the wide vascular diameter proximal part of RA-ECA end-to-side anastomosis can be performed by continuous suture of 7.0 prolene. Before blood flow is restored to the brain, the distal end of the CCA and the proximal side of the ICA are clamped, then the proximal side of the ECA and the distal clamp of the conduit are opened, which allows air to vent through the superior thyroid artery. DS, ICG and DIVA are used during operation after proximal native ICA clamping to demonstrate graft patency and to evaluate the anastomotic sites. After all proximal ICA is ligated and anticoagulation reversed with protamine. In the case of giant aneurysm at the cavernous portion, the parent vessel is not ligated distally, as all of the aneurysm is still thrombosed.



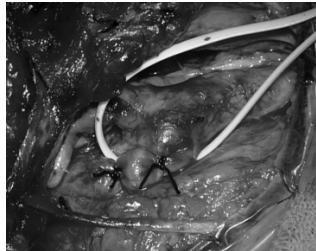
Dissecting the RA while applying appropriate tension with vascular tape



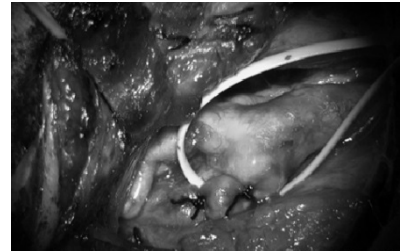
pressure distension technique is performed to prevent vasospasm



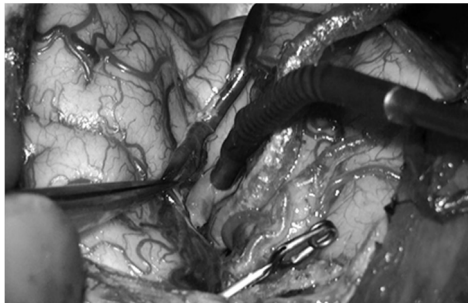
Prepped recipient artery. Arrow: M2 for the RA graft, Arrow head: M4 for the STA



ICA permanently occluded by double ligation with a 1.0 silk suture



ICG and DIVA demonstrates that there is not blood flow into ICA after occlusion of ICA (previous stage)

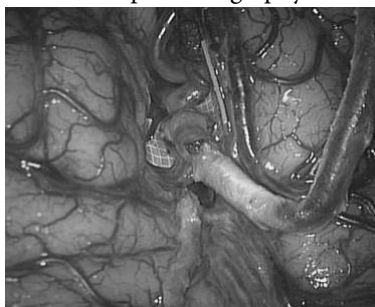


a

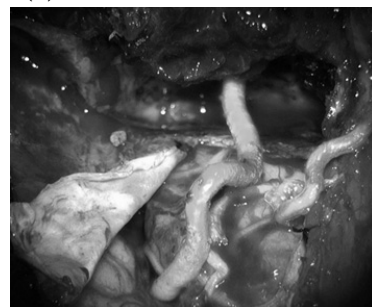

b

Dopler sonography of MCA (a) and RA graft (b) after anastomosis.

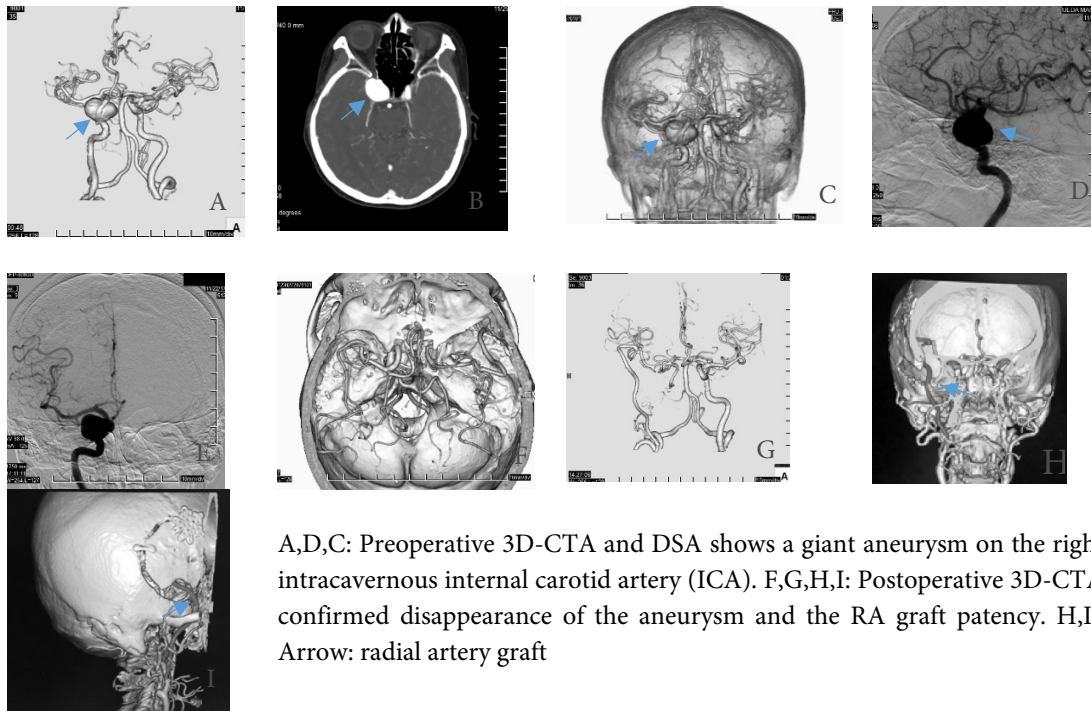


Final image of RA graft bypass. (Proximal view)



ICG and DIVA illustration of blood flow restoration after anastomosis

Patient was treated with radial artery (RA) graft technique and ICA occlusion. Postoperative 3D-CTA and confirmed disappearance of the aneurysm and the RA graft patency.



A,D,C: Preoperative 3D-CTA and DSA shows a giant aneurysm on the right intracavernous internal carotid artery (ICA). F,G,H,I: Postoperative 3D-CTA confirmed disappearance of the aneurysm and the RA graft patency. H,I, Arrow: radial artery graft

Results

Two patients with symptomatic large and giant aneurysms of cavernous part of ICA were evaluated as not amenable for clipping or endovascular treatment due to location and size of the aneurysm and associated high morbidity risk with these treatment options. In both cases radial artery graft was used for high-flow EC-MCA bypass and proximal internal carotid artery was ligated. Additionally, for high-flow bypass was performed superficial temporal artery (STA) to middle cerebral artery (MCA) bypass. DIVA, ICG and Doppler sonography were

used multiple times to assess the patency of graft artery. In one case there was not complete ligation of the IC after postop DSA, after one month was performed reintervention to completely ligate IC. Postoperative course was uneventful, there were no mortality or morbidity. Follow-up showed good recovery and postoperative CT and DSA showed complete occlusion of ligated IC and patent functioning arterial graft.

Discussion

Tarr et al. and Origiano et al. think that the cumulative risks of not performing revascularization in patients who tolerate ICA balloon occlusion (risk of BTO itself 3.7–7% false negative rate of BTO 7–22%) exceed the surgical risk of revascularization (3–7%).

Murai et al. reported in 17 bypass surgeries cranial nerve dysfunction (III and VI) caused by altered blood flow from the ICA after occlusion was the most common complication (three cases in CCA) and typically was temporary.

Houkin et al.[4] reported in 36 patients with giant or large aneurysms located at the cavernous portion of the ICA postoperative angiography showed patency of bypass graft in 97% of cases. Aneurysms disappeared and thrombosed on postoperative angiography and magnetic resonance imaging, respectively.

Houkin et al and Kamiyama reported that most of the aneurysms would spontaneously thrombose after proximal ligation without the distal outflow occlusion. [4,5]

In addition, endovascular techniques have been developed to treat CCA, which included intra-aneurysmal coil embolization with or without stent or balloon-assist, and flow-diverting stent. performed intra-aneurysmal coil embolization in seven patients with large or giant symptomatic CCA. After the operation, one patient improved the symptoms of aneurysmal mass effect, two patients unchanged and four patients deteriorated. They concluded that intra-aneurysmal coil embolization is not an effective treatment option for large or giant CCA. [6]

According to a recent report, a flow diverting stent has been developed for the effective treatment of an unruptured giant symptomatic CCA;[7] however, early,[8] and delayed [9,10] rupture of the aneurysm after treatment has been described. The incidence of delayed rupture of an aneurysm after the stent is 0.6–1%, but was not reported for early rupture. The risk factor is aneurysm size 10 mm or larger.[9]

In cases of a ruptured aneurysm with flow diverting stent treatment, the blood flow entered the aneurysm sac continuously without intra-aneurysmal pressure reduction immediately after device deployment. Furthermore, it was necessary to use the antiplatelet agent during the perioperative period after stenting. Therefore, prompt prevention of the aneurysmal re-rupture could not be obtained.[11]

Hasegawa et al reported In cases with direct CCF (carotid cavernous fistula) due to ruptured however, endovascular management was not always available on an urgent basis in some institutes and was not always successful, in which case direct surgical trapping of the lesion and distal bypass might be indicated. [12]

Little et al.[13] reported 15 cases of symptomatic CCA were treated with different methods of ICA occlusion without high-flow bypass. Good results were achieved in most cases, but delayed ipsilateral cerebral ischemia was found in two cases (13%), and partial retrograde filling of the aneurysm was demonstrated in three cases.

Postoperative complications of six case series are summarized in Table 2. [13,4,14,15,17,16]

Table 2 - List of complications

Ischemic stroke	Cranial nerve palsy	Ruptured Acom aneurysm	De novo aneurysm formation	Delayed re-enlargement of CCA	Epilepsy due to hyperperfusion syndrome
2/15 cases (13%) One case for STA-MCA bypass with Selverstone clamp occlusion One for ICA ligation) *Mean follow-up period 5.6 years	CN3, CN5 palsy 2/15 cases	No	No	No	No
1/36 cases (2.8%) RA graft occlusion *Mean follow-up period 7.2 years	No	No	No	No	No
3/11 cases (27.3%) Early 1 case Delayed 2 cases *Mean follow-up period 13.9 years	No	Ruptured Acom aneurysm (1 case)	(2 cases, contralateral CCA and Acom)	Delayed re-enlargement of CCA (2 cases)	No
0% *Mean follow up period 5.2 years	CN3,6 palsy (3/13 cases)	No	No	No	No
2/12 cases (16.7%) Both are embolic stroke One case is asymptomatic	CN2 (1 case) CN3,4 (2 cases) CN3,4,6 (1 case) CN6 (1 case)	No	No	No	No
1/8 cases (12.5%) A small ipsilateral frontal ischemia (transient dysarthria and gait disturbance) *Mean follow-up period 3.15 years	CN4 (1 case)	No	No	No	Epilepsy due to hyperperfusion syndrome (1 case)

Conclusions

Cavernous carotid aneurysms (CCA) are rare and pose considerable challenges in management. A bypass procedure before parent artery occlusion, preferable to reduce the risks of postocclusion stroke.

For CCA with mass effect, high-flow bypass with proximal occlusion of ICA

(without trapping) seems to be the first choice treatment for large and giant CCA because of the high rate of aneurysm thrombosis.

In our case series, the RA proved to be a useful graft for cerebral revascularization. Its long-term patency has been demonstrated in the surgical management of giant aneurysms of the cavernous and paraclinoid ICAs. The

RA has a lumen that closely approximates that of the M2 segment, and it has the advantage of being a physiological conduit for arterial blood. Unlike venous grafts, the RA lacks valves and varices, and is technically easier to harvest because of its consistent anatomical location and size. More resistant to kinking than the SV, the RA is preferable to this vein, whose flow mismatch can lead to subsequent flow turbulence and graft thrombosis. The RA grafts can better tolerate intermittent temporary occlusion when compared with vein grafts, whose valves and endothelium can promote thrombosis in low-flow states [18,19].

Intraoperative Doppler sonography and DIVA makes it easy to check the patency of the graft. DIVA is superior over Doppler or ICG in terms of better visualization of related anatomical structures.

References

1. Sheau Fung Sia, Michael Kerin Morgan. High flow extracranial-to-intracranial brain bypass surgery. *Journal of Clinical Neuroscience*. Volume 20, Issue 1, January 2013, Pages 1-5
2. Russell SM, Jafar JJ. Microsurgical treatment of intracavernous carotid artery aneurysms. In: Le Roux PD, Winn RH, Newell DW, editors. *Management of Cerebral Aneurysms*. Philadelphia: Saunders; 2004. p. 711-29.
3. Linskey ME, Sekhar LN, Hirsch WL Jr., Yonas H, Horton JA. Aneurysms of the intracavernous carotid artery: Natural history and indications for treatment. *Neurosurgery* 1990;26:933-7.
4. Houkin K, Kamiyama H, Kuroda S, Ishikawa T, Takahashi A, Abe H. Long-term patency of radial artery graft bypass for reconstruction of the internal carotid artery. Technical note. *J Neurosurg* 1999;90:786-90.
5. Kamiyama H. Bypass with radial artery graft. *No Shinkei Geka* 1994;22:911-24.
6. Morita K, Sorimachi T, Ito Y, Nishino K, Jimbo Y, Kumagai T, et al. Intra-aneurysmal coil embolization for large or giant carotid artery aneurysms in the cavernous sinus. *Neurol Med Chir (Tokyo)* 2011;51:762-6.
7. Szikora I, Berentei Z, Kulcsar Z, Marosfoi M, Vajda ZS, Lee W, et al. Treatment of intracranial aneurysms by functional reconstruction of the parent artery: The Budapest experience with the pipeline embolization device. *AJNR Am J Neuroradiol* 2010;31:1139-47.
8. Turowski B, Macht S, Kulcsár Z, Hänggi D, Stummer W. Early fatal hemorrhage after endovascular cerebral aneurysm treatment with a flow diverter (SILK-Stent): Do we need to rethink our concepts? *Neuroradiology* 2011;53:37-41.
9. Lin LM, Colby GP, Jiang B, Pero G, Boccardi E, Coon AL. Transvenous approach for the treatment of direct carotid cavernous fistula following pipeline embolization of cavernous carotid aneurysm: A report of two cases and review of the literature. *BMJ Case Rep* 2014;2014. pii: Bcr2014011235.
10. Kallmes D, Boccardi E, Bonafe A, Cekirge S, Fiorella D, Hanel R, et al. O-009 Safety of flow diversion: Results from a multicenter registry. *J Neurointerv Surg* 2013;5 Suppl 2:A6. [Abstr].
11. Schneiders JJ, VanBavel E, Majoie CB, Ferns SP, van den Berg R. A flow-diverting stent is not a pressure-diverting stent. *AJNR Am J Neuroradiol* 2013;34:E1-4.
12. Hasegawa H, Inoue T, Tamura A, Saito I. Urgent treatment of severe symptomatic direct carotid cavernous fistula caused by ruptured cavernous internal carotid artery aneurysm using high-flow bypass, proximal ligation, and direct distal clipping: Technical case report. *Surg Neurol Int* 2014;5:49.
13. Little JR, Rosenfeld JV, Awad IA. Internal carotid artery occlusion for cavernous segment aneurysm. *Neurosurgery* 1989;25:398-404.
14. Niiri M, Shimozuru T, Nakamura K, Kadota K, Kuratsu J. Long-term follow-up study of patients with cavernous sinus aneurysm treated by proximal occlusion. *Neurol Med Chir (Tokyo)* 2000;40:88-96.
15. Murai Y, Teramoto A, Mizunari T, Kobayashi S, Kamiyama H. Treatment of complex internal carotid artery aneurysm using radial artery grafts. *Surg Cereb Stroke* 2007;35:387-93.
16. Murai Y, Mizunari T, Umeoka K, Tateyama K, Kobayashi S, Teramoto A. Radial artery grafts for

symptomatic cavernous carotid aneurysms in elderly patients. *Neurol India* 2011;59:537-41.

17. Shimizu H, Matsumoto Y, Tominaga T. Parent artery occlusion with bypass surgery for the treatment of internal carotid artery aneurysms: Clinical and hemodynamic results. *Clin Neurol Neurosurg* 2010;112:32-9.

18. Surdell DL, Hage ZA, Eddleman CS, Gupta DK, Bendok BR, Batjer HH. Revascularization for complex intracranial aneurysms. *Neurosurg Focus* 2008;24:E21.

19. Kocaeli H, Andaluz N, Choutka O, Zuccarello M. Use of radial artery grafts in extracranial-intracranial revascularization procedures. *Neurosurg Focus* 2008;24:E5.