

DOI: 10.2478/romneu-2018-0053  
Article

# Computational fluid dynamics as an indicator of offending vessel in trigeminal neuralgia and hemifacial spasms

Mayur Kamath V., Yasuhiro Yamada, Yoko Kato  
JAPAN

## Computational fluid dynamics as an indicator of offending vessel in trigeminal neuralgia and hemifacial spasms

Mayur Kamath V.<sup>1</sup>, Yasuhiro Yamada<sup>2</sup>, Yoko Kato<sup>2</sup>

<sup>1</sup>Department of Neurosurgery, Kasturba Medical College, Mangalore & Fellow, Department of Neurosurgery, Banbuntane Hotokukai Hospital, Fujita Health University, Nagoya, JAPAN

<sup>2</sup>Department of Neurosurgery, Banbuntane Hotokukai Hospital, Fujita Health University, Nagoya, JAPAN

**Abstract:** *Context:* Newer Imaging tool for diagnosing offending vessel in trigeminal neuralgia (TN) and Hemifacial spasms (HFS). *Aim:* To find out if Computational FluidDynamics (CFD) can correctly predict the offending vessel in HFS and TN & thus improving the outcome of Microvascular Decompression) MVD. *Settings and Design:* CFD is a relatively new mode of imaging. Its application to indicate offending vessel in TN & HFS was tested. *Materials & Methods:* Retrospectively we studied 13 consecutive patients operated in 2017 for either HFS or TN. Preoperatively MRI & Computed Tomography Angiogram (CTA) were done and the offending vessel identified along with its point of contact with the concerned nerve. CFD was done using Hemoscope 2015 software and wall pressure, wall shear stress, vector & streamline flow were obtained in the offending vessel (test) & contralateral vessel (control). Results of these were charted on an excel sheet & results analyzed. The postoperativeoutcome were assessed and compared with CFD results. *Statistical analysis used:* Small study group hence statistical analysis couldn't be applied. *Results:* Of the 13 patients, offending artery had high wall pressure in 12 and increased wall shear stress innine. Among the controls six had high wall pressure and only two had high wall shear stress. *Conclusion:* CFD can be used to determine offending vessel and can predict good outcome following microvascular decompression.

**Key words:** Trigeminal Neuralgia, Hemifacial spasms, Computational Fluid Dynamics, Microvascular decompression & Offending Vessel.

### Introduction

The diagnosis of HFS & TN are mainly clinical based on patient's symptoms. TN is usually diagnosed based on following symptoms & signs<sup>1</sup>:

Unilateral facial pain, no extension beyond trigeminal territory, pain is paroxysmal with intervals of remission. Pain occurs spontaneously or more commonly triggered by a stimulus. On examination there is usually

no hypoesthesia or defective corneal reflex. These patients usually would have responded at least initially to medical management. HFS on the other hand involves sudden involuntary contraction of one side of the face. Usually imaging in TN & HFS reveals an offending artery abutting the trigeminal & facial nerve respectively. The most common offending artery in TN is superior cerebellar artery (SCA) followed by anterior inferior cerebellar artery (AICA)<sup>2,3,4,5</sup>.

The most common offending artery in HFS is AICA followed by posterior inferior cerebellar artery (PICA) & vertebral artery (VA)<sup>6</sup>.

Mostly the radiological evaluation for Trigeminal neuralgia & hemifacial spasms include High resolution T2 MRI which includes Constructive interference in steady state (CISS) & Fast imaging employed steady state acquisition (FIESTA), T1 POST Gadolinium MRI and CT Angiography<sup>7</sup>.

Computational fluid dynamics (CFD) is the use of applied mathematics, physics and computational software to visualize how a liquid flows – as well as how the liquid affects objects as it flows past<sup>8</sup>. In case of humans it is blood (liquid) that flows through blood vessels (tube). CFD gives us valuable information of blood flow through the vessels and hence has valuable applications. Wall pressure is the force of blood column on the arterial wall circumferentially leading to stretching/stress on all wall layers. Wall shear Stress is the tangential drag force produced by blood moving across the endothelial surface. It is a function of the velocity gradient of blood near the endothelial surface. Its magnitude is directly proportional to blood flow and blood

viscosity and inversely proportional to the cube of the radius. Wall shear stress regulates arterial wall remodelling. Vector and stream line velocity indicate the weather blood flow within the vessels is laminar or turbulent.

CFD has had multiple applications in imaging of the cerebral aneurysms in the past. Some of CFD in cerebral aneurysm include diagnosing thin walled regions in unruptured aneurysms<sup>9</sup>, rupture prediction of intracranial aneurysm<sup>10,11</sup>.

There has been however been some confusion regarding whether high or low wall shear stress leads to rupture with some authors believing both high and low wall shear stress causes aneurysmal rupture<sup>12</sup>. However CFD was not used in predicting the offending vessel and incriminating it as the cause of trigeminal neuralgia or hemifacial spasms until Dr. Toru Satoh from Ryofukai Satoh neurosurgical hospital, Hiroshima, Japan pioneered a study<sup>13</sup>. However no other articles were published on this regard at the time of writing this paper.

Trigeminal Neuralgia is treated initially with oral anticonvulsants like carbamazepine or oxcarbamazepine<sup>14</sup>. Lamotrigine, Clonazepam, Gabapentin, Pregablin and valproate are other drugs that have beneficial effects in trigeminal neuralgia.<sup>15,16,17,18</sup> Hemifacial spasms are treated initially with botulinum toxin<sup>19</sup>. GABAergic drugs and anticonvulsants are less effective when compared to botulinum toxin but are of some benefit in early stages when the contractions are weak & infrequent.

Microvascular Decompression (MVD) is reserved for patients not responding to medical line of management. Microvascular

decompression for TN & HFS is offered to patients with Neurovascular conflict (NVC). MVD is based on the fact the principle that the cause of neuralgia/ spasm is due to compression of the nerve by a vessel & MVD aims at removing that compression by either altering the path of offending vessel i.e. transposition or inserting teflon/ muscle patch between the offending vessel and the nerve at the point of NVC i.e. interposition. MVD has shown excellent results in both trigeminal neuralgia and hemifacial spasms. An analysis of twenty-two papers representing 5,685 patients treated with MVD for HFS found that an average of 91.1% of patients had complete resolution of symptoms over a median 2.9-year follow-up period<sup>20</sup>. Another meta-analysis included 8,484 cases of TN who underwent either MVD or gamma knife and concluded that MVD is better than GKRS in treating patients with idiopathic TN, better outcomes in the MVD group is because of immediate post op pain relief&MVD should be offered as first line of surgical intervention if no contraindication for surgery<sup>21</sup>. However there are reports that even despite of good microvascular decompression there are instances of no pain relief. Our study wanted to address such cases so as to improve the overall operative outcome by better preoperative evaluation of offending vessel.

### **Aim of the study**

To find out if Computational Flow Dynamics (CFD) can correctly predict the offending vessel in hemifacial spasms (HFS) and trigeminal neuralgia (TN) & thus improving the outcome of MVD.

### **Materials & methods**

In this retrospective study we studied 13 consecutive patients who underwent MVD procedures in the year 2017. Our preoperative workup included a 3D CTA and 1.5 T MRI including CISS & FIESTA sequences. With the help of these images the point of neurovascular conflict is confirmed. Once the offending vessel and point of NVC is identified, 3D CTA images are used to construct CFD using Hemoscope 2015 software. In the Hemoscope 2015 software, once the offending vessel is isolated the two points are marked proximal and distal to the NVC and orthogonal are constructed. Once this procedure is done the Hemoscope 2015 software automatically measures the vessel length, inlet and outlet diameter of the vessel. Once the measurements are done we choose the inlet and CFD is run on onsite mode which takes approximately ten to fifteen minutes for completing analysis. Once the analysis is complete the wall pressure, wall shear stress, streamline velocity and vector at NVC which serves as test and is charted on an excel sheet. Once the data is entered the entire procedure is repeated with normal contralateral vessel which serves as control and data of analysis charted on same excel sheet. Similarly, the data of all 13 patients were analyzed bilaterally and charted in the excel sheet. The data was expressed in terms of percentage of the values.

Microvascular Decompression involves patient to be in General anesthesia in lateral position with affected side up and head fixed to a Sugita clamp. Once the patient is meticulously prepared and draped we use a retroauricular incision and elevation of a subcutaneous flap followed by a small three by

three centimeter retro sigmoid craniotomy to expose the transverse – sigmoid sinus junction. Dura is opened in a Y shaped manner. The sharp arachnoid dissection is carried out on the lateral aspect of the cerebellum and CSF is released from lateral cerebellomedullary cistern. Once the cerebellum is lax, the cerebellum is dissected to expose the lower cranial nerve, seventh eighth complex and the trigeminal nerve. Once the nerve is identified sharp dissection is carried out to expose the Root Entry Zone (REZ) of the nerve. Any vessel in the path of REZ is identified by Dual Image Video Angiography (DIVA) & Endoscopy. Once the offending vessel is identified MVD is carried out either by transposition or by interposition. We always advocate intraoperative nerve monitoring of V, VII & VIII cranial nerves. Once adequate MVD is achieved the decompression is confirmed with DIVA& Endoscopy that no vessel is abutting the nerve at its REZ. After this hemostasis is achieved and dura closed in a watertight fashion and augmented with subcutaneous tissue flap and fibrin glue. The craniotomy defect is corrected by using a mesh of appropriate size& fixed with screws. The wound is closed in three layers i.e. Muscle, subcutaneous tissue and skin.

Postoperatively patient is followed up in terms of immediately post-surgery, one month post-surgery and three months postoperatively. The pain is graded as per Barrow Neurological Institute (BNI) pain intensity score<sup>22</sup>.

#### **Score Pain description**

I No pain, no medications

II Occasional pain, no medications required

III Some pain, adequately controlled with medications

IV Some pain, not adequately controlled with medications

V Severe pain or no pain relief

#### **Results**

Of the 13 patients, male: female ratio was five is to eight. The patients ranged from 47 to 77 years with a mean of 63.8 years. Of the 13 patients five had hemifacial spasms while eight had trigeminal neuralgia. Of the five patients with hemifacial spasms four had it on the left side while one had it on the right. Of the eight patient with trigeminal neuralgia six had it on the right side while two had it on the left.

On imaging, in five cases of HFS offending vessel was PICA in three cases, VA PICA in one case and AICA in one case. These vessels corresponded well to the intraoperative findings. Among the eight TN patients seven had SCA as the offending artery whereas one case had AICA. However intraoperatively we could not find an offending vessel in one of the cases where imaging suggested an SCA as an offending vessel.

CFD analysis suggested that among the 13 patients, 12 patients (92.3%) had high wall pressure and ten patients (76.9%) had high wall shear stress at NVC on the affected side. However only six patients (46.1%) had high wall pressure & only two patients (15.4%) had high wall shear stress on the normal side.

In the one patient we could not find the offending vessel intraoperatively the wall pressure on the CFD analysis was low however

the wall shear stress was high. Of the five patients with Hemifacial spasms, four (80%) had complete relief immediately, at one month & three months follow up whereas one (20%) patient had complete relief immediately & at one month follow up but had recurrence of symptoms at three months follow up that required no treatment.

Of the eight patients with trigeminal neuralgia, seven (87.5%) patients had good control of pain (BNI grade two or less) immediately, one month & three month follow up & required no medication at three month follow up. However one (12.5%) patient had BNI grade four at three months follow up despite immediate and one month follow up

BNI grade of one. Patient was treated by trigeminal nerve block. Our results of MVD for HFS & TN were comparable with other studies<sup>20, 21</sup>.

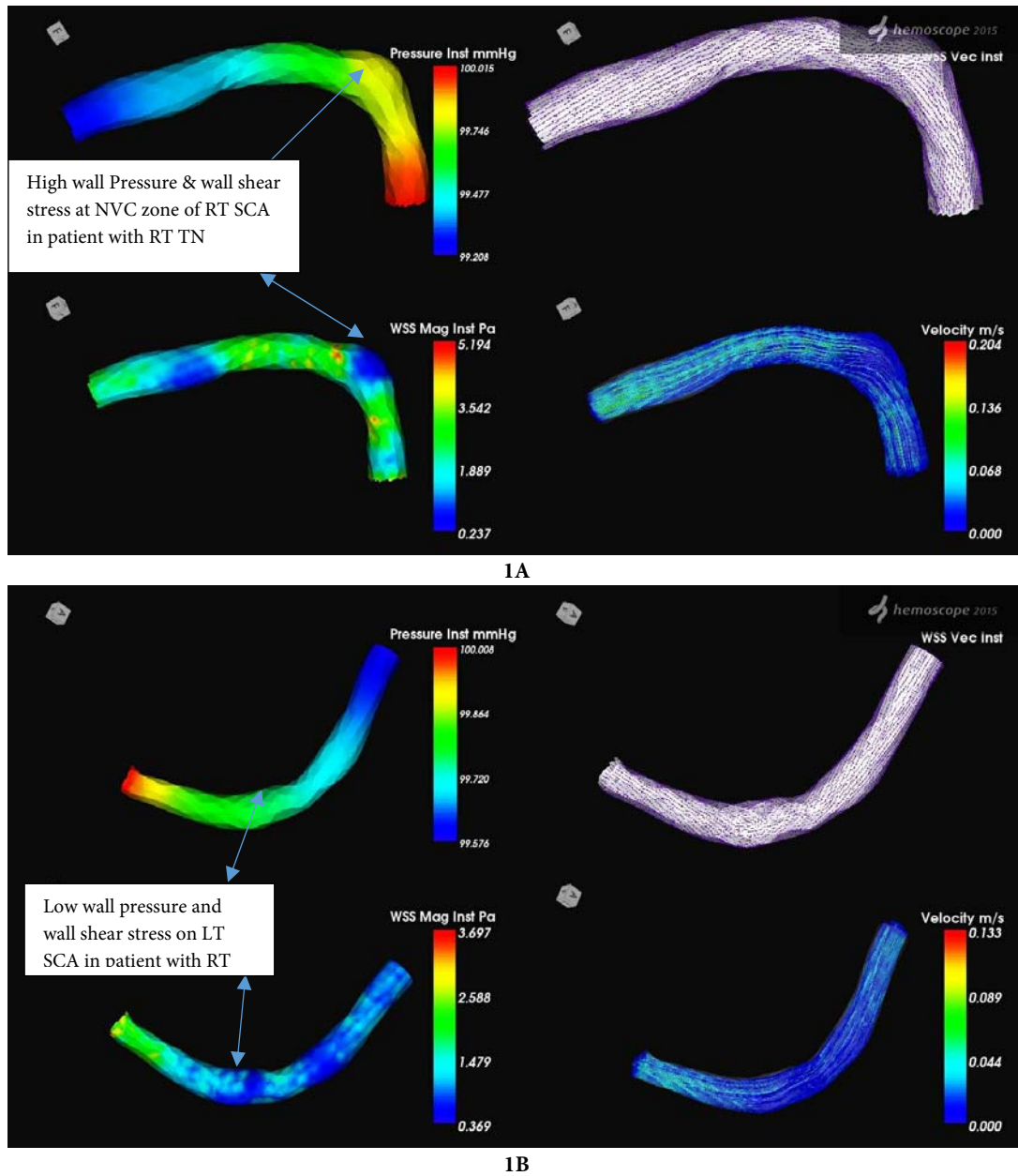
**TABLE 1**  
**Analysis of CFD in 13 patients operated for MVD in 2017**

Parameter	Test	Control
Wall pressure high	12/13 (92.3%)	6/13 (46.1%)
Wall pressure low	1/13 (7.7%)	7/13 (54.9%)
Wall shear stress high	10/13 (76.9%)	2/13 (15.4%)
Wall shear stress low	3/13 (23.1%)	11/13 (84.6%)

**TABLE 2:** Worksheet. WP: wall pressure, WSS: wall shear stress. IO NVC: Intraoperative neurovascular conflict. IP: Interposition TP: Transposition.

TN outcomes in BNI pain intensity score. In WP & WSS 1 is high, 0 is low. IO NVC 1 present, 0 absent

SL NO.	PATIENT ID	AGE	SEX	DIAGNOSIS	WP TEST	WSS TEST	WP CONTROL	WSS CONTROL	IO NVC	IP/TP	Surgery	offending vessel	IMMEDIATE OUTCOME	1 MONTH OUTCOME	3 MONTH OUTCOME
1	1427970	77	F	LT HFS	1	1	1	1	1	TP	28-Jun	AICA	NO HFS	NO HFS	NO HFS
2	1105948	74	M	LT HFS	1	1	0	0	1	TP	11-Jul	PICA	NO HFS	NO HFS	HFS
3	1889311	73	F	LT HFS	1	1	1	1	1	TP	06-Sep	PICA	NO HFS	NO HFS	NO HFS
4	2704242	66	F	LT HFS	1	1	0	0	1	TP	20-Sep	PICA	NO HFS	NO HFS	NO HFS
5	1167838	61	F	LT HFS	1	0	1	0	1	TP	11-Oct	VA PICA	NO HFS	NO HFS	NO HFS
6	2649675	74	F	RT TN	1	1	0	0	1	IP	16-Mar	AICA	I	I	I
7	2621818	55	F	RT TN	1	1	0	0	1	TP	21-Jun	SCA	I	I	IV
8	1132180	73	F	LT TN	1	0	1	0	1	TP	27-Jul	SCA	I	I	I
9	2605406	50	M	RT TN	1	0	0	0	1	TP	29-Aug	SCA	II	II	II
10	2708728	47	M	RT TN	1	1	1	0	1	TP	18-Oct	SCA	II	II	II
11	2710293	64	F	RT TN	1	1	0	0	1	TP	26-Oct	SCA	II	II	II
12	1180525	47	M	RT TN	0	1	1	0	0	NA	08-Nov	SCA / NO OV	II	II	II
13	2471086	68	M	LT TN	1	1	0	0	1	TP	13-Dec	SCA	II	II	II



**Figure 1** - Representative case depicting high wall pressure and high wall shear stress on affected side(A) whereas low wall pressure and wall shear stress on normal side (B)

## Discussion

In day to day practice, we as neurosurgeons face plenty of dilemmas when it comes to Nerve compression syndromes & MVD. Though most of the patients are treated conservatively at the onset. About 10-25% of the patients develop resistance to the medications. Some patients cannot tolerate the medications/ allergies.

There are multiple case scenarios wherein we as neurosurgeons are not able to help our patients with their misery. We would like to quote some of the scenarios which we believe all neurosurgeons who have an experience in treating TN & HFS will relate to.

**Case one:** Young patient with no comorbidities comes with history of classical trigeminal neuralgia. Not responding to medicines. MRI shows proximity of SCA to V nerve but no conflict. Patient in severe distress and wants to undergo microvascular decompression despite the fact that he still may not get relief. We operate find SCA loop around the REZ of V nerve. Achieve good MVD. Post operatively patient is pain free and has good quality of life without medicines.

**Case two:** Patient elderly, with underlying heart disease on antiplatelet therapy. Classical Trigeminal Neuralgia initially responding but now not responding to medications. MRI shows 'obvious' NVC. Patient consents for surgery. Antiplatelet drugs withheld for 5 days prior to surgery after cardiology consult. On table even with extensive arachnoid dissection we fail to identify any NVC at the REZ of V nerve. We handle the V nerve and come out. Postoperatively patient still has pain.

**Case three:** 47 year old with left hemifacial spasms. No comorbidities. MRI suggestive of

VA PICA NVC with VII nerve. Offered MVD & accepted. Intraoperatively large VA PICA compression of VII nerve was seen. MVD achieved. Patient was free of symptoms on first postoperative day but on second day post operatively symptoms recurred.

All these scenarios have one thing in common. We cannot incriminate the offending vessel as the cause for the patients' symptoms. Since blood flow and dynamics within the offending vessel plays an important basis of NCS, we have turned to CFD to predict offending vessel & incriminate it for the patients' symptoms.

Microvascular decompression is one of the first line of treatment in patients with failure with medications. MVD yields a good cure rates up to 90 % in cases when there is marked compression on preoperative MRI<sup>1</sup>. We have in our study tried to find ways in which we could predict the offending vessel accurately thereby improving patient selection in future resulting in only selection of cases where the offending vessel seen on imaging is the cause of patients' symptoms and offering them MVD as treatment of choice.

Limitations of our study include small sample size and short period of follow up. We recommend that in future a prospective study with more number of patients be done. We also recommend use of postoperative CFD to see for changes in the offending vessel after one year of complete remission of symptoms.

## Conclusion

From our results we can safely conclude that CFD can play an important role in predicting the offending vessel in patients with



TN & HFS. However greater sample size along with longer follow up period is required.

High wall pressure and wall shear stress at NVC zone are features that predict offending vessels in cases of TN & HFS.

High wall shear stress along with high wall pressure was more specific than high wall pressure alone in predicting the offending vessel in TN & HFS.

## References

- Marc Sindou, Neurosurgical management of trigeminal neuralgia; Essential Practice of Neurosurgery:2nd Edition; P 1365 – 66.
- Sekula RF, Jr, et al. Microvascular Decompression for elderly patients with trigeminal neuralgia: a prospective study & systematic review with meta-analysis. *J Neurosurg.* 2011; 114: 172 -179.
- Trucer B, et al. Microvascular Decompression for primary trigeminal neuralgia: short term follow up results and prognostic factors. *J Korean Neurosurg Soc.* 2012: 42-47.
- Oesman C, et al. Long term follow up of microvascular decompression for trigeminal neuralgia. *Skull Base.* 2011; 21: 313 – 322.
- Zhang H, et al. The long term predictors of pure microvascular decompression for primary trigeminal neuralgia. *World Neurosurg* 2013 May Jun; 79(5-6): 756 – 62.
- Chang Hyun Oh, et al. A case of hemifacial spasm caused by an artery passing through the facial nerve. *J Korean Neurosurg soc.* March; 57(3): 221 – 224.
- Marinos Kontzialis, et al. Imaging evaluation of trigeminal neuralgia. *J Istanbul Univ Fac Dent.* 2017; 51 (3 suppl 1): S62 - S68.
- <https://whatis.techtarget.com/definition/computational-fluid-dynamics-CFD>
- Suzuki T, et al. Determining the presence of thin walled regions at high pressure areas in unruptured cerebral aneurysms using computational fluid dynamics. *Neurosurgery.* 2016 Oct; 79(4): 589 -95.
- Skodvin TO, et al. Rupture prediction of intracranial aneurysm: a nationwide matched case-control study of hemodynamics at time of diagnosis. *J Neurosurg.* 2017 Nov 3: 1 – 7.
- Zhang Y, et al. Low wall shear stress is associated with the rupture of intracranial aneurysm with known rupture point: case report and literature review. *BMC Neurol.* 2016 Nov 18; 16(1): 231.
- H. Meng, et al. High WSS or low WSS? Complex interactions of hemodynamics with intracranial aneurysm initiation, growth, and rupture: toward a unifying hypothesis. *American Journal of Neuroradiology.* July 2014, 35(7) 1254 – 1262.
- Toru Satoh. Technical aspects of multi-fusion imaging:NVC of Trigeminal neuralgia and Hemifacial spasm. *J Neurosurgery* ahead of print.
- Zongshi Qin, et al. Comparative efficacy and acceptability of anticonvulsant drugs for classical trigeminal neuralgia: a Bayesian network meta-analysis protocol. *BMJ Open.* 2018;8(1): e017392.
- Court JE, et al. Treatment of tic douloureux with a new anticonvulsant ( clonazepam). *J Neurol Neurosurgery Psychiatry* 1976; 39:297 – 9.
- Yuan M, et al. Efficacy & safety of gabapentin vs carbamazepine in the treatment of of trigeminal neuralgia: a meta-analysis. *Pain Pract* 2016;16:1083–91.
- Obermann M, Yoon MS, Sensen K, et al. Efficacy of pregabalin in the treatment of trigeminal neuralgia. *Cephalalgia* 2008;28:174–81.
- Peiris JB, Perera GL, Devendra SV, et al. Sodium valproate in trigeminal neuralgia. *Med J Aust* 1980;2:278.
- Lu AY, et al. Hemifacial spasms and neurovascular compression. *ScientificWorldJournal.* 2014;2014:349319.
- L. E. Miller and V. M. Miller, “Safety and effectiveness of microvascular decompression for treatment of hemifacial spasm: a systematic review,” *British Journal of Neurosurgery*, vol. 26, no. 4, pp. 438–444, 2012.
- Ian Berger, et al. Microvascular Decompression Versus Stereotactic Radiosurgery for Trigeminal Neuralgia: A Decision Analysis. *Cureus.* 2017 Jan; 9(1): e1000.
- Riesenburger RI, Hwang SW, Schirmer CM, et al. Outcomes following single-treatment gamma knife surgery for trigeminal neuralgia with a minimum 3-year follow-up. *J Neurosurg.* 2009;112(4):766-771.