

ROMANIAN
NEUROSURGERY

Vol. XXXIV | No. 1 March 2020

A rare case of pituitary macroadenoma
with synchronous suprasellar
meningioma.
Case report, surgical strategy and review
of literature

Bogdan Ionut David,
Ligia Gabriela Tataranu,
Vasile Gheorghe Ciubotaru,
Aurelia Mihaela Sandu,
Radu Mircea Gorgan



A rare case of pituitary macroadenoma with synchronous suprasellar meningioma. Case report, surgical strategy and review of literature

Bogdan Ionut David^{1,3}, Ligia Gabriela Tataranu^{2,3}, Vasile Gheorghe Ciubotaru³, Aurelia Mihaela Sandu³, Radu Mircea Gorgan^{2,3}

¹ PhD Student, University of Medicine and Pharmacy "Carol Davila", Bucharest, ROMANIA

² University of Medicine and Pharmacy "Carol Davila", Bucharest, ROMANIA

³ Department of Neurosurgery, Emergency Clinical Hospital Bagdasar-Arseni, Bucharest, ROMANIA

ABSTRACT

Synchronous tumours can be found all along the entire neuraxis, however, some lesions are far less likely to coexist. One of these extremely rare associations is between GH-pituitary adenomas and suprasellar meningiomas. A wide spectrum of transcranial and transsphenoidal approaches were described in the literature for either sellar, suprasellar and parasellar lesions, but no agreement has been reached for the cases of simultaneous occurring lesions.

We present a rare case of a woman with GH-secreting pituitary adenoma and concomitant suprasellar meningioma. The strategy chosen was sequential transsphenoidal surgeries. However, after the first surgery, the remaining tumour mass did not mobilize as expected due to gravity, hence we decided to perform a transcranial subfrontal unilateral approach. Surprisingly, the second surgery revealed a different histopathological result.

Association of a GH-pituitary adenoma and suprasellar meningioma is very rare, only 17 cases being reported in the relevant literature so far. Different authors prefer different strategies, ranging from only transsphenoidal to simultaneous transsphenoidal and transcranial approaches, but no general consensus was established.

In conclusion, the existence of synchronous tumours of the sellar region should be taken into account when imaging studies reveal an intracranial mass developing both sellar and suprasellar. The surgical strategy should be tailored to every specific patient and experience of the neurosurgeon.

INTRODUCTION

Synchronous tumors are found along the entire neuraxis, however some lesions are far less likely to coexist (1). One of these unlikely associations is between pituitary adenomas and suprasellar menin-

Keywords
pituitary macroadenoma,
synchronous,
staged surgery,
suprasellar meningioma



Corresponding author:
Bogdan Ionut David

University of Medicine and
Pharmacy "Carol Davila",
Bucharest, Romania

david.bogdan.med@gmail.com

Copyright and usage. This is an Open Access article, distributed under the terms of the Creative Commons Attribution Non-Commercial No Derivatives License (<https://creativecommons.org/licenses/by-nc-nd/4.0/>) which permits non-commercial re-use, distribution, and reproduction in any medium, provided the original work is unaltered and is properly cited.

The written permission of the Romanian Society of Neurosurgery must be obtained for commercial re-use or in order to create a derivative work.

ISSN online 2344-4959
© Romanian Society of
Neurosurgery



First published
March 2020 by
London Academic Publishing
www.lapub.co.uk

giomas. Few cases have been reported in literature, most of the pituitary tumors being GH secreting adenomas. (1) However, a syndrome has yet to be defined consisting of this association, and, with the exception of the previously radio-treated pituitary adenomas that develop subsequent meningiomas, no pathophysiological connection exists.

Even though each type of tumor has distinct radiological findings, there are cases in which they can easily be misdiagnosed or even confused for one single lesion. This rare occurrence must be taken into account by neurosurgeons planning tumor resection in such cases. A wide spectrum of transcranial and transsphenoidal approaches have been described in literature for either sellar, suprasellar and parasellar lesions, but no agreement has been reached for the cases of simultaneous occurring lesions. (2)

The purpose of this article is to present a rare case of a simultaneous GH secreting pituitary adenoma and a supradiafragmatic meningioma, the strategy behind the surgical approach and review of literature.

CASE PRESENTATION

A 57 years old woman, with history of stage II hypertension, type II diabetes mellitus, NYHA II heart failure was admitted with intense headache, visual field disturbances and hormonal disturbances (elevated GH levels: IGF-1 = 98 ng/ml, $N = 10$ ng/ml). The cerebral CT scan showed a contrast enhancing sellar mass which extended suprasellar, slightly eccentric to the left. (Figure 1)

The presumed diagnosis was GH-secreting pituitary macroadenoma with suprasellar extension. We decided to perform surgery via transsphenoidal approach. Due to large size of the tumor and high risk of rupturing the sellar diaphragm, only partial resection was performed and a second transsphenoidal surgery was scheduled for the upcoming three months. The rationale was that the suprasellar part of a tumor originating in the sellar region will gravitationally fall in the sella over the next three months, thus enabling a second minimally invasive surgery.

The first histopathological exam was acidophilic pituitary adenoma with capsular invasion. (Figure 2) Initial postoperative outcome was uneventful, without any additional neurological deficits.

After three months, the cerebral CT scan showed a surprising stationary suprasellar tumor. (Figure 3)

We changed our initial strategy, and we decided to operate the tumor via the subfrontal approach on the nondominant side (right). Intraoperative we found a suprasellar meningioma. We achieved tumor complete resection, with no intraoperative incidents.

The second histopathological exam revealed meningotheial meningioma with transitional components. (Figure 4) After removal of the suprasellar tumor, visual field impairment improved. The patient required substitute hormonal therapy for transient diabetes insipidus for the first three months, which was gradually lowered in dosage. At three months postop, CT showed complete tumor removal and the patient was hormonally stable. Even if standard post-surgical strategy is to administer oral corticoids, these were interrupted after only one month, and no further hormonal therapy was required.

The particularity of the case was simultaneous development of a GH-secreting pituitary macroadenoma and suprasellar meningioma, a rare association of two types of histological tumors, with no apparent link between them.

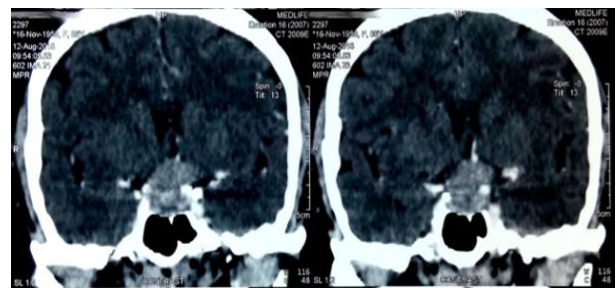
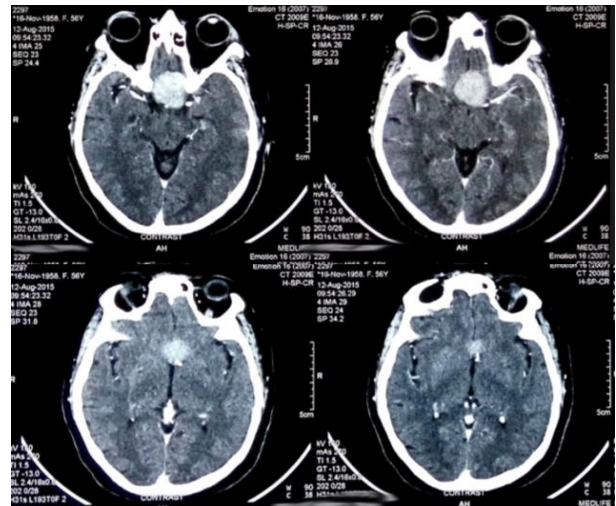


Figure 1. Cerebral CT scan showing a sellar and suprasellar contrast enhanced tumor.

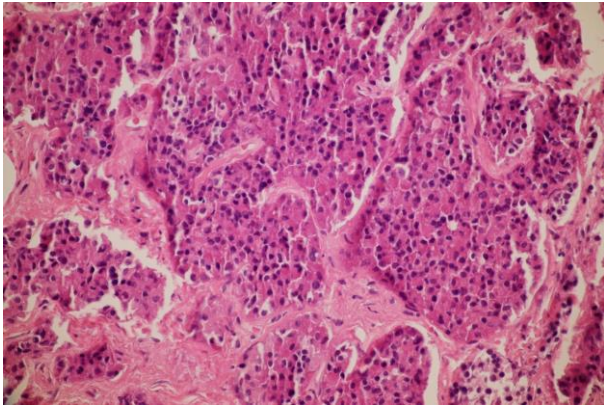


Figure 2. Acidophilic pituitary adenoma; HE; 40x.

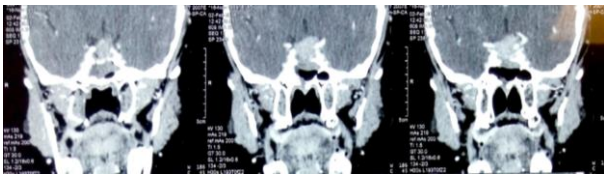


Figure 3. Cerebral CT scan, performed 3 months after the first surgery, showing suprasellar contrast enhanced tumor with no sellar tumor.

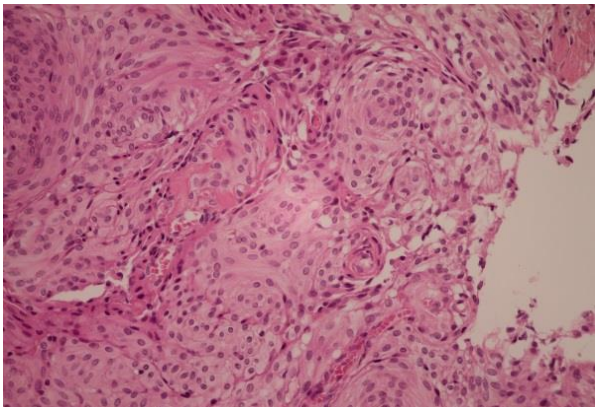
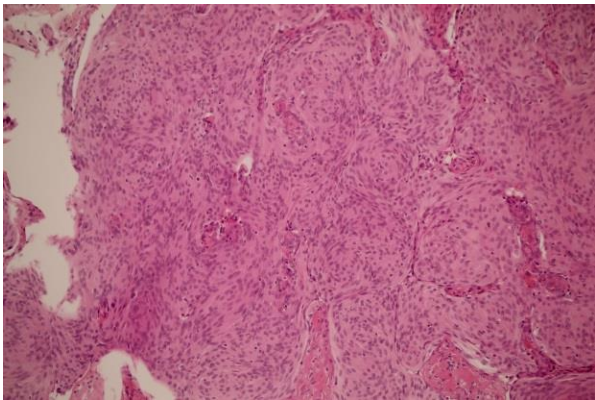


Figure 4. Meningothelial meningioma with transitional components; HE; a. 20x; b. 40x.

REVIEW OF LITERATURE

MESH terminology consists of two different situations which describe simultaneous development of brain tumors. Thus, one can encounter either collision tumors, in which case one tumor infiltrates the other one, or coincidental tumors, tumors being synchronous, but with different histogenesis, being situated one next to the other or at a distance. (3)

We performed a search in PubMed and Google Scholar for simultaneous occurring brain tumors out of which one would be a pituitary adenoma and we found 43 publications and a total of 63 patients. (1) Furthermore, a search of similar cases to ours found that the rare situation of simultaneous development of a pituitary adenoma and suprasellar or sphenoid wing meningioma has been reported in 32 cases. (4) Moreover, only 17 cases of strictly suprasellar meningiomas were described in the literature, our case being the 18th. (1)

DISCUSSIONS

Tumors of the sellar region have mesenchymal, neural or epithelial origin, along with cystic and inflammatory processes. Out of all these tumors, pituitary adenomas are the most common, accounting for about 10-15% of all intracranial tumors. (5) Most of the patients treated in our clinic present with both endocrine symptoms, but also intracranial hypertension and optic chiasm symptoms due to large size of the tumor. Thus, most of the patients suffer from macroadenomas (> 10 mm) at the time of diagnosis, and most of the tumors extending beyond the sella turcica, either parasellar or suprasellar.

The existence of simultaneous pituitary adenoma and supradiafragmatic meningioma is a very rare situation. Search of relevant literature performed in PubMed and Google Scholar revealed only 17 other cases, ours being the 18th. (1)

Even though a plethora of possible mechanisms have been forwarded in relation to multiple brain tumors occurring simultaneously and having different histology origins, none have been widely recognized by the neurosurgery community.

While some authors suggest a common receptor activator that triggers both lesions, others believe that one of the tumors might secrete a growth factor responsible for the initiation of aberrant cell growth in the second tumor. Although growth hormone

secreting adenomas have been suggested to induce arachnoid cell transformation, this hypothesis has yet to be confirmed. (6)

Other authors consider favorable factors for synchronously developing adenoma and meningioma variables such as genetic factors, prior trauma or surgery and even exposure to offending biochemical substances. (7)

It is essential to distinguish between cases of pituitary adenoma with a suprasellar component, and cases of a co-existing sellar adenoma and suprasellar meningioma, because different surgical strategies might be adequate for these two different situations. (2) This is particularly difficult, because in most of the times the two lesions are indistinguishable from a radio-imaging point of view, our case did not show any pathognomonic imaging characteristic.

Most authors prefer to perform both tumor resections in either one surgical procedure, or combined transsphenoidal and transcranial approach under the same single general anesthesia. However, sometimes this might not be possible, and a decision must be made on which lesion to perform resection on first. Surgical strategy is tailored according to the symptomatic lesion. So, in such cases it must be seen to whom the symptoms are due. Both tumors were located in the same area, sellar and suprasellar region and both can cause slightly similar neurological complaints. Headache is a nonspecific symptom, visual fields deficits are common findings in both pituitary macroadenomas and suprasellar meningiomas, but hormonal imbalances are specific for a pituitary adenoma. So, in cases when lesions cannot be resected using the same approach, the surgeon must first operate the symptomatic tumor.

Regarding the existence of an agreement as to the best surgical approach to be used, we could only find one: use the best approach tailored to the specific case of the patient. Therefore, some authors prefer to perform a transsphenoidal approach for both the lesions (3), others use a combined approach under the same anesthesia, others prefer a two timed transsphenoidal (4), transcranial, and so on.

Two-stage surgery is not an uncommon practice for large pituitary adenomas. In our case, both sellar and suprasellar components were considered to be part of the same pituitary macroadenoma. The treatment of choice for pituitary adenomas is tumor

resection via transphenoidal route. During transsphenoidal surgery the sellar part of the tumor is resected, and the soft suprasellar component descends, with the aid of gravity and CSF pulsation and develop itself to the surgeon. When the tumor is more firm this cannot happen during surgery. Vigorous attempts to pull the suprasellar tumor into the sella can be dangerous, due to possibility of adherence to neurovascular structures. More sellar diaphragm can be teared, leading to postoperative CSF fistula. In such cases a two-stage transsphenoidal surgery can be performed, because after a period of time of a few months the suprasellar will descend and through planned elective surgery the tumor can be completely resected via same surgical approach with minimal risks. Even more, first histopathological examination confirmed the nature of the tumor as being GH-secreting pituitary adenoma. That was the rationale for our decision not to extend the resection to the suprasellar component, but rather consider a second transsphenoidal approach 3 months later, in order to allow the rest of the tumor to gravitationally descend in the sella. However, the CT scan at 3 months showed a stationary suprasellar component. The decision was made to perform subfrontal approach in order remove this component. This second lesion turned out to be a meningioma.

This case perfectly illustrates the need for approaching every sellar tumor through the path that offers the most advantages. Thus, a transsphenoidal approach would not have allowed the surgeon to resect the suprasellar component without major risks, whilst a subfrontal approach would not have been possible to resect the entire sellar component.

Overall, the patient had favorable outcome, because he harbored two benign, slow-growing tumors.

CONCLUSIONS

Synchronous GH-secreting macroadenoma and suprasellar meningioma developing simultaneously in the sellar and suprasellar region are very rare findings. In selected cases, both minimally invasive transsphenoidal approach and transcranial microsurgical approach must be considered simultaneously in order to achieve complete resection. Moreover, the existence of two different lesions developing in the same region should be

considered in all the cases of pituitary adenomas with a suprasellar component. Further research is needed with genetic profile of patients with synchronous tumors.

CONFLICTS OF INTEREST

The authors declare no conflict of interests.

FOUNDING

None

REFERENCES

1. Amirjamshidi A, Mortazavi SA, Shirani M, Saeedinia S, HANif H. Coexisting pituitary adenoma and suprasellar meningioma - a coincidence or causation effect report of two cases and review of the literature. *J Surg Case Rep*, 2017 (5):rjx039. doi: 10.1093/jscr/rjx039.
2. Lim KZ, Goldschlager T, Chandra RV, Hall J, Uren B, Pullar M. Co-occurrence of pituitary adenoma with suprasellar and olfactory groove meningiomas. *Basic Clin Neurosci*, 2016. 7:361-365.
3. Prevedello DM, Thomas A, Gardner P, Snyderman CH, Carrau RL, Kassam AB. Endoscopic endonasal resection of a synchronous pituitary adenoma and a tuberculum sellae meningioma: technical case report. *Neurosurgery*, 2007. 60(4 Suppl 2):E401.
4. Guaraldi F, Prencipe N, di Giacomo V, Scanarini M, Gasco V. Association of craniopharyngioma and pituitary adenoma. *Endocrine*, 2013. 44:59-65.
5. Cannav S, Curt L, Fazio R, Paterniti S, Blandino A, Marafioti T, Trimarchi F. Coexistence of growth hormone-secreting pituitary adenoma and intracranial meningioma: A case report and review of the literature. *J Endocrinol*, 1993. 16:703-8.
6. Mathuriya SN, Vasishta RK, Dash RJ, Kak VK. Pituitary adenoma and parasagittal meningioma: an unusual association. *Neurol India*, 2000. 48:72-4.
7. Goldberg MB, Sheline GE, Malamud N. Malignant intracranial neoplasms, following radiation therapy for acromegaly. *Radiology*, 1963. 80:465-470.