

ROMANIAN
NEUROSURGERY

Vol. XXXIV | No. 2 June 2020

Cranium metastasis of HPV positive
oropharyngeal squamous cell carcinoma

Gokhan Canaz,
Huseyin Canaz,
Sabri Aydin



Cranium metastasis of HPV positive oropharyngeal squamous cell carcinoma

Gokhan Canaz¹, Huseyin Canaz², Sabri Aydin²

¹ Arnavutkoy State Hospital, Department of Neurosurgery, Istanbul, TURKEY

² Florence Nightingale Hospital, Istanbul Bilim University, Department of Neurosurgery, Istanbul, TURKEY

ABSTRACT

Head and neck squamous cell carcinomas rarely cause cranial metastases, but HPV related subgroup is known for unusual metastasis sites on the body. Despite the good overall treatment responses in this group, intracranial metastases are always accepted as a sign of rapid deterioration. We present a case of cranium metastasis of HPV related oropharyngeal squamous cell carcinoma, which had been very well responded to the treatment for years but deteriorates in a short period after the cranium metastasis.

INTRODUCTION

Head and neck squamous cell carcinomas (HNSCC) are known as rarely causing intracranial metastases. In the last years, HPV related subgroup of HNSCC has become a distinct subject of studies. They mostly occur at oropharynx. The incidence of HPV-positive HNSCC is increasing. Unlike the HPV-negative one, this subgroup does not show a relationship with tobacco and alcohol, which are prominent risk factors of HNSCC. More favourable results of chemotherapy and radiotherapy have been reported in comparison to the HPV-negative variant. The more successive local control means better morbidity and survival rates. On HPV-positive cases, a better prognosis was reported even on lung metastasis, which is the most frequent site of distant recurrence. Also, a different pattern of metastasis has been mentioned in recent studies (3). On the other hand, the presence of brain metastasis has always been accepted as a bad sign regardless of HPV status.

We present a case of a patient who has one of the most extended survival lengths reported in the literature despite unusual multisite metastases but deteriorated rapidly due to very aggressive cranium metastasis.

CASE REPORT

Sixty-four years old female patient had submitted to hospital with pain on the chest and back in 2013. Examinations revealed metastatic

Keywords
metastasis,
human papilloma virus,
HPV,
cranium,
squamous cell



Corresponding author:
Gokhan Canaz

Arnavutkoy State Hospital,
Department of Neurosurgery,
Istanbul, Turkey

gokhancanaz@gmail.com

Copyright and usage. This is an Open Access article, distributed under the terms of the Creative Commons Attribution Non-Commercial No Derivatives License (<https://creativecommons.org/licenses/by-nc-nd/4.0/>) which permits non-commercial re-use, distribution, and reproduction in any medium, provided the original work is unaltered and is properly cited.

The written permission of the Romanian Society of Neurosurgery must be obtained for commercial re-use or in order to create a derivative work.

ISSN online 2344-4959
© Romanian Society of
Neurosurgery



First published
June 2020 by
London Academic Publishing
www.lapub.co.uk

lymphadenopathies on mediastinum and metastases on the lung, liver, and vertebra corpus, but the primary tumour had not been found. With consecutive periods of chemotherapy (including carboplatin, capecitabine, and cisplatin-etoposide) and radiotherapy, local control was achieved, and the patient has succeeded five years of survival. In 2018, the patient had multiple enlarged lymph nodes in the cervical area. Following the tru-cut biopsy results, the pathology report pointed out CD117 positivity and low metabolic activity despite the clinical features. As a result, pathological examinations could not suggest a diagnosis. The new PET scan revealed multiple mediastinal and intraabdominal lymphadenopathies and improved uptake in various areas in the gastrointestinal system. With chemotherapy and radiotherapy, the local cure was succeeded. Other sites also responded to the treatment. In November 2018, in an examination for head-ache, extensive cranium metastasis was spotted. The patient was consulted to neurosurgery, and surgery was offered (Fig. 1). During the decision period of patient, right hemiparesis and headache complaints were developed. In concomitant MRIs within three months period, significant enlargement was discovered, and operation was performed (Fig. 2,3).

First, question mark skin incision was performed, and the tumour was revealed, extruding from the calvarium. A large frontoparietal craniotomy flap, which was covering the whole tumour and adherent dura, was elevated. Because of the cohesiveness, the dura was incised and elevated with the tumour. No invasion to parenchyma was observed but cerebrum was edematous. Because of that after bone-tumour-dura complex resection, cranioplasty was planned for a further time.

Pathologic examination revealed that the tumour was HPV positive oropharyngeal squamous cell carcinoma metastasis with strong p16 and neuroendocrine marker positivity. Different from the previously pathological examination, ki-67 index was found to be very high (about %80). Post-op PET scan also revealed an oropharyngeal mass with improved up-take near the base of the tongue.

DISCUSSION

HPV positive HNSCC are characterized by a better therapeutic response and lower recurrence in comparison to HPV negative variant, which means

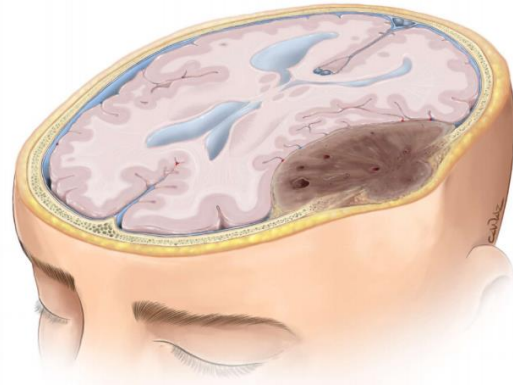


Figure 1.

overall better clinical outcome in terms of survival and morbidity (2). Because of this nature of HPV positive HNSCC, even in the presence of metastases, more direct and curative approaches are preferred instead of palliative treatment options.

Besides the better outcomes, the distant metastasis pattern of HPV positive SCC also differs. The longer survival lengths, thank to better therapeutic results, may contribute to increased numbers of distant metastases on HPV positive SCC. The most frequent metastasis sites for HNSCC are known as lung, liver, and bone (5). In this order, liver and bone metastases were reported as much rarer than the lung. An increased incidence in bone metastases, especially in vertebrae, were reported in patients with p16 positive tumours lately. The recent articles are reporting HPV positive SCC cases with multisite metastasis, including unusual sites such as long bones, brain, dura, pancreas, and skin (3,4). Among the metastasis sites, the brain was accepted to have the worst prognosis and defined as “non-curable”. Brain metastasis frequency on HNSCC was mentioned in a few articles as 0.43 – 5.7%.

The tumour-free episodes in HPV positive SCC are reported to be longer than non-HPV variants in several studies (2). When the recurrence or first metastasis was spotted during follow-ups, patients usually have metastasis on more than one site. In both HPV + and – tumours, metastases have much more aggressive behaviors than their primary tumours. Independent from the response of these metastases to the treatment, different, unexpected new metastases may occur, and the death of patients is usually caused by these aggressive new tumours. The development time of metastases is

approximately two years following the primary tumour treatment (4, 5). In a recent study about brain metastases of HNSCC, mean time of interval between diagnosis of primary and brain metastasis was reported as 26 months. Among the eleven patients, two longest intervals were 137 and 66 months, and the latter patient had 65.7 months of disease-free time, meaning prognosis of the brain metastasis was the decisive factor in patients' life (1).

Besides clinical features, HPV positive SCC's are known to be hard to detect on PET and MRI scans. As in our case, this mass had not been detected previous PET and MRI scans.

CONCLUSION

Extended patient follow-up times are suggested for HPV positive tumours in many papers as a conclusion (2, 4). Under these circumstances, we think that it would not be wrong to define the length of follow-up as "lifelong". Considering positive features of HPV-positivity, with further analysis of metastasis pattern of HPV positive HNSCC and with the developments of neurosurgical oncology, much longer survivability can be achieved in this patient group.

PATIENT CONSENT

The patient has consented to the submission of the case report for submission to the journal.

DECLARATION OF CONFLICT OF INTEREST: None

ACKNOWLEDGEMENTS

We would like to thank "Cura Canaz Medical Arts (www.ccmedicalarts.com)" for the illustrations.

REFERENCES

- Ahmed A, Sandlas G, Kothari P, Sarda D, Gupta A, Karkera P, Joshi P. Outcome analysis of shunt surgery in hydrocephalus. *J. Indian. Assoc. Pediatr. Surg.* 2009, 14 (3): 98-101.
- Bradley NK, Liakos AM, Mcallister JP, Magram G, Kinsman S, Bradley MK. Maternal shunt dependency: implications for obstetric care, neurosurgical management, and pregnancy outcomes and a review of selected Literature. *Neurosurgery.*1998, 43 (3): 448-60.
- Browd SR, Ragel BT, Gottfried ON, Kestle JR. Failure of cerebrospinal fluid shunts: part I : Obstruction and mechanical failure. *Pediatr. Neurol.* 2006, 34 (2),83-92.
- Browd SR, Ragel BT, Gottfried ON, Kestle JR. Failure of cérebrospinal fluid shunts: part II: over drainage, loculation, and abdominal complications. *Pediatr. Neurol.* 2006,34 (3):171-6.
- Cusimano MD, Meffe FM, Gentili F, Sermer M. Ventriculoperitoneal shunt malfunction during pregnancy. *Neurosurgery.* 1990,27(6):969-71.
- Cusimano MD, Meffe FM, Gentili F, Sermer M. 1991.Management of pregnant woman with cerebrospinal fluid shunt. *Pediatr. Neurosurg.*1991,92 (17):10-3.
- Drake JM, Kestle JR, Milner R, Cinalli G, Boop F, Piatt JJR, Haines S, Schiff SJ, Cochrane DD, Steinbok P, Macneil N.1998 Randomized trial of cerebrospinal fluid shunt valve design in pediatric hydrocephalus. *Neurosurgery.* 1998,43:294-303.
- Eholier Sp, Boni B, Aoussi E, Konan A, Orega M, Koffi A L, Ba Zézé V, Bissagnene E, Kadio A. Complications neurochirurgicales des méningites Purulentes en zone tropicale. *Neurochirurgie.* 1999,45(3):219-24.
- Fletcher H, Crandon lw, Webster D. Maternal Hydrocephalus in Pregnancy and Delivery: A Report of Two Cases. *West. Indian. med. J.*2007,56(6):558-9.
- Freo U, Pitton M, Carron M, Ori C. 2009.Anesthesia for urgent sequential ventriculoperitoneal shunt revision and cesarean delivery. *Int. j. obstet. Anesth.* 2009,18(3): 284-7.
- Hanakita J, Suzuki T, Yamamoto Y, Kinuta Y, Nishihara KJ. Ventriculoperitoneal shunt malfunction during pregnancy. *J Neurosurg.*1985, 63(3):459-60.
- Houston CS, Clein LJ. Ventriculoperitoneal shunt malfunction in a pregnant patient with meningomyelocele. *CMAJ.*1989,141(1):701-2.
- Hwang S.C, Tae-Hee K, Bum-Tae K, Soo-Bin I, Won-Han S. Acute Shunt Malfunction after Cesarean Section Delivery. *J. Korean. Med. Sci.*2010,25(4):647-50.
- Kleinman G, Sutherling W, Martinez M, Tabsh K. Malfunction of ventriculoperitoneal shunts during pregnancy. *Obstet Gynecol.* 1983,61(6):753-4.
- Kurtsoy A, Selçuklu A, Kemal Kr, Pasaoglu A, Kavuncu Al. Management of Maternal Hydrocephalus. *Turkish Neurosurgery.*1994,4:174-5.
- Landwehr JB, JR, Isada NB, Pryde PG, Johnson MP, Evans MI, Canady Al. Maternal neurosurgical shunts and pregnancy outcome. *Obstet Gynecol.* 83(1):134-7.
- Liakos AM, Bradley NK, Magram G, Muszynski C. Hydrocephalus and the reproductive health of women: the medical implications of maternal shunt dependency in 70 women and 138 pregnancies. *Neurol Res* .2000,22(1):69-88.
- Maheut-Lourmière J, Chu Tan S. Hydrocephalus during pregnancy with or without neurosurgical history in childhood. *Practical advice for management Neurochirurgie.*2000,46 (2):117-21.
- Monafared AH, Kee SK, Apuzzo MLJ, Collea JV. Obstetric management of pregnant woman with extracranial shunts. *Can. Med. Assoc. J.* 1979,120(5):562-3.

20. Mouelhi C, Srasra M, Zhioua F, Ferchiou M, Zine S, Meriah S. Maternal hydrocephaly and pregnancy. *Rev. Fr. Gynecol. Obstet.* 89(2):88-90.
21. Murakami M, Morine M, Iwasa T, Takahashi Y, Miyamoto T, Hon PK, Nakagawa Y. Management of maternal hydrocephalus requires replacement of ventriculoperitoneal shunt with ventriculoatrial shunt: a case report. *Arch. Gynecol.Obstet.* 2010,282 (3):339-42.
22. Okagaki A, Hanzaki H, Moritake K, Mori T.1990. Case report: pregnant woman with a ventriculoperitoneal shunt to treat hydrocephalus. *Asia. Oceania. J.Obstet. Gynaecol.* 1990,16: 111-3.
23. Orega M, Eholier S P, Boni N, Konan A, Koffi A L. Méningites purulentes et complications neuro-chirurgicales chez l'enfant à Abidjan. *Médecine d'Afrique Noire.* 2005,52(4):251-2.
24. Rees GJ, Francis C, Sizer A R. Convulsions in an undiagnosed pregnancy due to blocked ventriculoperitoneal shunt.*J. Obstet. Gynaecol.* 2008,26(5), 533-4.
25. Riffaud L, Ferre, JC, Carsin-Nicol B, Morandi X. Endoscopic third ventriculostomy for the treatment of obstructive hydrocephalus during pregnancy.*Obstet. Gynecol.* 2006,108:801-4.
26. Sova M, Smrcka, M, Baudysova O, Gogela J Management of a shunt malfunction during pregnancy. *Bratisl Lek Listy.* 2001,102(12):562-3.
27. Wishoff JH, Kratzert KJ, Handwerker SM, Young BK, Epstein F. Pregnancy in patients with cerebrospinal fluid shunts: report of a series and review of the literature. *Neurosurgery.* 1991,29(6):827-31.